

Histopathological and enzymatic study on the effect of *Aspergillus fumigatus* in mice

Shatha A Shafiq* BSc
Akbal K. Al- Joofy* BSc, PhD

Summary:-

Background: - *Aspergillus fumigatus* is a ubiquitous and opportunistic fungal pathogen causing severe invasive aspergillosis, an important source of morbidity and mortality in immunocompromised hosts (human and animals). The present study was conducted to obtain more clarification about the toxicity and histopathological effects of this pathogen in albino mice.

Material and Methods :- fourteen male mice (6-10) weeks old, (20 – 28) gm weight, divided into two groups, test group (n= 8), intranasally infected with 25 μ l (10^7 conidia / ml normal saline) of *A. fumigatus* for 7 successive days, compared with uninfected group (n=6). The weight of all animals was measured at the beginning and at the end of the experiment, in addition to histological study for lung, liver and kidney were performed, with estimation of enzyme activity of GOT (Glutamic Oxaloacetic Transaminase), GPT (Glutamic Pyruvic Transaminase), ALP (Alkaline Phosphatase) and Creatinine Kinase in homogenized liver and kidney tissues were studied by colorimetric method.

Results :- increased ($p < 0.05$) in body weight, and organs weight (lung, liver, kidney) in infected mice with different histological changes were found in organs tissues of infected mice especially in lung and liver, these changes were supported by variation in enzyme activities of GOT, GPT, ALP and Creatinine kinase in homogenized organs tissues.

Conclusion: - normal host can suffer from systematic diseases after inhalation of infective forms of *A. Fumigatus* (conidia), and further work is needed to study the active components, which are responsible for pathogenesis of this opportunistic fungi.

Keywords: - Aspergillosis, Histopathology, GOT, GPT, ALP, Creatinine kinase.

Fac Med Baghdad
2010; Vol. 52, No. 4
Received Dec., 2009
Accepted Feb., 2010

Introduction:-

Aspergillus fumigatus is the dominating species causing fungal lung diseases in human and animal, usually acquired through the inhalation of small enough conidia reaching the small airways and alveolar spaces (1). Air, water, soil, plant debris, manure, animal feed are the natural ecological rich of *A. fumigatus* from which aerosols of conidia are released. Thus, the pathogenesis of invasive aspergillosis (IA) starts with the inhalation of the conidia by the patients, any increase in the concentration of airborne conidia increase the risk of contracting aspergillosis in susceptible individuals with no host specific strains were observed (2). Mice, especially outbred Swiss mice, have been the most common animals used. Most mouse strains, regardless of genetic background are equally susceptible to *A.fumigatus*, particular difference in host sensitivity may be used in the study of fungal pathogenesis (3). Several studies have been accepted histopathological changes in host with Aspergillosis (4, 5, 6, 7). Moreover, the role of enzymes is well during various

diseases among which are liver, kidney and bone diseases, among, the isoenzyme of clinical importance are GOT, GPT, ALP (liver function) and Creatinine kinase as kidney function enzyme (8). This study was designed to obtain more clarification about the toxicity and histopathological effects of *A.fumigatus* in animal model.

Material and Methods:-

A.fumigatus clinical isolate from external ear of patients attending Central Health Laboratories – Baghdad. Conidia suspension was prepared according to the method reported by Faraj, 1990(9), then the number of conidia was calculated under high dry power 40X of compound light microscope, using the following equation.

Concentration of conidia = $Z \times 4 \times 10^6 / n$.

Where Z= total number of conidia, n= total number of small squares.

Animals: fourteen male white swiss mice (*Mus musculus*) age ranged from (6-10) weeks, (20-28) gm weight, divided into two groups, test group (n=8) and control group (n=6), The animals were fed with suitable quantity of water and complete diet. The

*Dept. of biology, college of Science, Al- Mustansiria university.

mouse model of acute aspergillosis was established by intranasal administration of *A. fumigatus* conidia (25 µl (10⁷conidia/ml normal saline.) by using micropipette for 7 successive days (3), which represent the test group , while control group was administrated normal saline only . Then all animals were killed by spinal dislocation, lung, liver and kidney were removed for both histological and enzymes activity studies.

Tissues were fixed in 4% neutral buffered formalin, embedded in paraffin and cut into sections which stained with hematoxylin and eosin (H & E) and examined microscopically 40 x (10).

On the other hand , homogenized organs tissues (liver and kidney) were used to estimate the specific activity of liver enymes (glutomic oxaloacetic transaminase (GOT) , Glutamic pyruvic transaminase (GPT) , Alkaline phosphatase (ALP) and kidney enzyme (Creatinine kinase) by using colorimetric method (11, 12) .

Statistical Analysis

Statistical significant was assessed by using least significant differences – LSD (T- test) P- value <0.05 was considered significant. Results were expressed as mean ± S.D. all the statistical analysis were done by using Pentium – 4 computer through the (SPSS) program (version – 10) and excel application (13) .

Results:-

Results showed significant increased (P > 0.05), in the mean of body weight of test group before / and after infection with *A. Fumigatus* (22.41 / 23.07 gm) as compared with control group (20.86 / 22.43). Moreover, significant elevation (P <0.05) in organs weight (mg) in test group in comparsion to control group as clearly shown in table (1).

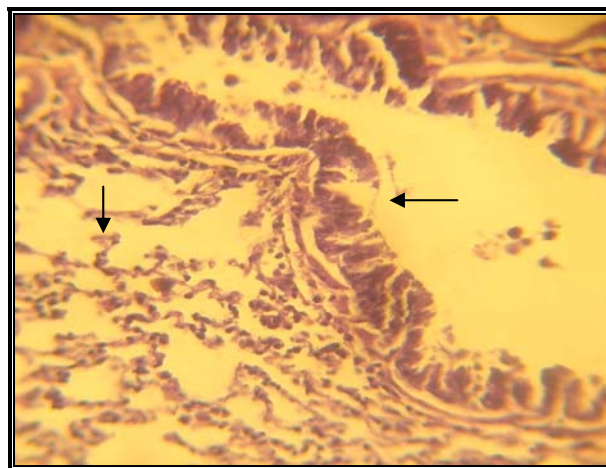
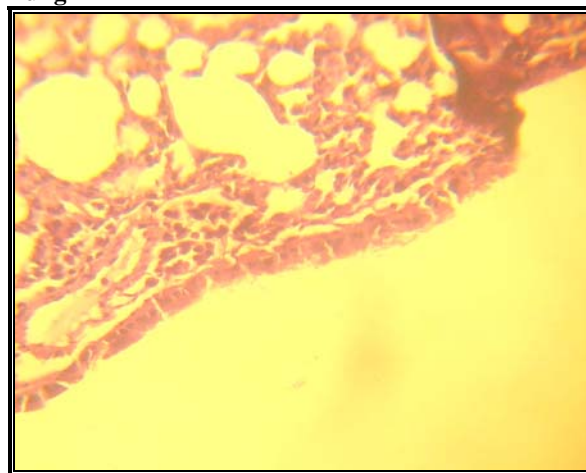
Table(1). Influence of intranasally infected mice with *A. fumigatus* conidia on organs weight (liver , lung , kidney) in the study groups .

Study groups	Organs weight (mg) Mean ± S.D.		
	Lung	liver	kidney
Control group (n=6)	8.90 ± 0.66	70.63 ± 1.54	16.85 ± 1.10
Test group (n= 8)	11.64 ± 1.63*	75.75 ± 1.52 *	15.92 ± 2.23 *

* Significant (P < 0.05)

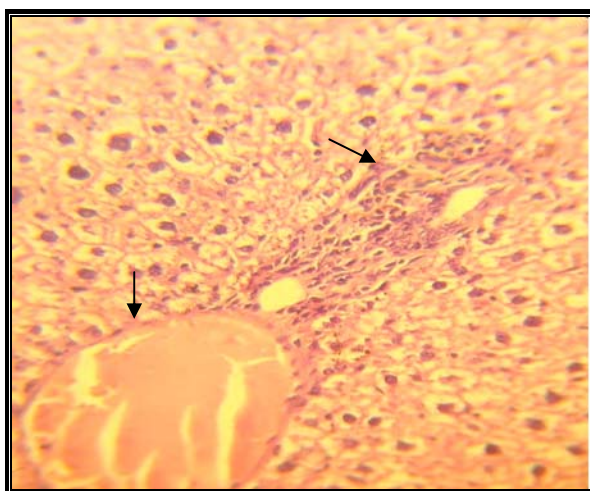
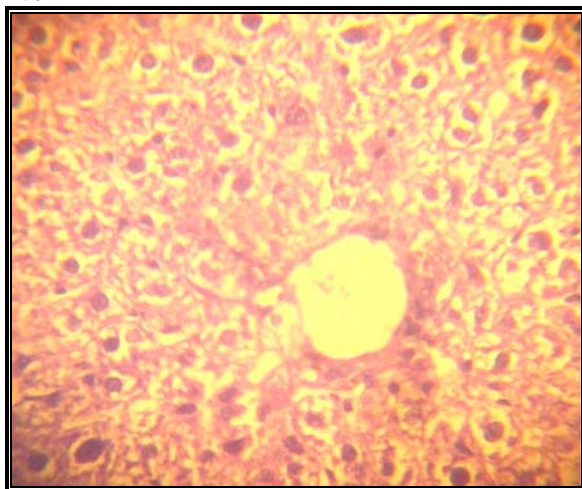
Histological pictures of organs (lung , liver and kidney) from intranasal infected mice with *A.fumigatus* conidia and control group are clearly illustrated in (figure – 1) , different histological changes found in tissues of lung included necrosis in lung alveoli with inflammatory cells infiltration and abuses formation in addition to thickness in lung alveolar sac wall and brancheolis _with hemorrhage (Figure1-a1) . While histological changes that found in the liver of test group in comparison to control group including: necrosis with the damages of hepatic cells, moreover lymphocytes infiltration and hemorrhage especially near portal space (figure1 – b1). On the other hand, no variation in the histological nature of kidney tissues was found in both studied groups. .

Lung



a- lung tissue in control group
a1-lung tissue in test group

liver



b- liver tissue in control group
b1- liver tissue in test group

Fig. -1: histological features of lung, liver in mice intranasally infected with *A. fumigatus* conidia and control group. H. & E. staining sections 40 X.

The results of enzyme activity are denoted in table -2 , significant decrease ($P < 0.05$) in enzyme activities of GOT and GPT in animals infected intranasally with *A. fumigatus* as compared with control group , concerning enzymatic activity of ALP and Creatinine kinase , results shows non significant decrease ($P > 0.05$) in both enzymes as clearly notice in table (2) .

Table (2) Enzymes activities in mice intranasally infected with *A. fumigatus* conidia and control group.

Enzymes activities Study Groups	GPT	GOT	ALP	Creatinin kinase
Control group (n=6)	143.33 ± 1.20	114.00 ± 0.93	14.00 ± 0.0	0.45 ± 0.69
Test group (n=8)	106.00 ± 0.66 *	80.33 ± 1.10 *	13.67 ± 1.22	0.38 ± 0.78

* Significant ($P < 0.05$)

Discussion:-

Infection with *Aspergillus* has been well documented in human and animals (1, 3) Although these species are not considered to be environmental pathogens , they do act as opportunistic pathogens in immunocompromised or debilitated animals. However the circumstances and host conditions allowing such infection are not fully understood (3).

Intranasal inoculation mimics the natural route of infection and seen to be a more appropriate route. Following inhalation of conidia , the fungus preferentially localizes to the lungs , and it most often presents as necrotizing pneumonia , also *Aspergillus* species have a propensity to invade blood vessels , and thus systematic dissemination , especially to the brain is often a fatal complication (14) . In this study in addition to histological changes in lung and liver, abnormalities on chemistry panel included significant ($P < 0.05$) decline in liver enzymes activities (GOT and GPT) with non significant ($P > 0.05$) decrease in both ALP and kidney creatinine kinase activities . These results are related with the degree of organs damages , the more damage and alteration in organ tissues the more decline in homogenized tissues enzymes activities , This is due to release of enzymes to the serum and increment in serum enzymes activities that clearly found in animal with nasal aspergillosis (15) . On the other hand *A. fumigatus* has been reported to produce a large of extrolites including acids and protiens, at least 22.6 potentially bioactive secondary metabolites that can be ordered into 24 biosynthetic families (16). Many extrolites are associated with conidiospores, including gliotoxin, trypacidin, verruculogen and fumigaclavine A and are thus likely to have effects in the initial lung infection process (17, 18). While liver abscesses result from fungus are common, the organisms reach the liver through one of the following pathways: 1- Ascending infection in biliary tract. 2- Vascular seeding, either portal or

arterial, 3- Direct invasion of the liver from a nearby source, or 4- apenetrating injury.(14).

Based on the present findings, it can be concluded that host can suffer from systematic diseases after inhalation of infective forms of *A. fumigatus* (conidia) and further work is needed to isolate the active components, which are responsible for pathogenesis of this opportunistic fungi.

References:

- 1- Hohl TM, Feldmesser M. *Aspergillus fumigatus* : principles of pathogenesis and host defence. *Eukaryot cell*, 2007, 6 : 1953-1963.
- 2- Pattron, D. D. *Aspergillus*, health implication and recommendations for public health food safety . *Internet journal of food safty*, 2006, 8 : 19-23
- 3- Latge , Jean- Paul . *Aspergillus fumigatus* and *Aspergillosis* . *clinical microbiology reviews*, 1999 , 310 – 350 p.
- 4- Tokarzewski , S. , Ziolkowska , G . , Lopuszynski, W. And Nozdryn- plotnicki, Z. *Aspergillus fumigatus* infection in Apigeon flock . *Bull. Vet. Inst. Pulaway*, 2007, 51 : 563-567.
- 5- Pasqualott, Alessandro C. Differences in pathogenicity and clinical syndrome due to *Aspergillus fumigatus* and *Aspergillus flavus* . *Medical Mycology*, 2008 : 51- 510, first article.
- 6- Vallon – Eberhard , A. ; Mkovitzki , A. ; Beauvais , A. ; Latge , J. P. ; Jung , S. And Shai , Y. Efficient clearance of *Aspergillus fumigatus* in murine lungs by ultrashort antimicrobial . lipopeptide , Palmitoyl _ lys _ Ala _ Dala _ lys . *Antimicrobial agents and chemotherapy*, Sep . 2008 : 3118-3126.
- 7- Jung , K. ; Kim , Y. ; Lee, H. And Kim, J. *Aspergillus fumigatus* infection in two wild Eurasian black vultures (*Aegypius monachus linnaeus*) with carbofuran insecticide poisoning . *Veterinary Journal*, 2009 , 179 : 307-312 .
- 8- Lieberman , M. A. ; Marks , A. D. Marks, basic medical biochemistry : clinical approach , Lippincott Williams and Wilkins , third edition , 2008 . 1024 pp.
- 9- Faraj , M. K. Regulation of mycotoxin formation in *Zea mays* . Ph.D. thesis . Department of bioscience and biotechnology , university of Strathelyde , Glasgow , U.K. 1990.
- 10- Gartner , L. P. ; Hiatt , J. L. ; Strum , J. M. *Cell biology and histology* . Lippincott Williams and Wilkins , 5th edition , 2006. 384pp
- 11- Retiman , S. And Frankel , A. S. A colrimetric method for determination of serum glutamic oxaloacetate and glutamic pyruvic transaminase . *Amer. J. Clin. Path.* , 1957 , 28 : 56-58.
- 12- Kind , P. R. And King , E. Estimation of plasma phosphatase by determination of phenol with amino pyrines . *J. Clin. Path.* 1954 . 7 : 322-336 .
- 13- Sorlie , D, E . *Medical biostatistics and epidemiology examination and board review* . first edition Norwalk , Connecticute , Appleton and Large , 1995 . 88pp.
- 14- Kumar , V. , Cotran , S. And Robbins , S. *Basic pathology* . Illustration by James A. Perkins Suunders , 7th .edition, 2003. 610pp.
- 15- Davidson , A. P. Pappagianis , D. Treatment of nasal aspergillosis with topical clotrimazole . In : J. D. Bonagura , ed . *Kirk,s current veterinary therapy xll: small animal practice* . Philadelphia : W. B. Saunders , 1995 . 899-901.
- 16- Frisvad , J. ; Rank, C. ; Nielsen , K. And Larsen , T. *Metabolomics of Aspergillus Fumigatus* . *Medical Mycology*, 2008 . 519 p.
- 17- Atles, A. ; Remach, AF. ; Sancho, FJ.; Sureda , A. ; Martino , R. ; Briones , J. Frequent severe liver iron overload after stem cell transplantation and its possible association with invasive aspergillosis . *Bone marrow tranplantation*, 2004. 34, 505-509.
- 18- Stanzani , M.; Orciuolo , E. ; Lewis , R.; Kantoyiannis , DP. ; Martins , S. L. And Komanduri , K. V. *Aspergillus fumigatus* suppresses the human cellular immune response via gliotoxin- mediated apoptosis of monocytes . *journal of the American society of hematology* ,2005. 105(6) : 2258-2265.