

## Protective effect of *Lactobacillus plantarum* against *Salmonella typhimurium* in mice

Shahlaa M. Salih\* BSc, PhD

Zahraa K. Zedan\* MSc

### Summary:

**Background:** Probiotics are defined as living microbial food supplements that beneficially affect the host by improving its intestinal balance. In recent years there is a great interest for viable microorganisms that promote or support a beneficial balance of microbial population of gastrointestinal tract. Probiotics may be consumed in different forms, comprising foods, mainly in fermented state and pharmaceutical products, mainly as capsules or in microencapsulated forms.

**Methods:** Twelve albino mice were divided into four groups designated as 1, 2, 3 and 4. Each group consists of 3 mice, and subject to the followings treatments: Group 1: This group was used as a control. Group 2: This group was dosed with 0.1ml. of  $0.5 \times 10^5$  cfu/ml of *Lactobacillus plantarum* culture. Group 3: This group was dosed with 0.1ml. of  $0.5 \times 10^5$  cfu/ml *Salmonella typhimurium* culture. Group 4: this group was dosed with 0.1ml of  $10^9$ cfu/ml *Lactobacillus plantarum* culture, and infected with 0.1ml of  $0.5 \times 10^5$ cfu/ml culture of *Salmonella typhimurium*, then histological sections were made from intestine and examined to evaluate protective effect of *Lactobacillus plantarum*.

**Results:** Histopathological study exhibited that intestinal sections of mice infected with *Salmonella typhimurium* showed a necrosis, degenerative changes and inflammatory cells infiltration as compared with normal sections taken from uninfected mice, while treating with *Lactobacillus plantarum* prevented the histopathological effect of *Salmonella typhimurium* on mice intestine.

**Conclusion:** Probiotic *L. plantarum* had a protective effect on intestine sections of mice infected with *Salmonella typhimurium*

**Keywords:** Probiotic, *Lactobacillus plantarum* Inhibitory effect and *Salmonella typhimurium*.

*Fac Med Baghdad*  
2010; Vol. 52, No. 4  
Received July 2009  
Accepted Jan.2010

### Introduction:

The term probiotic refers to living microorganism that survive passage through the gastrointestinal tract, and have beneficial effect on the host. (1). Probiotics have several mechanisms to exert their beneficial effect; they prevent colonization, cellular adhesion and invasion by pathogenic microorganisms, exhibit direct antimicrobial activity and stimulate the host immune response. (2) Probiotic bacteria such as Lactic acid bacteria (LAB) may have a potential effect in several gastroenterological conditions especially in the disturbance of intestinal normal flora. (3) Lactic acid bacteria have the ability to inhibit the growth of various gram positive and gram negative bacteria, this due to their ability to produce organic acids such as Lactic acids and acetic acids, hydrogen peroxide, bacteriocins, bacteriocins like substances and possibly biosurfactants. (4). *Lactobacillus plantarum* is a gram positive bacilli grouped in chains, microaerophilic, grows at 15°C but not at 45 °C and produces lactic acid, *Lactobacillus plantarum* has one of the largest genomes known among the lactic acid bacteria and is a very flexible and versatile species because of the long tradition of utilization of *Lb. plantarum* in industrial and artisanal fermentations.(5) This microbe is generally regarded as safe. In addition to the occurrence of *Lb.*

*plantarum* in our diets, this microbe is frequently encountered as a natural inhabitant of the human GI tract. The genome of *L. plantarum* is 3,308,274 bp long with 3,052 openreading frames, and a G+C content of 44.5% (6). *Salmonella typhimurium* causes gastroenteritis in humans and other mammals; when the bacterial cells enter epithelial cells lining the intestine. They cause host cell ruffling which temporarily damage the microvilli on the surface of the cell. This causes a rush of white blood cells into the mucosa, which throws off the ratios between absorption and secretion, and leads to diarrhea. In mice *S. typhimurium* causes symptoms resembling typhoid fever in humans (7).

### Materials and methods:

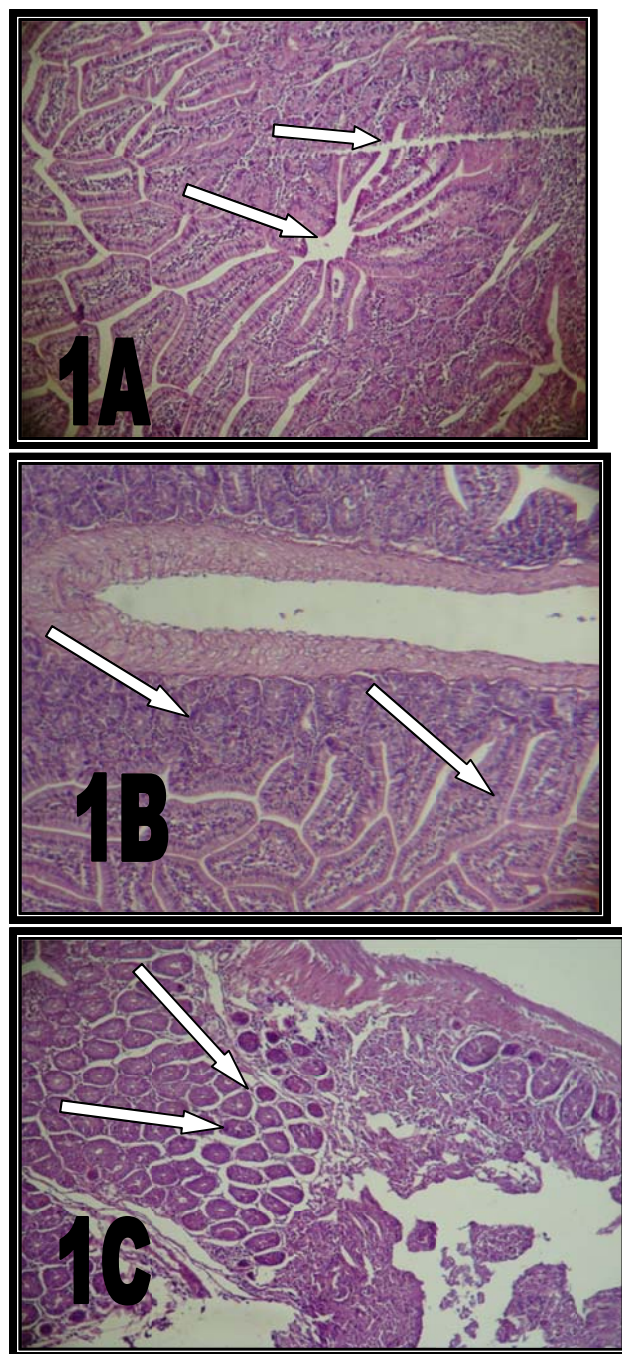
*Lactobacillus plantarum* and *Salmonella typhimurium* were supplied by microbiology Lab in the department of Biotechnology, College of Science, Al-Nahrain University. *Lactobacillus plantarum* previously isolated from infant stool and *Salmonella typhimurium* previously isolated from patients, stool infected with Salmonellosis. The *Lactobacillus* was grown in de Mann, Rogosa and Sharp (MRS) broth (Merck) media for 18 hr at a 37 °C. This activated culture was centrifuged at 2000 g at 4°C and resuspended in phosphate-buffered saline with pH 7, in order to obtain  $10^9$ colony forming units (cfu)/ml. One hundred µl of this suspension was administered to mice by gavage

\*Dept. of Biotechnology/ College of science/Al-Nahrain University.

needle, before the challenge with the pathogenic bacteria (8). *Salmonella Typhimurium* was grown in liquid brain heart infusion (BHI) medium (Difco) for 18 hr at 37°C. Mice were challenged by the oro-gastric route with 0.1 ml of the bacterial suspension containing about  $0.5 \times 10^5$  cfu which was obtained by using Mc Farland method (8). Twelve albino mice were divided into four groups designated as 1, 2, 3 and 4. Each group consists of 3 mice, and subject to the following treatment, Group 1: This was kept only on the basal diet (control). Group 2: This was fed on the basal diet, and dosed with 0.1ml of  $1 \times 10^9$  cfu/ml *Lactobacillus plantarum* culture. Group 3: This group was fed on the basal diet, and dosed with 0.1ml of  $0.5 \times 10^5$  cfu/ml *Salmonella typhimurium* culture. Group 4: This group was fed on the basal diet, and dosed with 0.1ml of  $1 \times 10^9$  cfu/ml *Lactobacillus plantarum* culture, and infected with 0.1ml of  $10^5$  cfu/ml culture. *Salmonella typhimurium*. The treatments above were repeated in the next day. A post ingestion period of 10 days was observed after the administration of the cultures (9). Mice were sacrificed by cervical dislocation and intestine was collected. Pieces were taken from previous organ (for histopathological study) and put in petridishes contain physiological salt solution to remove the fatty tissues and sticky bundles, then the organs were put in tubes containing 10 % formalin for about 16-18 hours for fixation purpose. They were transferred into tubes containing 70% ethanol in which they were preserved till the time of the final preparation. The samples were transferred into 90% ethanol for 6 hours then transferred into 99% ethanol for about 6 hours and put in xylol for 2 hours (10). Sections of about 5 $\mu$  were obtained using metal knives on a handling rotary microtome. The prepared sections put in a water bath at 43°C, and then they were stick in a glass slide in a proper manner. The staining method was performed by using hematoxylin and eosin stains (11). Pictures were taken using a digital camera for all histological slides under microscope at 20X and 40X magnification. Histopathological examination was carried out under supervision of histopathologist Prof. Dr. Salim R. Hamoudi / Department of Pathology /College of medicine / Baghdad University.

#### Results:

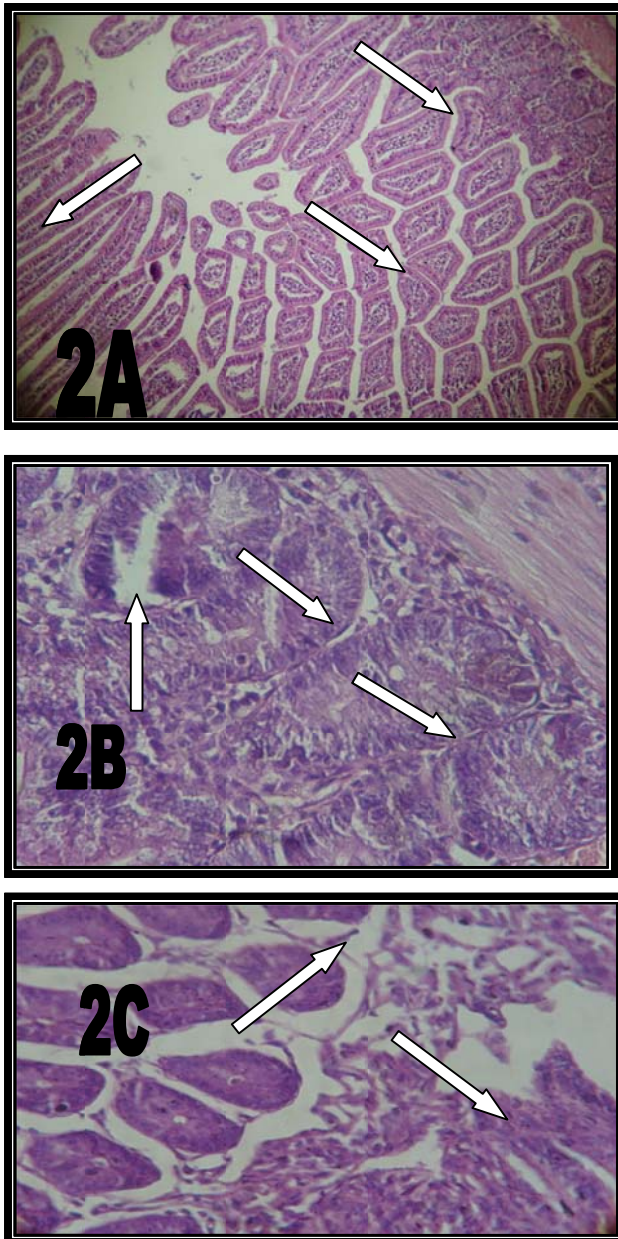
The protective effect of LAB against *Salmonella typhimurium* infection in mice was examined and the histopathological changes of intestine were observed as follows: Normal structure appearance of the intestinal villi was observed in the first and mid part of intestine Figure (1.1A and 1.1B). The final part of intestine of control group, showed the normal appearance of small intestine with appearance of peyers patch (lymph nodes) as shown in (figures 1.1C).



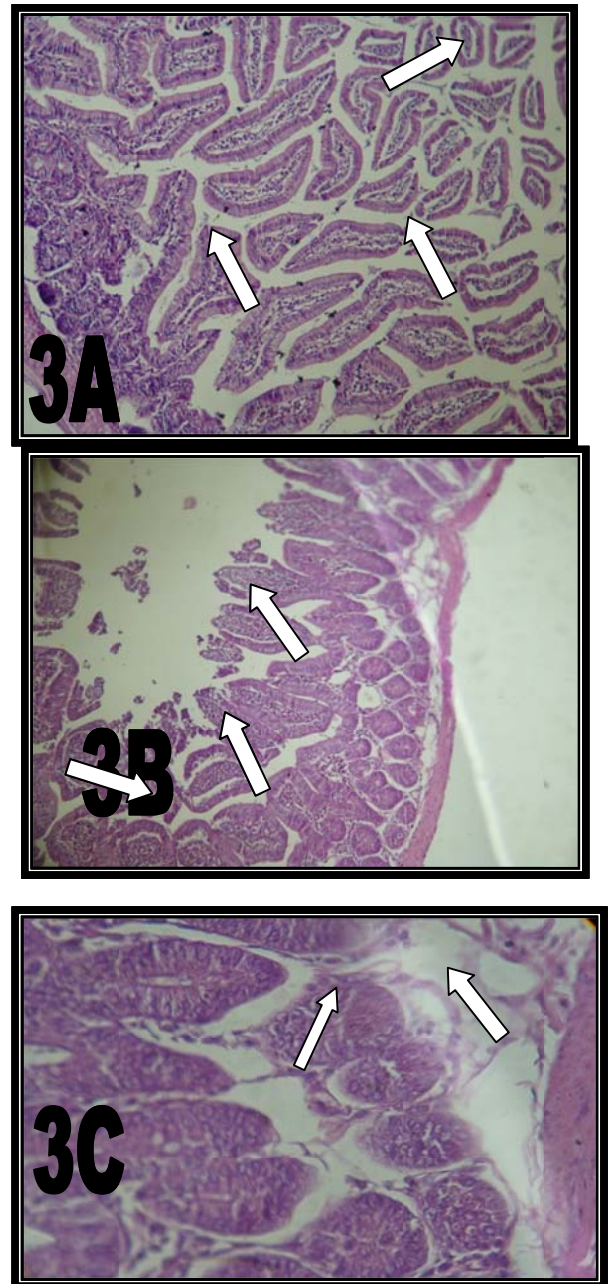
**Figure 1:** 1A- Section of first part intestine of control group showing the normal structure appearance of finger like projections (arrows). 1B- Section of mid part intestine of control group, showing the normal finger like appearance of the intestinal villi (arrows). 1C- Section of final part intestine of control group, showing the normal appearance of small intestine with appearance of peyers patch (lymph node) (arrows). (HE) 100 $\times$ . Group 2 was fed on the basal diet and was also dosed with 0.1 ml of *L. plantarum*. Section of intestine treated with *L. plantarum* exhibited normal structure appearance of intestine villi with presence of few



inflammatory cells inside the vili as shown in figure (2.2A, 2.2B and 2.2C).



**Figure2:** 2A- : first part section of intestine treated with 0.1 ml of  $10^9$  cfu/ml *Lactobacillus plantarum* showing the normal structure appearance of finger like projections (arrows) .(HE) 100 $\times$ . 2B- Section of mid part intestine treated with 0.1 ml of  $10^9$  cfu/ml *Lactobacillus plantarum* showing mild shortening of intestinal vili with moderate infiltration of inflammatory cells inside the vili (arrows). 2C- Section of final part of intestine of treated with  $10^9$  cfu/ml *Lactobacillus plantarum*, showed mild degenerative changes of intestinal mucosa cells with mild inflammatory cells infiltration(arrows). 40 $\times$ .

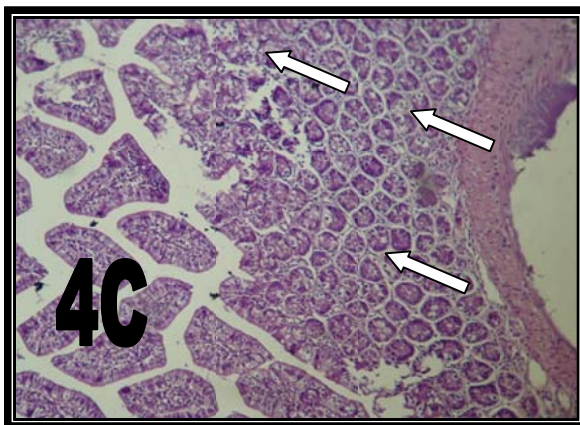
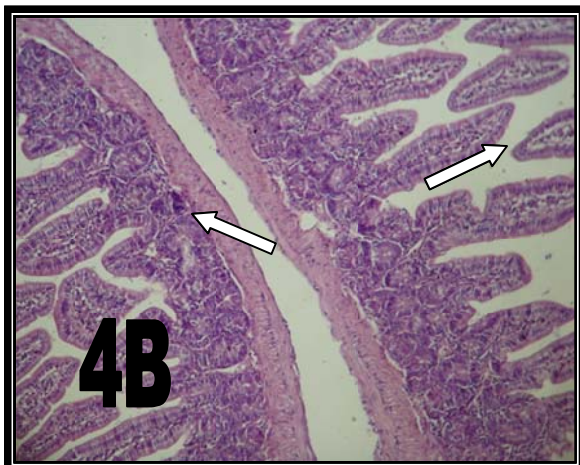
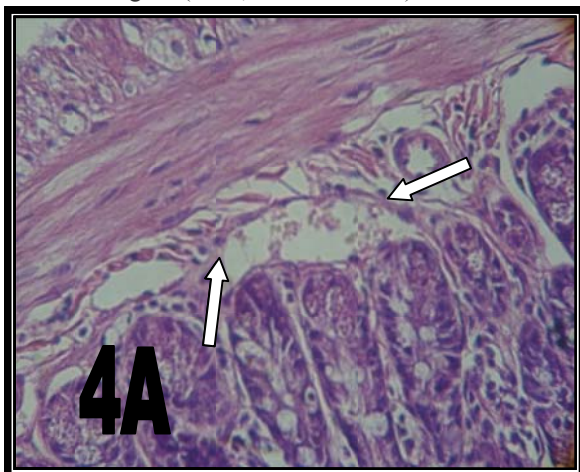


**Figure 3:** 3A- Section first part of intestine from group 3 infected with 0.1 ml of  $10^5$  cfu/ml of *Salmonella typhimurium*, showing degeneration and shortening of intestinal vili with infiltration of inflammatory cells within the vili (arrows). 3B- Section of mid part of intestine from group 3 infected with 0.1 ml of  $10^5$  cfu/ml of *Salmonella typhimurium*, showing degeneration and necrosis of intestinal mucosa, and mild shortening of intestinal vili with infiltration of inflammatory cells inside the vili (arrows) (HE) 100 $\times$ . 3C- Section of final part of intestine of treated with, 0.1 ml of  $10^5$  cfu/ml of *Salmonella typhimurium* showed mild degenerative changes of intestinal mucosa cells with mild inflammatory cells infiltration.(HE) 40 $\times$ .



Section of intestine treated with *Salmonella typhimurium* showed degeneration and shortening of intestinal villi, Figure (3.3A, 3.3B and 3.3 C).

Group 4 was fed on the basal diet, and dosed with 0.1ml of  $10^9$ cfu/ml *Lactobacillus plantarum* culture, and infected with 0.1ml of  $10^5$ cfu/ml culture of *Salmonella typhimurium*. Results revealed that Section of intestine from this group showed regenerative of intestinal villi with mild shortening of the villi as shown in figure (4.4A, 4.4B and 4.4C).



**Figure 4:** 4A-Section of first part of intestine treated with  $10^9$  cfu/ml *Lactobacillus plantarum*, and infected with 0.1 ml of  $10^5$  cfu/ml of *Salmonella typhimurium*, showing mild degenerative changes of intestinal villi (arrows) (HE) 40 ×. 4B- Section of mid part of intestine treated with  $10^9$  cfu/ml *Lactobacillus plantarum*, and infected with 0.1 ml of  $10^9$  cfu/ml of *Salmonella typhimurium*, showing normal structure appearance of intestinal villi (arrows). 4C- Section of final part of intestine showing the normal appearance of small intestine with appearance of peyers patches (lymph node) (arrows). (HE) 100×.

#### Discussion:

Mice treated with L.P *plantarum* show that normal structure appearance. This result agreed with (Yoshitaka) (12) .who showed that heat killed *Lactobacillus plantarum* strain L-137 (HK-LP) was a potent inducer of IL-12 in vitro as well as in vivo in mice. HK-LP has been shown to suppress IgE production, which induces the T helper (Th) 1 type immune response. It is known that an essential step in the pathogenesis of typhoid fevers in mice or humans is the establishment of a systemic infection after oral administration. This systemic infection usually develops from foci established in the Peyer's patches of the small intestine soon after ingestion. Thus the virulence of typhoid bacteria depends on their ability to penetrate into the Peyer's patches, to survive and multiply there, and subsequently to become disseminated and survive systemically. Virulence factors of *Salmonella* which determine the bacteria's ability to colonize the mucosa of the small intestine may depend upon certain types of pili-like capsular antigens, flagella, and lipopolysaccharide (LPS) structure (13). Mice infected with *S. typhimurium* and treated with *Lb. plantarum* showed that *Lb. plantarum* had a considerable protective effect against *Salmonella typhimurium*. Probiotics exhibit direct effects locally in the GI tract, including modulation of resident bacterial colonies and vitamin production (14). It had been shown that probiotics, such as lactobacilli or bifidobacteria, could enhance specific and total IgA secretion when used as an oral adjuvant (15), (16) and (17). Probiotics had been shown to have beneficial health effects. Many different activities had been ascribed to probiotics; however, The effects include enhanced innate and acquired immunity, as well as increased anti-inflammatory cytokine production (IL-10), and reduced intestinal permeability(18).

Jin (19) reported that receptors for the pathogenic bacteria are present in the mucus overlaying the epithelial cells of the small intestine. It was therefore proposed that the presence of receptors in mucus may play a role in intestinal pathogenesis. Much of the current interest in the intestinal microflora focuses on interactions that are thought to occur between lactic

acid bacteria (especially *Lactobacillus* spp.) and coliform bacteria. A similar result stated by ( David ) (20) who found that incubation of *L. plantarum* 299v with HT-29 cells increased MUC2 and MUC3 mRNA expression levels. From these in vitro studies, it was proposed that the ability of probiotic agents to inhibit adherence of attaching and

#### References:

- 1- Lee, Y. K. and Salminen, S. (1995). *The coming of age of probiotics*. *Trends Food Sci. Technol.*, 6: 241-245.
- 2- Doron, S. and Gorbach, S. L. (2006). *Probiotics: their role in the treatment and prevention of disease*. *Expert Rev. Anti Infect Ther.*, 4(2): 261-275.
- 3- Goossens, D.; Jonkers, D.; Stobberingh, E.; Van den Bogaard, A.; Russel, M. and Stockbrügger, R. (2003). *Probiotics in gastroenterology: indications and future perspectives*. *Scand J. Gastroenterol Suppl.*, 239: 15-23.
- 4- Fernaández, M. F.; Boris, S. and Barbe's, C. (2003). *Probiotic properties of human lactobacilli strains to be used in the gastrointestinal tract*. *J. Appl. Microbiol.*, 94: 449-455.
- 5- Dicks, L. M. T.; Silvester, M.; Lawson, P. A. and Collins, M. D. (2000). *Lactobacillus formicalis* isolated from the posterior fornix of the human vagina. *Int. J. Sys Evol. Microbiol.*, 50: 1253-1258.
- 6- Marasco, R.; Salatiello, I.; De Felice, M. and Sacco, M. (2000). *A physical and functional analysis of the newly identified bglGPT operon of Lactobacillus plantarum*. *FEMS Microbiol. Lett.*, 186: 269-273.
- 7- Tuin and Annemarie. (2005). *"On the role and fate of LPS-dephosphorylating activity in the rat liver"*. *American Journal of Physiology- Gastrointestinal and Liver Physiology*, 290 : G377-G385
- 8- Lilian, M., Elizabeth, N.; Leda, Q. and Jacques, R. (2001). *Protection by lactobacillus acidophilus UFV-H2B20 against experimental oral infection with Salmonella enterica subsp. Enterica Ser. Typhimurium gnotobiotic and conventional mice*. *Braz. J. Microbiol.*, 32(1):
- 9- Oyetayo, V. O.; Adeluyi F. C. and Akinyosoye, F. A. (2003). *Safety and protective effect of Lactobacillus acidophilus and Lactobacillus casei used as probiotic agent in vivo*. *Afri. J. Biotech.* 2(11): 448-452.
- 10- Bankroft, L. (1980): *Basic histological techniques; 4<sup>th</sup> ed; an Arboer science publishers*. Pp: 130-145.
- 11- Junquera, L. and Carneiro, J.R.O. (2005): *Male Reproductive System*. In: *Basic Histology*. Janson, M.; Harriet and Petery J., Stamford. 11<sup>th</sup> ed. Pp: 418-434.
- 12- Yoshitaka, H.; Shinji M.; Yoshihiro Y; and Tomomi, T. (2006). *Daily Intake of Heat-Killed Lactobacillus plantarum L-137 Augments Acquired Immunity in Healthy Adults*. *J. Nutr.*, 136: 3069-3073.
- 13- Arthur, W.; Gunter S. and Derrick, R. (1978). *Intestinal colonization and Virulence of Salmonella in Mice*. *Infect. And Immun.*, 22, (3): 763-770
- 14- Parvez, S.; Malik, K. A.; Ah Kang, S. and Kim, H-Y. (2006). *Probiotics and their fermented food products are beneficial or health*. *J. Appl. Microbiol.*, 100: 1171-1185.
- 15- Kaila, M.; Isolauri, E.; Soppi, E.; Virtanen, E.; Laine, S. and Arvilommi, H. (1992). *Enhancement of the circulating antibody secreting cell response in human diarrhea by a human Lactobacillus strain*. *Pediatr. Res.*, 32:141-144.
- 16- Norton, P. M.; Brown, H. W. and Le Page, R. W. (1995). *Mucosal and systemic responses following enteric exposure to lactic acid bacteria*. *Adv. Exp. Med. Biol.*, 371: 1559-1562.
- 17- Perdigon, G.; Alvarez, S.; Rachid, M.; Aguero, G. and Gobbato, N. (1995). *Immune system stimulation by probiotics*. *J. Dairy Sci.*, 78: 1597-1606.
- 18- Donglai, M.; Paul F.; and John B. (2004). *Live Lactobacillus reuteri is essential for the Inhibitory effect on tumor necrosis factor alpha-induced Interleukin-8 Expression*. *Infection and Immunity*, 72(9): 5308-5314
- 19- Jin L. Z.; Ho, Y. W.; Ali, M. A.; Abdullah, N. and Jalaludin, S. (1996). *Effect of adherent Lactobacillus spp. on in vitro adherence of Salmonella to the intestinal epithelial cells of chicken*. *J. Appl. Bacteriol.*, 81: 201-206.23-
- 20- David, R.; Sonia M.; Shu W.; and Michael A. (1999). *Probiotics inhibit enteropathogenic E. coli adherence in vitro by inducing intestinal mucin gene expression*. *Am J Physiol Gastrointest Liver Physiol.*, 276 : (4), G941-G950.