

Comparative study between saline sonohysterography, transvaginal ultrasound and biopsy in evaluation of endometrial disease in postmenopausal bleeding

Laith Ahmed FMC ,DMRD ,MBChB

Summary:

Background: Transvaginal ultrasound is used conventionally as initial investigation of patients with postmenopausal bleeding, but saline contrast sonohysterography is a better technique to reliably distinguish focal from diffuse endometrial lesion.

Objectives: to compare the ability of transvaginal ultrasonography and saline infusion sonohysterography as initial modality for the diagnosis of endometrial abnormalities in women with PMB by correlating the results with endometrial biopsy.

Patients and methods: During the period from November 2011 to MAY 2012 ,40 female patients with postmenopausal bleeding were submitted to sequential examination by transvaginal ultrasound ,and sonohysterography .the presence of focal endometrial lesions and type of lesion (endometrial hyperplasia ,polyp, submucous myoma ,or malignancy)were noted .predictive values were calculated by correlating the results with final diagnosis reached by endometrial biopsy.

Result: The sonohysterography had 89.4 % sensitivity and 90% specificity , DA 90%, compared to 60%sensitivity and 70%specificity achieved by transvaginal sonography .

The diagnostic performance of sonohysterography for 3 main endometrial abnormalities (i.e. endometrial hyperplasia ,polyps and submucous myoma) was better than transvaginal sonography. The best results were seen in cases of submucos myoma where sensitivity and specificity of sonohysterography reached to 100% as compared to TVS (66% and 95.24% respectively).

Conclusion: The results have substantiated that sonohysterography is a better tool than transvaginal sonography for the assessment of endometrial intra-cavity lesion .by providing accurate differentiation between focal and diffuse endometrial lesions.

Keywords: sonohysterography , transvaginal us , postmenopausal bleeding.

*J Fac Med Baghdad
2013; Vol.55, No. 1
Received Sept .2012
Accepted June.2013*

Introduction:

The endometrium is a very unique tissue because of its exquisite sensitivity to hormonal influences, which can translate into structural morphological change (1). The histological appearance of the endometrium varies with the age and reproductive period in women's life (2). Menopause is derived from the Greek men (month) and pauo (to stop) and is applied to the permanent cessation of menstruation due to loss of ovarian follicular activity (3). The age which menopause occurs is influenced by several factors (4).

postmenopausal bleeding is defined as the bleeding that occurs after one year of amenorrhea at the proper age (5,6). whilst it may indicate endometrial pathology including malignancy and in many cases no organic cause is found. (7). Sonography can be used to search for a thickened endometrial stripe and masses within the uterus, adnexa, or cervix. (8). Saline-Infusion Sonographic (sis) has been used to evaluate the endometrium in various clinical situations. Among others, these include abnormal uterine bleeding, polyps and submucosal leiomyomas can often be differentiated based on two findings (9). The CT and MRI imaging can be used to help evaluate the location and extent of the disease (10, 11).

*Dept of surgery, college of medicien university of Baghdad.

Saline sonohysterography is a particularly useful diagnostic tool to identify intrauterine polyps as in figure (2) (12). On TVUS HSG endometrial hyperplasia presents as focal or more commonly, diffuse endometrial thickening without a localized mass or abnormality (14,15). Endometrial cancer is the most common gynecologic malignancy, accounting for 6% of all female cancers (16). About 90% of women with endometrial carcinoma have vaginal bleeding or discharge as their only presenting symptom (17). Submucosal leiomyomas their impact on the endometrium and its blood supply most often leads to irregular uterine bleeding. Fibroids are most often associated with dysfunction bleeding, they do play a role in the etiology of PMB and account for approximately 10% of cases (18). SIS was introduced 25 years ago. First described by Nannini and Complications of SIS are minimal, and the risk of infection is less than 1 percent (18, 19).

Patient and Methods:

During the period from November 2011 to MAY 2012, a prospective study was performed in which 48 women with PMB submitted to the gynecological department at medical city ,Baghdad teaching hospital, were evaluated sonographically

at ultrasound unit. The main complaint in all these women was PMB that began at least one year after cessation of their menstrual cycles.

After performing transvaginal HSG examination for all patients (48 women) eight women were excluded from the data analysis (four patient, the HSG was unsuccessful because they had cervical mass protruded into the vagina which cause technical difficulties, two patients, cervical stenosis prevented advancement of the catheter through the cervical os. in two of patient incomplete follow up).

Each patient was informed first about the method of examination and verbal consent was obtained.

Initially transabdominal scan using a Phillips (HD 11 XE. Revision 2.0.7 Andover, MA, USA) 3.5-5MHZ electronic convex array transducer was performed to obtain a global view of the pelvis, to assess any gross structural abnormalities of the uterus and other pelvis structure and to show the state of bladder.

Patient were then asked to empty their bladders after which transvaginal ultrasound using a 5-7MHZ electronic sector transducer.

The examination was performed on an ordinary examination table in which the patient positioned supine lithotomy position and placing a speculum into the vagina to expose the cervix, the external os was cleansed with povidon iodine. A6F balloon catheter was used.

The advancement of the catheter was aided by grasping the tip with ring forceps and carefully threading it approximately 5-10cm into the endometrial canal to position the tip beyond the endocervical canal. A6F balloon catheter was inflated by (3-4ml of saline fluid), the speculum was then carefully removed while the catheter was left in place. Next, the transvaginal probe was sheathed with a rubber glove that contains a gel. additional gel was applied to the sheathed transducer. then the probe was inserted into the vagina and continuous scanning in the sagittal and coronal planes was performed during instillation of sterile saline solution (0.9% NaCl). various amounts (10-25 ml or more) of sterile saline solution was injected slowly through the catheter under direct sonographic visualization to evaluate the distention of the uterine cavity, only 5-10 ml are actually needed to distended the cavity adequately. cervical leakage is common, and it is helpful to have two 20-ml syringes of saline solution available for procedure. Multiple sagittal and coronal images were then obtained.

Results:

Table (1) show the age distribution of all patients.

Table (2) show the age distribution of menopause of all Patients. At histopathological examination of all forty women, 21 had atrophic endometrium the same on SHG and 20 on TVS, nine patients had endometrial hyperplasia (on SHG 10 and TVS 17), three patients had submucosal myoma (3 on SHG & 2 on TVS) another three patients had endometrial polyp (4 on SHG and 1 on TVS). The remaining four patients had

endometrial carcinoma (2 case on SHG) as shown in table (3). The SHG was more sensitive and specific as compared to TVS alone; the sensitivity and specificity of TVS were 60% and 71.42% respectively as compared to sensitivity and specificity of SHG which were 89.47% and 91.30% respectively. the PPV and NPV of SHG was 93% and 98.46% respectively as compared to PPV and NPV for TVS which were 70.5% and 77.9% respectively, the diagnostic accuracy of SHG (90.47%) was significantly better than that of TVS (76.47%) as shown in table (4). The diagnostic performance of TVS and SHG in identifying various causes shown in table (5).

Table (1) Age distribution of all patients

Age group (year)	No.	Percentage %
45-49	2	5
50-54	11	27.5
55-59	14	35
60-64	8	20
65-69	4	10
≥70	2	2.5
Total	40	100

Age range :45-75 years

Mean age (±S.D) : 59.5 ± 3.93 years

Table (2) Age distribution of menopause of all patients

Age	No.	Percentage %
45-49	20	50
50-54	18	45
55-59	2	5
Total	40	100

Age range : 45-59 years

Mean age of menopause (Mean age ±S.E.M.) : 52 ± 2.9 years

Table (3) diagnosis of 40 patients with PMB provided by three investigation modalities.

Diagnosis	Histopathological diagnosis NO. of patients	TVS diagnosis NO. of patients	SHG diagnosis NO. of patients
Endometrial hyperplasia	9	22.5%	17
Submucosal fibroid	3	7.5%	2
Endometrial polyp	3	7.5%	1
Normal atrophic	21	52.5%	20
Endometrial cancer	4	10%	2
Total	40	100%	40

Table (4) diagnostic performance of TVS and SHG

Test	Sensitivity%	Specificity%	PPV%	NPP%	DA%
TVS	60	71.42	70.5	77.9	76.47
SHG	89.47	91.30	93	98.46	90.47

Table (5) diagnostic performance of TVS and SHG in identifying various causes

Diagnosis	Test	Sensitivity	Specificity	PPV	NPV	DA
Endometrial Hyperplasia	TVS Diagnosis	100.0%	79.5%	52.9%	100.0%	83%
	SHG Diagnosis	100.0%	96.9%	90.0%	100.0%	97.6%
Submucosal Fibroid	TVS Diagnosis	66.7%	100.0%	100.0%	97.4%	97.6%
	SHG Diagnosis	100.0%	100.0%	100.0%	100.0%	100.0%
Endometrial Polyp	TVS Diagnosis	33.3%	100.0%	100.0%	95.12%	95.2%
	SHG Diagnosis	100.0%	97.3%	75.0%	100.0%	97.5%
Normal Atrophic	TVS Diagnosis	95.2%	100.0%	100.0%	95.0%	97.6%
	SHG Diagnosis	100.0%	100.0%	100.0%	100.0%	100.0%
Endometrial Cancer	SHG Diagnosis	50.0%	100.0%	100.0%	92.3%	95.2%

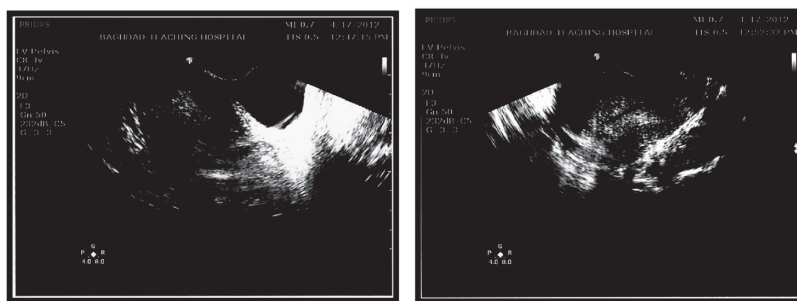


Figure (1) A. TVS in patient with PMB shows endometrial thickness, figure B- SHG in same patient shows endometrial hyperplasia.

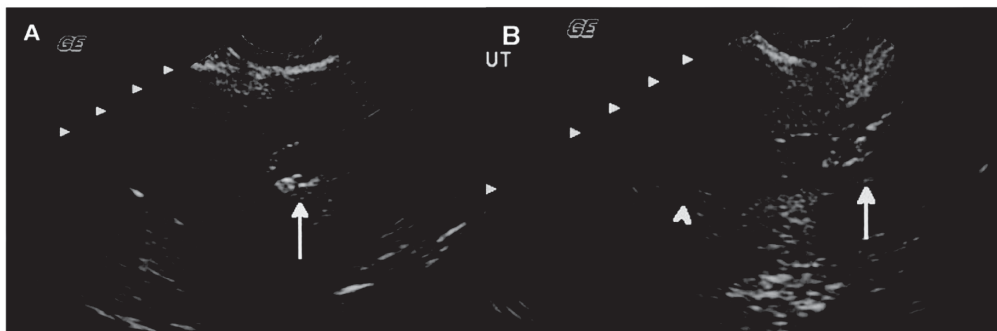


Fig.(2). Sagittal SHG in 63-year-old woman with postmenopausal bleeding. (A) Initial saline infusion reveals no focal abnormalities. The catheter (arrow) is in the inferior aspect of the endometrial cavity. (B) After retraction of the catheter into the superior portion of the cervical canal (arrow), a focal endometrial lesion arising from the posterior endometrial surface in the lower uterine segment is revealed (arrowhead). Pathology showed a benign endometrial polyp.

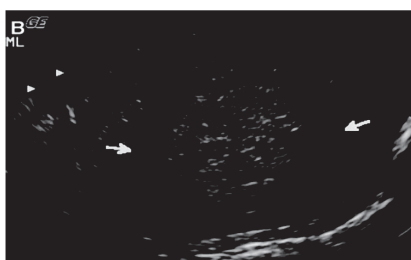


Figure. (3). SHG shows that this fibroid projects approximately 50% of its total volume into the endometrial cavity (arrows).

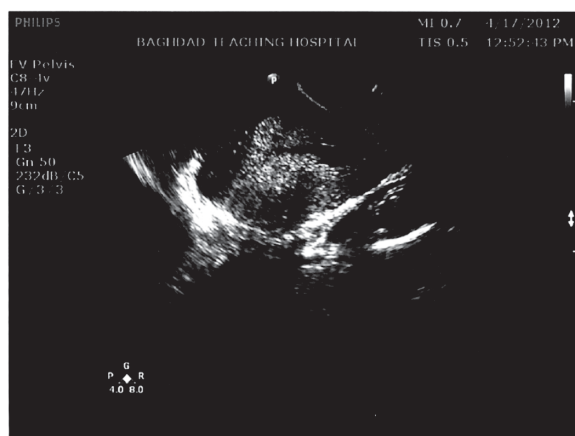


Figure (4) SHG in 70 years patient present with PMB shows focal irregular echogenic lesion on back ground of endometrial hyperplasia .patient with endometrial carcinoma.

Discussion:

Transvaginal ultrasonography has been used extensively in the evaluation of patients with PMB. Many previous studies in the literature have substantiated that TVS was quite a sensitive method to evaluate the abnormal uterine bleeding. The diagnostic accuracy of TVS varies depending upon the expertise of the investigators, the sensitivity being 87% (range 24–96%) and the specificity 82% (range 29–93%)^(20,21,22)

In the present study, the results were indicated; 60% sensitivity, 71.42% specificity, 70.5% PPV, and 77.9% NPV.

Despite the wide spread use of TVS for initial evaluation of PMB, the number of studies in the literature is growing which indicate that TVS has its limitations in depicting small nodular lesions, which are isoechoic within the endometrium, and even a normal thickness endometrium may be seen to represent endometrial hyperplasia^(21,22,23)

Similarly, TVS also cannot differentiate submucosal from intramural leiomyoma and cannot differentiate between focal or diffuse endometrial lesions in many instances, which is an important distinction for selection of cases for hysteroscopic resection of these lesions (24,25).

Our study results indicate that out of 3 cases of submucous myomas, one was misinterpreted as intramural by TVS but correctly located by SHG. And three cases of endometrial polyps, two of them were misinterpreted as endometrial hyperplasia but correctly diagnosed by SHG. These results are in agreement with the study by Laifer-Narin et al., who claim that 14% of 114 patients showing normal TVS findings revealed abnormalities on SHG⁽²⁶⁾.

There are many advantages of using saline contrast sonohysterography as an initial evaluation test in post menopausal bleeding. Owing to its ability to demonstrate small endometrial lesions and its reliability to differentiate between focal and diffuse endometrial lesions, SHG can be used as a method of choice to evaluate patients with PMB (figure 1).

The sensitivity and specificity of SHG have been reported to

be as high as 85–91% and 83–100%, respectively.

O'Connell et al., Ryu et al., Alborzi et al., Wongsawaeng and Aslam et al., result have shown 92.9% Sensitivity, 89.7% Specificity, 86.7% PPV, and 94.5% NPV for SHG to diagnose intra-cavity endometrial lesions^(16,27,28,29,35)

The present study results have shown that 89.47% sensitivity, 91.3% specificity, 93% PPV and 98.4% NPV for SHG to diagnose intracavity endometrial lesions. Over all diagnostic accuracy was 90.47%.

Similar high accuracy rates ranging from 84% to 96% have been reported by other studies; Epstein et al., Wongsawaeng, Ragni et al., and Aslam et al.,^(29,30,31,35)

Three commonly seen lesions in cases of PMB are submucous myoma, endometrial polyps and hyperplasia. There have been several reports of the diagnostic value of SHG in differentiation of these diseases.

Kamel et al. in a study of 106 patients with AUB has achieved 93.3% sensitivity, 94.6% positive predictive value and 93.3% diagnostic accuracy in the detection of endometrial polyps by SHG (32)

Soares et al. has reported 100% sensitivity, 100% positive predictive value and 100% diagnostic accuracy for polypoid lesions, including endometrial polyps, fibroids and endometrial hyperplasia (33)

Nanda et al., reported 100% sensitivity of SHG in detecting endometrial

polyps (34), sent study the endometrial polyps are hyperechoic compared with normal myometrium and contrast with the relatively hypoechoic submucosal fibroids (figure 2)

The more difficult differential diagnoses were those of pedunculated leiomyomata that mimicked polyps and flattened adherent polyps that mimicked focal hyperplasia or leiomyomata using the color Doppler criteria of a single central vessel for a polyp and generalized hyper vascularity for a leiomyoma helped in establishing these difficult differential diagnoses.

Bree., reported that 100.0% sensitivity, 97.3% specificity, 75.0% PPV, 100.0% NPP, 97.5% DA of SHG in endometrial polyps there one case reported false positive as a polyp were found a focal hyperplasia^[21] Compared with Aslam et al., reported 90% sensitivity, 98.11% specificity, 90% PPV, 98.11 NPP, 96.83% DA^[6].

Leone et al., correctly diagnosed all 48 cases of submucosal fibroids by using SHG^[25] Aslam et al., reported the accuracy of SHG 100% in differentiated submucosal fibroid from intramural fibroid^[35]

The data and results from the present study are in agreement with the above-mentioned published reports and the accuracy of SHG in differentiating submucosal from intramural fibroids was found to be 100% in the present study. Sonohysterography showed a hypo echoic mass with an overlying echogenic endometrium in most cases, which established the subendometrial location. Submucosal fibroids may show acoustic attenuation, Some may prolapse almost entirely into the endometrial cavity (figure 3).

Postmenopausal vaginal bleeding is an important and common problem. It can present symptom of endometrial cancer, the most common gynecologic malignancy. In the present study only two cases of endometrial carcinoma were detected (figure 4) and others two cases misdiagnosed as endometrial hyperplasia on TVS and SHG both. Our retrospective review of these cases indicated small lesions associated with adenomatous hyperplasia detected on endometrial biopsy. Epstein et al., has reported that hysteroscopy is superior to both SHG and TVS for discriminating between benign and malignant lesions (sensitivity, 84%, 44%, and 60%; false-positive rate, 15%, 6% and 10%, respectively). However, neither hysteroscopy nor saline contrast sonohysterography can reliably discriminate between all the benign and malignant focal lesions and biopsy is usually indicated to further evaluate such lesions^[30]

Most endometrial abnormalities, including carcinoma, appear as a focal mass on ultrasonography; therefore, women with multifocal or sessile lesions should undergo a hysteroscopic guided biopsy. The SHG is useful in identifying benign pathologic conditions of the endometrium and can help in the triage for hysteroscopic versus nondirected endometrial biopsy. We recommended that saline contrast sonohysterography should be used as an initial investigation in cases of postmenopausal bleeding.

Conclusions:

Our results have substantiated that SHG is a better tool as compared to TVS for the assessment of endometrial intra-cavity lesions. By providing accurate differentiation between focal and diffuse endometrial lesions.

References:

1. Rosai J. (2004): *Ackerman's surgical pathology. Volume 3. mosby comp. st. louis.* Pp; 1392-1423.
2. Christopher P. (2009): *The Female Genital Tract. In Robbins: Basic pathology of disease. 7th ed.* Pp; 1059-1118.
3. Panay N. (2007): *menopause and postmenopausal women. In Edmonds DK Dewhurst's textbook of obstetrics and gynecology for postgraduate. 5th ed. Black well ltd. London.* Pp; 479-495.
4. Goodwin TM., Nathan L., DeCherney AH. (2007): *Current Diagnosis & Treatment Obstetrics & Gynecology. 10th ed., The McGraw-Hill Companies. United States of America. (Menopause & Postmenopause).*
5. Merwe H. (2010): *Postmenopausal bleeding. Obstetrics & Gynaecology; South Africa. 13.* Pp; 9-13.
6. Schorge JO., Schaffer JL., Halvorson LM., and Hoffman BL. (2008): *Williams Gynecology. 7th ed. McGraw-Hill Companies. Philadelphia.* Pp; 73-124, 948-976.
7. Goldstein SR. (2006): *Abnormal uterine bleeding : the role of ultrasound . Ultrasound clinics. 1.* Pp; 415-424.
8. Moschos E., Ashfaq R., Donald D. (2009): *Saline -Infusion Sonography Endometrial Sampling Compared With Endometrial Biopsy in Diagnosing Endometrial Pathology. Obstetrics & Gynecology. 113.* Pp 881-887.
9. Jorizzo JR., Riccio GJ., Chen MY., Jeffrey J. (2007): *Sonohysterography: The Next Step in the Evaluation of the Abnormal Endometrium. Radio Graphics. 19.* Pp 117- 130.
10. O'Neill MJ. (2003): *Sonohysterography. (Division of Abdominal Imaging and Interventional Radiology, Massachusetts General Hospital). Radiol. Clin. N. Am. 41 .* Pp; 781– 797.
11. Szymanski LM. and Fortner KB. (2007): *Abnormal Uterine Bleeding. In Fortner KB., Szymanski LM., Fox HE, and Wallach EE. : Johns Hopkins Manual of Gynecology and Obstetrics. 3rd . ed. Lippincott Williams and Wilkins.* Pp; 419-427.
12. Groma TO. and Holling WT. :(2008): *postmenopausal bleeding : In Dunlop W. and Ledger W. Recent advances in obstetrics and gynecology. 24th ed., the Royal society of medicine press limited. Britain.* Pp; 245-258.
13. Sala E., Allison S., Ascher SM., and Hricak H. (2008): *Imaging in Gynaecology. In : Adam A., Dixon AK., Grainger R., and Allison DJ. : Grainger & Allison's Diagnostic Radiology. 5th . Ed. Elsevier Churchill. Livingstone.*
14. Crofton M. (2007): *gynecological imaging. In : SUTTON D.; Textbook of radiology and imaging. 7th . ed. Elsevier Churchill. Livingstone.* Pp; 1069-1078.
15. Nelson AL. and Gambone JC. (2010): *Uterine corpus carcinoma. In Hacker NF., Gambone JC. and Hobel CJ. Essentials of obstetrics and gynecology. 5th ed., Saunders Elsevier. Philadelphia.* Pp; 428- 452.
16. Mounsey AL. (2002): *Post menopausal bleeding; Evaluation and Management. Department of Family Medicine, Primary Care Centre, University of Virginia. 4.* Pp; 173-192.
17. Bonnamy L, Marret H, Perrotin F, Body G, Berger C, Lansac J. (2002): *Sonohysterography: a prospective survey of results and complications in 81 patients. Eur J Obstet Gynecol Reprod Biol. 102:*42–7.
18. Nannini R, Chelo E, Branconi F, et al. (1981): *Dynamic echohysteroscopy: a new diagnostic technique in the study of female infertility. Acta Eur Fertil. 12.* Pp; 165–71.
19. Parsons AK, Lense JJ. (1993): *Sonohysterography for endometrial abnormalities: preliminary results. J Clin Ultrasound. 21.* Pp;87–95
20. Ryu JA., Kim B., Lee J., Kim S., Lee SH., (2004) : *comparison of transvaginal ultrasoundography with hysterosonography as screening method in patients with abnormal uterine bleeding. Korean J Radiol. 1.* Pp 39-46.

21. Bree RL., Bowerman RA., Bohm-Velez M., Benson CB., Doubilet PM., DeDreu S., Punch MR. (2000): US evaluation of the uterus in patients with postmenopausal bleeding: A positive effect on diagnostic decision making. *Radiology*. 1. Pp 260-4.
22. Lanlchandani S, Phillips K. (2003): Evaluation of endometrial cavity investigation options. *Rev Gynaecol Prac*. 3. Pp; 165-70.
23. Saidi MH, Sadler RK, Theis VD, Akright BD, Farhart SA, Villamueva GR. (1997): Comparison of sonography, sonohysterography, and hysteroscopy for evaluation of abnormal uterine bleeding. *J Ultrasound Med*. 16. Pp; 587-91
24. Becker E, Jr, Lev-Toaff AS, Kaufman EP, Halpern EJ, Edelweiss MI, Kurtz AB. (2002): The added value of transvaginal sonohysterography over transvaginal sonography alone in women with known or suspected leiomyoma. *J Ultrasound Med*. 21. Pp; 237-47
25. Leone FPG, Lanzani C, Ferrazzi E. (2003): Use of strict sonohysterographic methods for preoperative assessment of submucous myomas. *Fertil Steril*. 79. Pp; 998-1002
26. Laifer-Narin S, Ragavendra N, Parmenter EK, Grant EG. (2002): False normal appearance of the endometrium on conventional transvaginal sonography: comparison with saline hysterosonography. *Am J Roentgenol*. 178. Pp; 129-33
27. O'Connell LP, Fries MH, Zeringue E, Brehm W. (1998): Triage of abnormal postmenopausal bleeding: a comparison of endometrial biopsy and transvaginal sonohysterography versus fractional curettage with hysteroscopy. *Am J Obstet Gynecol*. 178. Pp; 956-961.
28. Alborzi S, Parsanezhad ME, Mahmoodian N, Alborzi S, Alborzi M. (2007): Sonohysterography versus transvaginal sonography for screening of patients with abnormal uterine bleeding. *Internat. J Gynecol Obstet*. 96. Pp; 20-23
29. Wongsawaeng W. (2005): Transvaginal ultrasonography, sonohysterography and hysteroscopy for intrauterine pathology in patients with abnormal uterine bleeding. *J Med Assoc Thai*. 88. Pp; 77-81
30. Epstein E, Ramirez A, Skoog L, Valentin L. (2001): Transvaginal sonography, saline contrast sonohysterography and hysteroscopy for the investigation of women with postmenopausal bleeding and endometrium > 5 mm. *Ultrasound in Obstet Gynecol*. 18. Pp; 157.
31. Ragni G, Diaferia D, Vegetti W, Colombo M, Arnoldi M, Crosignani PG. (2005): Effectiveness of Sonohysterography in Infertile Patient Work-Up: A Comparison with Transvaginal Ultrasonography and Hysteroscopy. *Gynecol Obstet Invest*. 59. Pp; 184-8.
32. Kamel HS, Darwish AM, Mohamed SA. (2000): *Comparison of transvaginal ultrasonography and vaginal sonohysterography in the detection of endometrial polyps. Acta Obstet Gynecol Scand*. 79. Pp; 60-4.
33. Soares SR, Barbosa dos Reis MM, Camargos AF. (2000): Diagnostic accuracy of sonohysterography, transvaginal sonography, and hysterosalpingography in patients with uterine cavity diseases. *Fertil Steril*. 73. Pp; 406-11.
34. Nanda S, Chadha N, Sen J, Sangwan K. (2002): Transvaginal sonography and saline infusion sonohysterography in the evaluation of abnormal uterine bleeding. *Aust NZ J Obstet Gynecol*. 42. Pp; 530-34.
35. Aslam M., Ijaz L. and Tariq Sh. (2007): Comparison of Transvaginal Sonography and Saline Contrast Sonohysterography in Women with Abnormal Uterine Bleeding: Correlation with Hysteroscopy and Histopathology. *Int J Health Sci. Qassim*. 1; Pp; 17-24.