

Amyand's hernia with healthy looking vermiform appendix, treatment of three cases with review of literatures

DOI: <https://doi.org/10.32007/med.1936/jfacmedbagdad.v60i3.11>



This work is licensed under a [Creative Commons Attribution-NonCommercial 4.0 International License](https://creativecommons.org/licenses/by-nc/4.0/).

Nabil I. Naiem* FICBS, CABS

Introduction:

The term Amyand's hernia refers to an incarcerated inguinal hernia containing the vermiform appendix, which may be completely healthy, inflamed or perforated. (1)

Amyand's hernia is named after Claudius Amyand, who on December, 6,1735 performed the 1st successful appendectomy during the treatment of 11 years old boy presented with right inguinal hernia. During the surgery Amyand found a pin within the appendix which was encrusted with stone the appendix was found within the inguinal hernia sac. (2) It should not be confused with the incidental findings of cecal appendix within the femoral hernia sac "de Garengot's hernia" which is first described by Rene de Garengot in 1731(3,4)

In almost 1% of all inguinal hernias Amyand's hernia is detected and acute appendicitis in Amyand's hernia cases accounts only for 0.1% "0.07-0.13". (5)

The reported mortality rate of Amyand's hernia ranges from 5.5%- 30%.

This variation occurs due to the effect of early diagnosis, giving proper treatment, preventing intra abdominal sepsis, and good postoperative care. (6) It is generally accepted that surgical treatment of Amyand's hernia includes both appendectomy and hernia repair. (5,6,7)

However, appendectomy in the absence of an inflamed appendix and the use of mesh in cases of appendectomy remain to be controversial.

Some authors offer not to perform prophylactic appendectomy when non inflamed appendix is incidentally found in the hernial sac. (6)

Others believe that appendectomy should be performed in all cases to prevent future reherniation and appendicitis. (8,9) It has been thought that it is impossible to reach sufficient number of Amyand's hernias cases to get evidence-based data due to its rarity. Therefore it is logical to revise the classification and surgical treatment of Amyand's hernia based on the case reports from different institutions. The aim of this study is to review the experience of mesh inguinal hernia repair without performing appendectomy in patients with Amyand's hernia with healthy looking vermiform appendix with close postoperative follow up to detect recurrence or other postoperative complications.

Keywords: Amyand's hernia, vermiform appendix, mesh repair.

JFac Med Baghdad
2018; Vol.60, No .3
Received Oct. 2018
Accepted July. 2018
Published: Dec.2018

Case presentations:

This is a retrospective review of the case histories of (402) inguinal hernia cases operated by our team in **Shahid** Ahmed Ismail hospital – As Sulaimania – IRAQ in the five years period extending from April 2013 to April 2018.

All the cases included were elective cases, and the informations were obtained from their medical records.

Three male patients presented with Amyand's hernia "0.74%". all patients was diagnosed incidentally intraoperatively, and all of them presented with healthy appearing vermiform appendix within the hernia sac of **right** indirect inguinal hernia, which corresponds to **type "A"** and **type "1"** according to Fernando and ceuleman's (10,11) {table1-} and Losanoff and Basson's (12,13) {table-2-} classifications respectively.

Contents reduction, herniotomy, suture ligation of the peritoneum with tension free prolene mesh repair done for all of them.

The follow up period extending from July 2015 to April 2018 with a minimal period of (14) months revealed no postoperative wound infection, appendicitis, or hernia recurrence.

Case -1- :

A 55 years old man presented with right inguinal hernia which is non incarcerated but causing pain and discomfort to the patient, no history of preoperative bowel compromise. Intraoperatively the appendix appeared healthy with small band of adhesions connecting the side of the hernia sac to the mesoappendix (**PIC-1-**).

The case was operated at June,13,2015.

Case -2- :

A 20 years old man presented with irreducible right inguinal hernia with mild tenderness but no signs of

*Al-Shaheed Ahmed Ismail Hospital
nabil_naiem@yahoo.com

bowel obstruction. Also the appendix presented healthy looking in the hernia sac with no bands of adhesions (PIC-2-).

The operation was done at October,4,2016.

Case -3- :

A 61 years old man presented with right inguinal hernia and inguinal pain with sensation of small induration area "1*1cm" at the site of deep inguinal ring even after reduction of hernia contents so, ultrasound examination done which revealed nothing.

At time of operation a long but completely healthy appendix was found in the hernia sac (pic-3-)

The operation was done at February, 2, 2017.

Discussion and review of articles:

The varying methods of surgical treatment of Amyand's hernia according to the published reports, which ranges from tissue repair of inguinal hernia to the hernia repair with biologic mesh with or without appendectomy have made the decision a challenging issue.

Preoperative clinical diagnosis is practically impossible, but has been reported via trans abdominal ultrasound or computed tomography. (5)

The later, a tubular blind- ended structure originated from the cecum wall is observed & extends to the hernia sac (pic.4), and the former reveals similar findings, a blind ended non compressible tubular structure and increased vascularity. (5,14)

There are no sensitivity or specificity reports in the international literatures to this particular clinical entity. (5,14)

Our three patients had no history of bowel problems, so no preoperative radiological investigations were done.

In 2007 Losanoff & Basson created a classification scale to identify and treat Amyand's hernia (12, 13)

A type 1 hernia has a normal appendix and an inguinal hernia, which is managed with a reduction & mesh repair.

Type 2-4 have acute appendicitis within inguinal hernia sac.

Type 2 has an inflamed non perforated appendix, type 3 has a perforated appendix, and type 4 is complicated with intra-abdominal pathology.

Types 2-4 hernias are managed with appendectomy and primary repair without mesh. In addition to the primary repair and appendectomy, type 3 includes a laparotomy for abdominal irrigation, possible orchiectomy or colectomy, and type 4 includes investigation of pathology. (12,13)

In the case of a normal appendix, incidentally found within the hernia sac, the performance of a prophylactic appendectomy along with hernia repair is not favored by many authors. (6,15)

Appendectomy adds the risk of infection to an otherwise clean procedure. Superficial wound infection increases morbidity; and deep infection may contribute to hernia recurrence, in addition surgical manipulation to achieve visualization of the entire appendix and its base, by enlarging the hernia

defect or distending the neck of the hernia sac, increases the possibility of recurrence by weakening the anatomic structures around the defect(12,15,16,17)

In the cases where an inflamed, suppurative, or perforated appendicitis were encountered, no prosthetic materials should be used because of the increased risk of surgical site infection as well as the possibility of fistulae formation from the appendicular stump.

In these cases, in addition to appendectomy a shouldice technique should be considered because of its lower recurrence rate. (18,19)

The absence of inflammation in type 1 advocates elective hernioplasty.

Using a prosthetic material in such cases carries the expectation of improved longevity of the repair; it avoids tension on the suture lines and circumvents the metabolic problems related to collagen deficiency which is known to exist in hernia patients. (12, 13)

With the new prosthetic materials such as biological mesh, current surgical approach in Amyand's type 2 hernias suggest its use to prevent recurrence. There are very few case reports in the international literatures so future research will focus on proving its efficacy; a disadvantage is that it is not available in all hospital settings. (20)

In the pediatric population, however a prophylactic appendectomy would have been performed "without mesh repair", because children and adolescents have a higher risk of acquiring acute appendicitis. (12,13)

While reduction of hernia contents & performing tension – free hernia repair is recommended for type 1 Amyand's hernia by international literatures (5,7,12,13,21), in septic patients with an Amyand's hernia type 3 "acute appendicitis with peritonitis", or type 4 "acute appendicitis with other pathology" even the hernioplasty may be contraindicated if the patient's condition is poor or the life expectancy is limited.

In a study performed in Istanbul, turkey there were five male patients in the study group with a mean age of 42.4 years, four right sided and one bilateral inguinal hernia. Despite that all the patients included in the study presented with healthy appearing vermiform appendix, Appendectomy plus mesh hernia repair was performed in all. Post-operative courses were uneventful. During the follow up period (14.0 +/- 7.7 months), there was no inguinal hernia recurrence. (22)

We also encountered a study done by Psarras et al. included four patients, one of them with inflamed appendix treated with appendectomy plus bassini repair, two of them were with normal appendix treated with mesh repair without appendectomy , and one case with appendicitis treated with appendectomy and mesh repair with no incidence of postoperative wound infection or hernia recurrence. (23)

Our patients were treated with mesh repair without appendectomy as all of their hernias contained

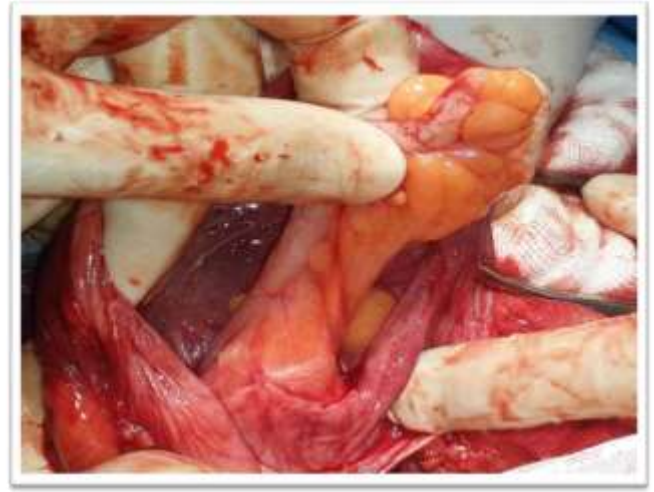normal appearing vermiform appendix, the postoperative course was uneventful & at the follow up period no hernia recurrence was recorded. Review of international literatures related to this subject may give the surgeon a better ability to take the most appropriate & individualized approach.

Table -1- Fernando & ceulemans Classification of amyand's hernia

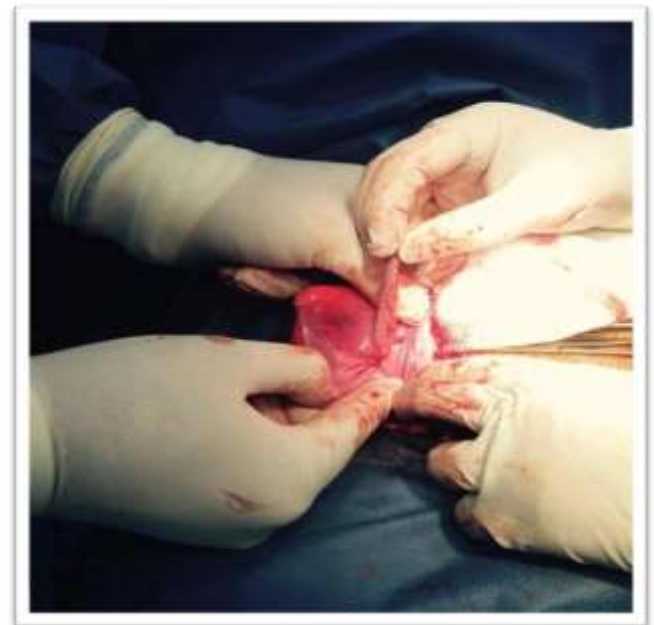Types	Findings
Type A	Normal appendix , non inflamed.
Type B	Acute appendicitis , localized in the Sac.
Type C	Acute appendicitis , perforated , peritonitis.

Table -2- Losanoff & Basson Classification of Amyand's Hernia

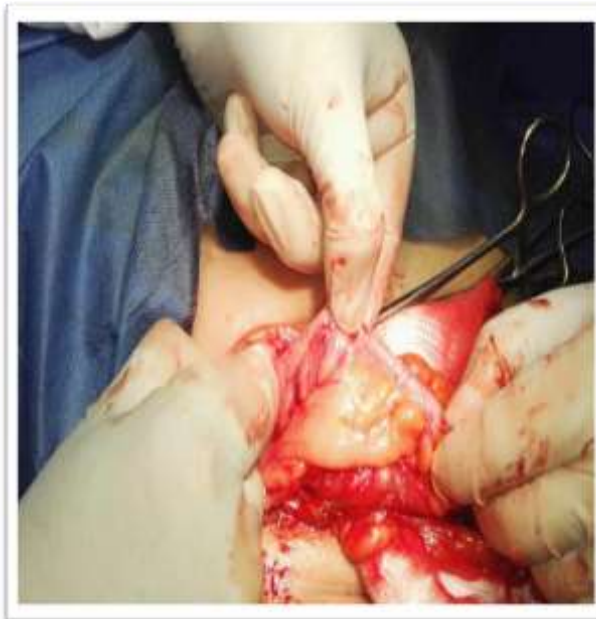Classification	Description	Management
Type 1	Normal appendix in an inguinal hernia	Hernia reduction , mesh placement
Type 2	Acute appendicitis in an inguinal hernia with no abdominal sepsis	Appendectomy , primary no prosthetics hernia repair
Type 3	Acute appendicitis in an inguinal hernia with abdominal and abdominal wall sepsis	Laparotomy , appendectomy , and primary no prosthetic hernia repair
Type 4	Acute appendicitis in an inguinal hernia with abdominal concomitant pathology	Same as type 3 plus management of concomitant disease



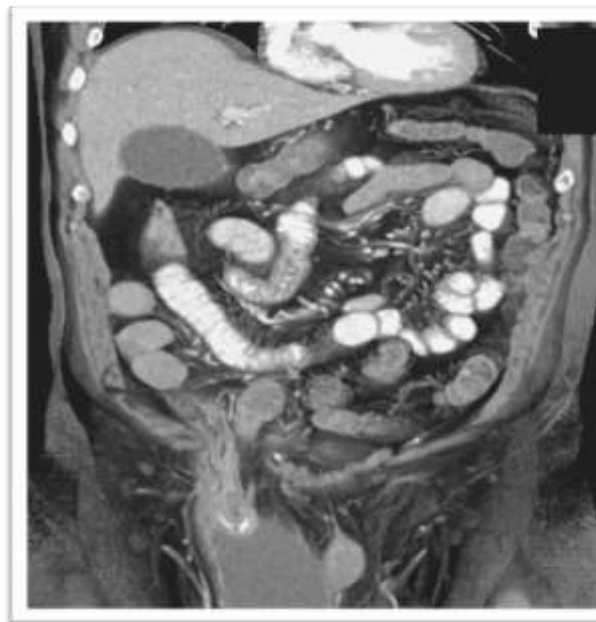
PIC-1-



PIC- 2 -



PIC-3-



PIC 4

Conclusion:

Amyand's hernia is a rare condition, with a challenging decision of treatment which will depend on multiple factors.

It is important to have a good background about the types of this hernia & its different modalities of treatment.

References:

- (1) Ali SM, Malik KA, Al-qadhi H: Amyand's hernia: study of four cases and literature review. *SQU medical journal*, 2012;12:232-36.
- (2) C: of an inguinal rupture, with a pin in the appendix caeci incrusted with stone: and some observations on wounds in the gut. *Philosophical*

transaction of the royal society of London 1736;39:329.

(3) Ahmed K, Mc Hugh TJ, Mc Hugh SM, Kavanagh E. : *Appendicitis in de Garengot's hernia presented as a non tender inguinal mass: case report & review of literatures: case reports in surgery*, Hindawi publishing corporation 2014.

(4) Ramsing Jason, Ali Ahmed, Cameron Caroline, Al-Ani Ahmed

De Garengot,s hernia: diagnosis and surgical management of a rare type of Femoral hernia, *J. Surg. Case reports* 2014.

(5) A. Michalinos, D. Moris, S. Vernadakis " *Amyand's hernia: a review*" *The American journal of surgery*. Vol.207, no.6 pp989995, 2014.

(6) Sharma H, Gupta A, Shekhawat NS : *Amyand's hernia: a report of 18 consecutive patient's over a 15 years period*. *Journal of Hernia*,vol. 11, no. 1, 2007; 11:31-35.

(7) Ivashchuk Galyna et al. *Amyand's hernia : a review*, *Med. Sci. Monit.* 2014; 20: 140-6.

(8) P. Priego, E. Lobo, I. Moreno " *Acute appendicitis in an incarcerated crural hernia: analysis of our experience*" *Spanish journal for the digestive system diseases*, vol.97, no.10,pp 707715.

(9) A.Gurer, M.Ozdogan, N.Ozlem, A.Yildirim, H.Kulacoglu " *uncommon content in groin hernia sac*" *journal of Hernia*, vol.10, no.2 pp 152-155, 2006.

(10) J.Fernando and S.Leelaranta " *Amyand's hernia*" *the Ceylon medical journal*, vol.47, no.2, article no.71, 2002.

(11) L.J.Ceulemans, N.P.Deferm, T.Splessens " *Amyand's hernia*" *Belgian journal of radiology*, vol.97,no.3,pp.146-147,2014.

(12) J.E.Loanoff and M.D.Basson " *Amyand's hernia : a classification to improve management*" *journal of Hernia*,vol.12, no.3, pp 325-326,2008.

(13) Losanoff JE, Basson MD. *Amyand hernia: what lies beneath a proposed classification scheme to determine management*. *Am. Sur.* 2007; 73: 1288-90.

(14) Luchs JS, Halpren D, Katz DS, *Amyand's hernia: prospective CT diagnosis*. *Journal of. Comp. Ass. Tomography* 2000; 24(6) : 884-6.

(15) D'Alia C, Lo Schiavo MG, Tonante A : *Amyand's hernia : case report & review of the literature*. *Journal of Hernia* 2003, 7(2): 89-91.

(16) Ballas K, Kontoulis T, Skouras C : *unusual findings in inguinal hernia surgery : report of six rare cases*. *Hippokratia* 2009,13(3): 169-171.

[17] Milanchi S, Allins AD: *Amyand's hernia: history, imaging, and management*. *journal of Hernia* 2008, 12(3):321-322.

(17) Samani RS et al. *Amyand'd hernia: an extremely rare condition of inguinal hernia accompanied with acute appendicitis*. *Ann.colorectal Res* 2014;2(1) : - 17748.

(18) Nicola SM. Et al. *amyand's hernia : presentation of one case and review of literature*. *Journal of surgery* 2007; 59(2) : 142-4.

- (19) Agirre et al. amyand's hernia (type 2 Losanoff) preoperative diagnosis and treatment with biological mesh prosthesis. Hispanoamerican journal of Hernia 2014; 2(4):169-72.
- (20) Singal R, Gupta S. " Amyand's hernia" pathophysiology, role of investigations and treatment. A J Chin. Med. 2011; 6(4).
- (21) E. kose, A. Sisik, M. Hasbahceci: Mesh inguinal hernia repair and appendectomy in the treatment of

- Amyand's hernia with non inflamed appendices- jan. 2017, Hindawi publishing corporation , Article ID 7696385.
- (22) Pssaras et al. Amyand's hernia- a vermiform appendix presenting in an inguinal hernia : a case series, Journal of medical case reports 2011,5:463.

فتق " أمياند" المحتوي على زائده دودية غير ملتهبه, علاج ثلاث حالات مع مراجعة البحوث السابقه

د.نبيل عصام نعيم

المقدمه:

فتق "أمياند" هو الفتق المغبني في حالة وجود الزائده الدودية من ضمن محتوياته سواء كانت الزائده ملتهبه أو غير ملتهبه, وتحصل هذه الحاله بواقع 1% من حالات الفتق المغبني.

عرض الحالات:

أجريت هذه الدراسه عبر مراجعة (402) حاله من عمليات الفتق المغبني أجريت في مستشفى الشهيد أحمد أسماعيل – السليمانيه - جمهورية العراق في الفتره من أبريل 2013 الى أبريل 2018 من جميع هذه الحالات وجدت فقط (3) حالات من فتق "أمياند" جميعها احتوت على زائده دودية غير ملتهبه, تم اصلاح الفتق للحالات الثلاثه عن طريق وضع شبكة (البرولين) بدون إجراء عملية رفع الزائده الدودية.

الاستنتاج:

فتق "أمياند" هي حاله نادره تمثل تحديا من ناحية اتخاذ القرار المتعلق بطريقة العلاج لكونه يرتكز على عوامل متعدده. نجد انه من المهم ان تكون للجراح معلومات كافيه عن انواع هذا الفتق وطرقه العلاجيه المتعدده. مفتاح الكلمات: فتق أمياند, الزائده الدودية, اصلاح الفتق باستخدام الشبكة الصناعيه