

## Large functioning Childhood adrenocortical carcinoma (Case report)

Jinan A. Jabbar\* MBChB ,DMRD  
Qusai A. Fahad\*\* MBChB ,DMRD,FICMS

### Summary:

We describe a large functioning non metastasizing ACC in 8 years old boy who presented with a history of precocious puberty noticed by his parents since 3 months .Ultrasound of the abdomen showed a large well defined right suprarenal mass with calcification and necrosis . MRI showed the mass to be hypointense to liver on T1 and hyperintense to liver on T2, and dynamic CT scan revealed a large heterogenous enhancing right suprarenal mass with calcification and necrosis , clear chest .Histopathology done after surgical removal reveal adrenocortical carcinoma,so we recommend to do an abdominal ultrasound to any child with precocious puberty because it is easy,cheap and non invasive , if any suprarenal mass found it should be further characterized by MRI and dynamic conontrast enhanced CT to determine its respectability

**Keywords:** paediatric adrenocortical tumor, functioning adrenocortical carcinoma.

*Fac Med Baghdad*  
2013; Vol.55, No. 4  
Received: Mar., 2013  
Accepted June. 2013

### Introduction:

Adrenocortical carcinoma (ACC) is a rare malignancy ,especially in children .The overall incidence is approximately 2 cases per million per year .(1) In children , the incidence is 0.3 cases per million per year ,except in southern Brazil where the incidence is 3.4-4.2 cases per million per year .(1) At presentation , most children shows signs and symptoms of virilization ,which may be accompanied by manifestation of the hypersecretion of the adrenal cortical hormones. Fewer than 10%of patient with ACT show no endocrine syndrome at presentation ; these are often older children and adolescent . The extent of disease is best evaluated by computed tomography or MRI.(2)

In a majority of cases ,the tumor has either invaded adjacent organ or already metastasized to distant organ at the time of initial diagnosis .in most of the cases , it is mistaken for neuroblastoma which is the commonest intra-abdominal childhood tumor.(3)

The tumor has has bimodal age distribution ,presenting in children under 6 years ,and in adults 30-40 years old.(4) Functioning ACC usually draws clinical attention for many hormone syndromes.virilization,cushing 's syndrom,cons syndromand feminization. (1)

Histological features are used to classify the tumors as adenoma or carcinomas ;however,the distinction between these subtypes is often difficult .The extent of disease is best evaluated by computed tomography or MRI ,the role of PET / CT has not been defined .(2).Cure of ACT requires complete tumor resection(2).

### Case report:

An 8-years-old boy noticed by his parents to have precocious puberty of 3 months duration ,there was no relevant past history of abdominal pain or distension, and there was no significant family history of cancer.physical examination

revealed soft abdomen ,no palpable mass , external genitalia showed enlarged penis and testis with growing of pubic hair , Blood pressure was 140/90.

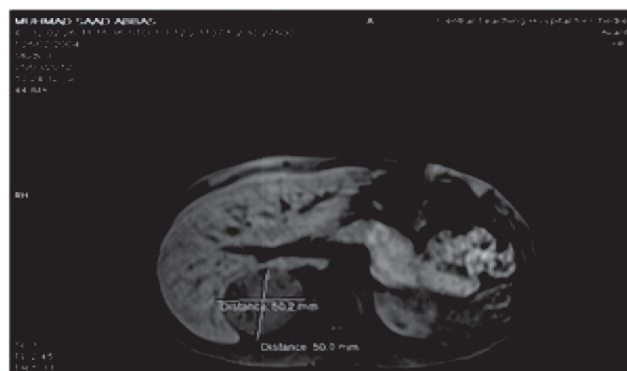### Investigation:

Xray: for wrist and elbow reveal accelerated bone age which was 12 years

Ultrasonography of abdomen revealed a large right suprarenal mass of about 5x4.9x4.7 cm with calcification and necrosis ,the mass was well defined ,IVC showing normal course and flow ,not displaced or encased and no focal lesion was seen in the liver

MRI : revealed a well defined right suprarenal mass that measure 5x4.9x4.9cm ,hypointense on T1, hyperintense on T2 with areas of signal void ,intact fat planes between the mass and kidney and liver .

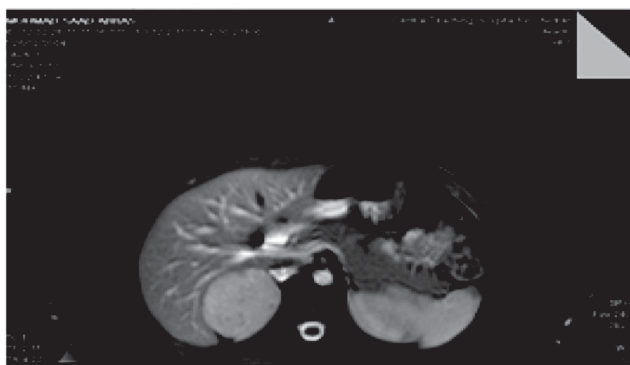
Contrast dynamic enhanced CT scan of the abdomen showing heterogenous enhancing suprarenal lesion with area of necrosis, multiplanar coronal reformat showed that the mass was well defined with intact fat planes. No focal lesion observed in liver and chest.



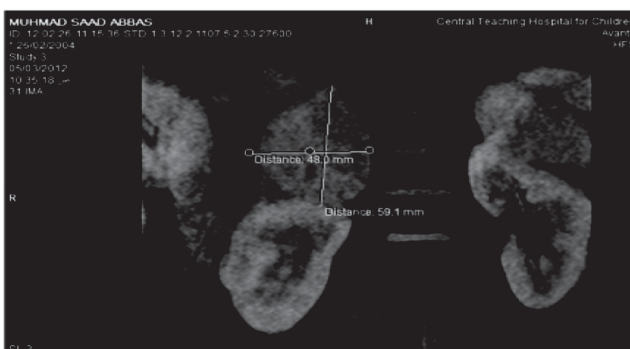
**Fig1:** Axial T1 :well defined hypointense right suprarenal mass

\*The national center for early detection of cancer, Medical city.

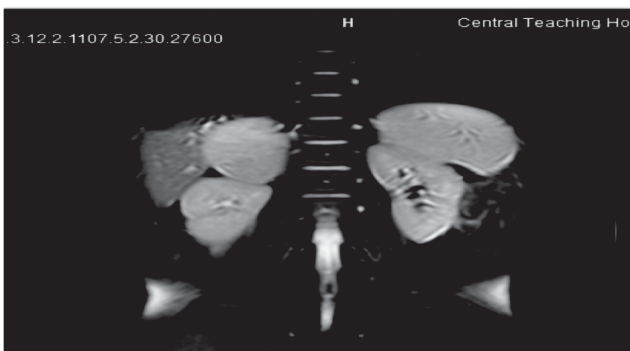
\*\* Baghdad Teaching hospital, Medical city.



**Fig2:Axial T2 :well defined hyperintense right suprarenal mass**



**Fig 3 :coronal T1 :well defined hypointense right suprarenal mass**



**Fig4:coronal T2 :well defined hyperintense right suprarenal mass.**

The tumor was removed totally by surgery ,pathology report was : macroscopically(gross) the section showed single piece of tissue measure 5x5x 4.5 cm ,soft yellow cut section with focus of hemorrhage. Microscopically the section showed: malignant tumor composed of solid sheets of atypical dense compact eosinophilic cytoplasm ,some cells have intracellular inclusion , mitosis ,capsular invasion ,focal clear cell compound, broad bands .The histologic picture (when collecting these features together ) is consistant with adrenocortical carcinoma.

Chromogranin immunostatin was negative.

To be differentiated from adenoma, the adenomas are surrounded by thin or well-developed capsules ,and most weigh less than 30 gm. Microscopically ,they are composed

of of mixturers of lipid-rich and lipid-poor cortical cells with little variation in cell and nuclear size. (3)

Laboratory investigations: reveal elevated plasma cortisol, and elevated serum androstenedione level.

#### **Discussion and review of literatures:**

ACC is an extremely rare tumor .In children,90% of the adrenal tumors are neuroblastoma (adrenal medulla).Tumors arising from adrenal cortex are rare .Among them,ACC is most common and it accounts for only 6% of adrenal tumors. Adrenal tumors in children can be associated with hemihypertrophy and Beckwith - Widemann syndrome. (4)

ACC are classified as functional and nonfunctional based on the hormonal syndroms they produce. Functional tumors are common and detected earlier than nonfunctioning tumor due to the production of hormones and associated clinical signs as well as symptoms. (5), as in our case.

Because pediatric adrenocortical tumors are almost universally functional, they cause endocrine disturbances, and a diagnosis is usually made 5 to 8 months after the first signs and symptoms emerge. (6) Virilization (pubic hair, accelerated growth, enlarged penis, clitoromegaly, hirsutism, and acne) due to excess of androgen secretion is seen, alone or in combination with hypercortisolism, in more than 80% of patient (6)

CT findings that increase the index of suspicion for adrenocortical carcinoma include the following:

- Large mass (>4 cm)
- Central necrosis or hemorrhage
- Heterogeneous enhancement
- Invasion into adjacent structures
- Venous extension into the renal vein or inferior vena cava .(7)

In our case the mass was >4cm. area of necrosis ,and heterogenously enhanced.

MRI often demonstrates a large mass with lower signal intensity than the liver on T1-weighted images and higher signal intensity than the liver on T2-weighted images. Often, the tumor demonstrates heterogeneously hyperintensity on T1- and T2-weighted images, due to the central necrosis and hemorrhage. Because the mass usually does not contain any significant intracellular lipid, it will not lose signal on out-of-phase imaging.MRI is advantageous for evaluating tumors, since its depiction of vascular invasion and extension into surrounding structures often is superior to that of CT. Additionally, the most cephalad extension of the tumor must be evaluated so that the surgeon can obtain vascular control of the tumor. This can be achieved with CT but often is easier with MRI. (7)

#### **Conclusion:**

Based on review of literature we recommend to do an abdominal ultrasound to any child with precocious puberty because it is easy and non invasive , if any suprarenal mass found it should be further characterized by MRI and dynamic conontrast enhanced CT to determine its respectability .

**References:**

1. *Viral V. Patel, Diva S. Shah, Chandra R. Raychaudhari, and Keyuri B. Patel giant non functioning adrenocortical carcinoma: Arare childhood tumor Indian J Med Paediatr Oncol. 2010 Apr-Jun; 31(2): 65–68.  
doi: 10.4103/0971-5851.71659*
2. *. Sandrini R, Ribeiro RC, DeLacerda L. Childhood adrenocortical tumors. J Clin Endocrinol Metab. 1997;82:2027–31. [PubMed]*
3. *Cotran S.Ramzi,M.D,Kumar Vinay,M.D,Robins L.Stanely,M.D,Schoen J.Fredrick,M.D.,Ph.D.Robbins :Pathologic basis of disease 5<sup>th</sup> edition .P; 1153*
4. *Agrons GA, Lonergan GJ, Dickey GE, Perez-Monte JE. Adrenocortical neoplasms in children: Radiologic-pathologic correlation. Radiographics. 1999;19:989–1008. [PubMed]*
5. *Kanmaz T, Demirbilek S, Ozardali I, Safali M, Guran S, Yucesan S. Nonfunctioning adrenocortical carcinoma in a child. Pediatr Pathol Mol Med. 2003; 22:405–10. [PubMed]*
6. *Cheungpasitporn W, Horne JM, Howarth CB. adrenocortical carcinoma a presenting as varicocele and renal vein thrombosis: A case report. Journal of medical case reports 2011 5: 337 doi : 10.1186/1752-1947-5-337*
7. *Robert L Cirillo Jr, MD, MBA; Chief Editor: Eugene C Lin, MD :adrenal carcinoma imaging Updated: May 25, 2011.*