

## CA19-9 and CK immunohistochemical expression in pancreatic and ampulla of vater carcinomas (A clinicopathological study)

Sudad A. Khalf\*

MSc

Kifah H. Abdulghafour\*\*

PhD

### Summary:

**Background:** Pancreatic carcinoma is one the most lethal malignancies and the Prognosis for patients with locally advanced or metastatic disease is poor. The 5-year survival rate is about 4%, which is the lowest of any cancer and median survival is 6 months. The high mortality rate is largely due to the typically advanced stage of the cancer at the time of diagnosis and treatment. Resection is the only current treatment resulting in cure for pancreatic carcinoma. However, due to the initiation and progression of this cancer without symptoms, only about 10% to 15% of patients present with localized disease amenable to potentially curative resection. Chemotherapy increases survival and up to date, the use of palliative chemotherapy is increasing due to the availability of more drugs and a wider range of indications. CA 19-9 is the marker most widely used clinically as elevated in approximately 75% of patients with pancreatic carcinoma with reported sensitivities ranging from 70% to 90% and specificities ranging from 68% to 91% with great support of CK marker in excluding or confirm diagnosis.

**Objectives:** Evaluation of CA19-9 and CK HMW markers expression in pancreatic and ampulla of vater carcinoma immunohistochemically & to correlate the immunohistochemical expression of CA19-9 and CK HMW markers with carcinoma location.

**Material and method:-** 36 samples of whipple operations and partial pancreatectomy whom already diagnosed as pancreatic carcinoma from 2009-2013 whom visit and admitted to GIT hospital in Baghdad medical city. A tissue sample block from mass that already processed and identified by dissection report from data base of histopathology Lab was collected for staining by immunohistochemical method with C19.9 and CK marker.

**Results:-** 36 patients - 24 male and 12 females, Mean age (45+2.02) range (28-65) year with Male: Female ratio is (2:1) As differentiation of malignant cell in this study it was higher level with grade II (60%) For TNM classification the result was dominantly staging as T3. IHC staining of CK19-9:-in present study we have 75% of patient samples with positive result. Present study show that 4 patient's samples of total 6 positive CK/IHC staining was pancreatic carcinoma while only 2 of total positive was ampulla carcinoma.

**Conclusion:-** CA19-9 is pancreatic tumor associated marker but cannot used for screening and association with clinical findings. Meanwhile CK tissue immunolabing mostly helpful in diagnosis of ampullary and pancreatic carcinoma and CK immunohistochemical staining can be used as exclusion aid in diagnosis of pancreatic carcinoma.

**Keywords:** whipple', pancreatic carcinoma, ampullary carcinoma CA19-9, CK.

Fac Med Baghdad  
2014; Vol.56, No3  
Received: March, 2014  
Accepted May, 2014

### Introduction:

Pancreatic carcinoma is a highly lethal disease, which is usually diagnosed in an advanced stage for which there are little or no effective therapies.(1)

Pancreatic cancer has been ranged among first five death causes in the western world, accurate characterization and staging have become increasingly important for patients to avail themselves of the increasing advances in treatment options.(2)

One key to effective cancer treatment is early detection. In many cancers, including those of the pancreas, current methods

for early detection are inadequate.(3).

An accurate, minimally invasive test that could be routinely employed to screen for pancreatic carcinoma would possibly increase detection at a stage amenable to resection and thus improve survival rates.(4)

Preoperative radiographic findings and (CA 19-9) which frequently elevated in patients with pancreatic carcinoma is one of the few markers that can aid in diagnosis.(5)

When the tumor is small and confined to the Ampulla, both the endoscopic and radiographic appearances may be normal, CT and ultrasound usually show dilation of the common bile duct or pancreatic duct, but the mass itself may be unapparent. (6) Although no histochemical or immunohistochemical marker

\*Dept. of pathology, Alkadhemia Teaching Hopsital

\*\* Corresponding Authedr: kifahalani@yahoo.com

Dept. of pathology, College of Medicine, Baghdad University.

is able to unequivocally distinguish pancreatic from extra pancreatic carcinoma, some markers are useful in separating ductal adenocarcinoma of the pancreas from non duct-type tumors or other gastrointestinal carcinomas.

Immunohistochemically, most ductal adenocarcinomas express MUC1, MUC3 and MUC5/6 (but not MUC2) CA 19-9, Du-Pan 2, Span-1, CA 125 and TAG72.

The expression patterns of CA 19-9, Du-Pan2, Span-1, CA 125 and TAG 72 are largely comparable in their immunoreactivity and specificity. The sensitivity of evaluation of CA19-9 as single tumor marker determination in diagnosis of pancreatic tumor is 70.4%. CA19-9 is a carbohydrate antigen recognized by a monoclonal antibody produced by a hybridoma raised against a human colonic carcinoma cell line. It has been characterized as a monosialoganglioside related to the Lewis A blood group antigen. (7)

Normal pancreatic and biliary ductal cells and pancreatic centroacinar cells express the cytokeratins (CK) 7, 8, 18, 19 and occasionally 4. Acinar cells contain only CK 8 and 18, and islet cells 8, 18 and occasionally 19. Ductal adenocarcinomas express the same set of cytokeratins as the normal duct epithelium i.e. CK 7, 8, 18 and 19. More than 50% of the carcinomas also express CK 4 but are usually negative for CK 20. As the usual keratin patterns of non-duct-type pancreatic neoplasm (i.e. acinar carcinomas and endocrine tumors, CK 8, 18 and 19) and gut carcinomas (i.e. CK 8, 18, 19 and 20) differ from that of ductal carcinoma, it is possible to distinguish these tumors on the basis of their CK profile. (7)

Considerable number of cases are operable at diagnosis and for carcinomas arising in the ampulla of Vater, prognosis after surgical intervention is therefore better. (8)

Many tumor markers have been developed in the past two decades as immunohistochemical aids to the diagnosis of carcinoma and some of these tumor markers are very organ specific. (9)

#### Material and methods:

In this study a 36 samples of whipple's operations and partial pancreatectomy whom already diagnosed as pancreatic carcinoma from 2009-2013 from the GIT hospital in Baghdad medical city.

A tissue sample block from mass that already processed and identified by dissection report from data base of histopathology department was collected for staining by immunohistochemical method with C19.9 and CK marker.

Each single block was selected so that the section to be from the pancreatic tumor mass and confirmed by examination of the basic slide with H&E stains and supported by report of specialized histopathologist. Immunohistochemical staining of anti-CA 19.9 showed Brown staining of cytoplasm and/or membranous immunolabelling were expressed positive result when cover one third or more of the tumor surface area.

While negative result when no staining show or less than one third of tumor surface area.

Immunohistochemical staining of anti-CK HMW Showed

Brown staining of cytoplasm immunolabelling of 20% or more of malignant cells in tumor surface were expressed positive result While negative result when no staining show or less than 20%.

Two software programs were used to present, describe and analyze data included in the present study. These were SPSS (Statistical Package for Social Science; version 16) and Microsoft Office Excel 2007. Numeric variables were presented as mean, standard deviation and range. Nominal variables were expressed as frequency (number) and percentage out of total. Pearson's Chi-Square and Fisher exact tests were used to evaluate nominal variable frequency difference between groups, whenever possible. The level of (<0.05) was considered significant for interpretation of P values.

#### Results:

Table 1 showed the anatomical site of lesion we divide our study group in to preamullary(smaller group) which present 8% and ampullary (38%) and pancreatic(larger group) which present more than 52% of study samples. For the TNM classification of pancreatic carcinoma staging we found more than 47% of stage presentation was in patients with T3 while less than 6% was presented for both T1 and T4 as below in table 2. Table 3 showed the grading of the tumors, 22 cases was grade II the equal to 61% of total and only 5 cases was grade III (13%) and in between results 25% of cases show grade I (figure 1)

Table 4 & 5 showed the correlation between grading and IHC staining of CA19-9 and CK HMW, For the grade of differentiation we have group of 22 cases presented as grade II which shows 18 cases of positive result CA19-9/IHC and 14 cases with negative result CK HMW/IHC staining.

**Table 1 the anatomical site of carcinoma**

Site	Frequency	Percent
Periampulla	3	8.33
Ampulla	14	38.89
Pancreas	19	52.78
<b>Total</b>	<b>36</b>	<b>100.00</b>

**Table 2: the TNM Stage of carcinomas**

Stage	Frequency	Percent
T1N0	2	5.56
T2N0	8	22.22
T2N1	2	5.56
T3N0	17	47.22
T3N1	3	8.33
T4N0	2	5.56
T4N1	1	2.78
T4N1MX	1	2.78
<b>Total</b>	<b>36</b>	<b>100.00</b>

Table 3:-the grade of differentiation of carcinoma

Grade	Frequency	Percent
I	9	25.00
II	22	61.11
III	5	13.89
Total	36	100.00

Table 4: show grade of differentiation in study cases in relation to CA19-9 /IHC staining

grading	CA19-9 /IHC staining		Total
	Negative	Positive	
I	2	7	9
II	4	18	22
III	1	4	5
TOTAL	7	29	36

Table 5 :-show grade of differentiation in study cases in relation to CK /IHC staining

Grading	CK /IHC staining		Total
	Negative	Positive	
I	7	2	9
II	14	8	22
III	3	2	5
TOTAL	22	12	36

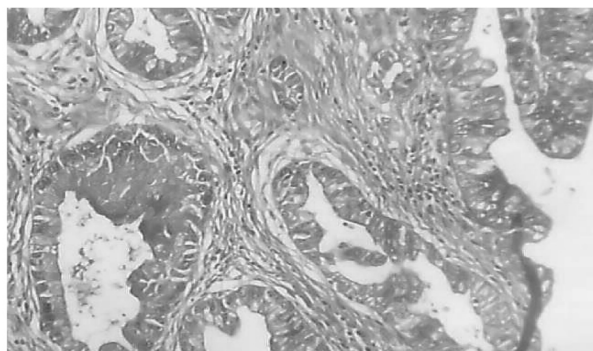


Figure 1: shows pancreatic adenocarcinoma , moderately differentiated X100

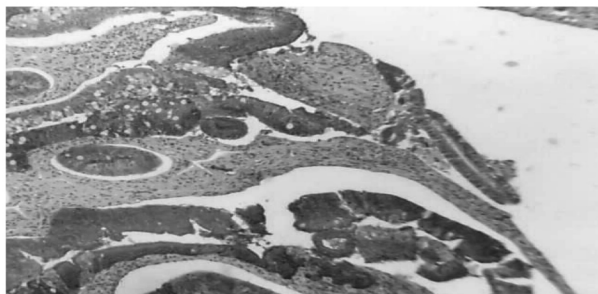

Figure 2: shows pancreatic adenocarcinoma glands positively stained with IHC method CA19-9/ X100

**Discussion:**

In this study the Mean age (45 year) which totally fit the study results of Senthilkumar et.al.(9)from India but is lower than results of Kim et al. .(10)And this can be explained by the causes of pancreatic carcinoma itself as it is more common in elderly people in western society and both studies done on clinical data from patients with limited age group. While present study samples were collected from actual findings in specialized center. As differentiation of malignant cell in this study it was higher level with grade II (60%) which totally fit the results of J. L. Humphris et.al. (11) and C Ziske et.al. (12) and also very close to result of Sabrina et.al. (13) but lettel higher than result of YC Kim et al. (14) and Chiang et al. (15) and J. Rudnicki et al. (16) as they used bigger study sample and more restriction parameter to choose patients i.e. in all those study the major differentiation was grade II just like present study but the percentage defers with some of them, while with results of Shuichi Fujioka et.al. (17)was higher than this study result but grade II also. For TNM classification the result was dominantly staging as T3 which differ from Sabrina et.al. and L. Humphris et.al. and Dorandeu et al. .(18) as most cases with T2 for the all 3 studies sample and also differs from Jiahua Zhou et al. (19) which was mostly as T4 and that difference most probably to late presentation of Iraqi patients and more advanced facilities for earlier diagnosis in those studies. IHC staining of CK:- our study show 30% of patients samples was positive and higher than the results of one study group in Wang et al (20) and similar to one group in Tot et al (21) as they both used more than one subtype of CK marker and lower Threshold cut-point required for positive stain and more than one group of study. While both Alexander et al (22) and Neal et al (23) study groups was higher positive results than present study as they used bigger study samples and more filtered cases and more than one CK marker subgroup. IHC staining of CK19-9:-in present study we have 75% of patient samples with positive result which totally fit the result of A Dorandeu et al. although he used double bigger study group and filtered group of samples as carcinoma of ampulla. But this study result was higher than S Pavai et.al. (24) for malignancy group including pancreatic cases as he used parameter for tissue and serum samples with higher study samples. Present study show that 4 patients samples of total 6 positive CK/IHC staining was pancreatic carcinoma while only 2 of total positive was ampulla carcinoma which is similar to results of Neal et al. although the rate between 2 types may defer since he used many subtypes of CK and with multiple staining density group. While for C19-9/IHC staining there was very small variation in positive result of pancreatic and ampullary carcinoma and the same rate of negative result but unfortunately we could not found a study with same working parameter to compare with.

**Author contributor :**

Dr Kifah Hamdan: supervisor, review of the results and interpretation of data.

Dr Sudad Khalaf: Msc student, collection of cases, practical word, statistical analysis.

**References :**

1. Chenwei Li, David G. Heidt, Piero Dalerba, et al., Identification of Pancreatic Cancer Stem Cells. *Cancer Res.* 2007;67:1030-1037).
2. Jasna Trifunovic, Ljubomir Muzikravić, Mladen Prvulović, Svetlana Salma, Borislava Nikolin, Biljana Kukić. Evaluation of imaging techniques and CA 19-9 in differential diagnosis of carcinoma and other focal lesions of pancreas. *Arch. Oncol.* 2004;12(2):104.
3. W. Zhou, L. J. Sokoll, D. J. Bruzek, et al. Identifying markers for pancreatic cancer by gene expression, *Cancer Epidemiology, Biomarkers and Prevention* 1998;7:109-112.
4. Sabrina C. Wentz, Zhi-Guo Zhao, Yu Shyr, Chan-Juan Shi, Nipun B. Merchant, Kay Washington, Fen Xia, A. Bapsi Chakravarthy. Lymph node ratio and preoperative CA 19-9 levels predict overall survival and recurrence-free survival in patients with resected pancreatic adenocarcinoma. *World J. Gastrointest Oncol* 2012 October 15; 4(10): 207-215.
5. Shishir K. Maithel, Stephen Maloney, Corrine Winston, Mithat Goñen, Michael I. D'Angelica, Ronald P. DeMatteo, William R. Jarnagin, Murray F. Brennan and Peter J. Allen. Preoperative CA 19-9 and the Yield of Staging Laparoscopy in Patients with Radiographically Resectable Pancreatic Adenocarcinoma. *Annals of Surgical Oncology* 2008 (12):3512-3520.
6. Wagner PL, Chen YT, Yantiss RK. Immunohistochemical and molecular features of sporadic and FAP-associated duodenal adenomas of the ampullary and nonampullary mucosa. *Am J Surg Pathol* 2008; 32:1388-1395.
7. A.M. Attallah, N.A. Al-ghawalby, A.A.F. Abdel Aziz, E.A. Elsayed, A.A. tabll and A.M. Elwaseef. clinical value of serum CEA, CA19-9, CA242 and AFP in diagnosis gastrointestinal tract cancers. *International journal of cancer research* 2006, 2(1); 50-56. [IVSL].
8. Takashima M., Ueki T., Nagai E., Yao T., Yamaguchi K., Tanaka M., Tsuneyoshi M. Carcinoma of the ampulla of Vater associated with or without adenoma: a clinicopathologic analysis of 198 cases with reference to p53 and Ki-67 immunohistochemical expression. *Mod Pathol* 2000; 13:1300-1307.
9. Sun Hoo Park, Yong Il Kim, Yong Hyun Park, Sun Whe Kim, Ki Whan Kim, Yong Tae Kim, Woo Ho Kim, Clinicopathologic Correlation of p53 Protein Overexpression in Adenoma and Carcinoma of the Ampulla of Vater, *World J. Surg.* 2000, 24, 54-59).
10. Young Choon Kim, Hong Joo Kim, Jung Ho Park, Dong Il Park, Yong Kyun Cho, Chong Il Sohn, Woo Kyu Jeon, ByungIk Kim and Jun Ho Shin ( Can preoperative CA19-9 and CEA levels predict the resectability of patients with pancreatic adenocarcinoma?) *Journal of Gastroenterology and Hepatology* 24 (2009) p.1869-1875.
11. Jiahua Zhou, Liang Hu, Zeqian Yu, Jie Zheng, Detong Yang, Michael Bouvet and Robert M. Hoffman (Marker Expression in Circulating Cancer Cells of Pancreatic Cancer Patients) *Journal of Surgical Research* (2011) 171, 631-636.
12. C. Ziske, C. Schlie, M Gorschlu, A. Glasmacher, U. Mey, J. Strehl, T. Sauerbruch and IGH Schmidt-Wolf. Prognostic value of CA 19-9 levels in patients with inoperable adenocarcinoma of the pancreas treated with gemcitabine. *British Journal of Cancer* (2003) 89, 1413 - 1417.
13. Sabrina C Wentz, Zhi-Guo Zhao, Yu Shyr, Chan-Juan Shi, Nipun B Merchant, Kay Washington, Fen Xia, A Bapsi Chakravarthy. Lymph node ratio and preoperative CA 19-9 levels predict overall survival and recurrence-free survival in patients with resected pancreatic adenocarcinoma. *World J Gastrointest Oncol* 2012 October 15; 4(10): 207-215.
14. Young Choon Kim, Hong Joo Kim, Jung Ho Park, Dong Il Park, Yong Kyun Cho, Chong Il Sohn, Woo Kyu Jeon, ByungIk Kim and Jun Ho Shin . Can preoperative CA19-9 and CEA levels predict the resectability of patients with pancreatic adenocarcinoma?. *Journal of Gastroenterology and Hepatology* 24 (2009) p.1869-1875.
15. Kun-Chun Chiang<sup>1,2</sup>, Chun-Nan Yeh<sup>3,5\*</sup>, Shir-Hwa Ueng<sup>4</sup>, Jun-Te Hsu<sup>3</sup>, Ta-Sen Yeh<sup>3</sup>, Yi-Yin Jan<sup>3</sup>, Tsann-Long Hwang<sup>3</sup> and Miin-Fu Chen<sup>3</sup> (Clinicodemographic aspect of resectable pancreatic cancer and prognostic factors for resectable cancer) *World Journal of Surgical Oncology* 2012, 10:77 p.2-9.
16. J. Rudnicki<sup>1</sup>, A.K. Agrawal, Z. Grzebieniak, P. ukrowski, D. Zyoeko, M. Jelen, W. Kielan, M. Sebastian, J. Sónina, G. Marek, Ł. Duda-Barcik. Prognostic value of CA 19-9 level in resectable pancreatic Adenocarcinoma. *FOLIA HISTOCHEMICA ET CYTOBIOLOGICA* Vol. 48, No. 2, 2010 pp. 249-261.
17. Shuichi Fujioka, Takeyuki Misawa, Tomoyoshi Okamoto, Takesh Gocho, Yasuro Futagawa, Yuichi Ishida, and Katsuhiko Yanaga. Preoperative serum carcinoembryonic antigen and carbohydrate antigen 19-9 levels for the evaluation of curability and respectability in patients with pancreatic adenocarcinoma *J Hepatobiliary Pancreat Surg* (2007) 14:539-544.
18. A. Dorandeu, J-L Raoul, F Siriser, N Leclercq-Rioux, M Gosselin, E D Martin, M-P Ramee, B Launois (Carcinoma of the ampulla of Vater: prognostic factors after curative surgery: a series of 45 cases) *Gut* 1997; 40: 350-355.
19. Jiahua Zhou, Liang Hu, Zeqian Yu, Jie Zheng, Detong Yang, Michael Bouvet and Robert M. Hoffman .Marker Expression

*in Circulating Cancer Cells of Pancreatic Cancer Patients. Journal of Surgical Research (2011) 171, 631–636.*

20. Wang NP, Zee S, Zarbo RJ, et al. Coordinate expression of cytokeratins 7 and 20 defines unique subsets of carcinomas. *ApplImmunohistochem.* 1995;3:99-107.

21. Tot T. Adenocarcinomas metastatic to the liver: the value of cytokeratins 20 and 7 in the search for unknown primary tumors. *Cancer.* 1999;85:171-177

22. Alexander J, Krishnamurthy S, Kovacs D, et al. Cytokeratin profile of extrahepaticpancreaticobiliary epithelia and their carcinomas. *ApplImmunohistochem.* 1997 ;5:216-222.

23. Neal S. Goldstein, MD, and DeepaBassi, M(Cytokeratins 7, 17, and 20 Reactivity in Pancreatic and Ampulla of Vater Adenocarcinomas )*Am J ClinPathol* 2001;115:695-702.

24. S Pawai, MD\*, S F Yap (The Clinical Significance of Elevated Levels of Serum CA 19•9) *Med J Malaysia*Vol 58 No 5 December 2003 P.668.