

# The role of Wilm's Tumor1 immunohistochemical marker in surface epithelial ovarian tumors

Muna I. AL Hafedh\*

Sahira A. Ali\*

Lubab F. Talal\*

MBChB

MBChB, PhD( Pathology)

FICMS-Pathology (Histopathology)

## Abstract:

**Background:** Wilms' tumor 1 is a tumor suppressor gene. The gene is located in chromosome 11p13. And its expression was found in many solid tumors (including ovarian tumor) and also expressed in hematologic malignancies, Recent studies found that WT1 to be involved in angiogenesis.

**Objectives:** To evaluate the expression of WT1 in surface epithelial ovarian tumor and study the possibility of using WT1 as replacement of both; ovarian tumor marker CA125 and an endothelial cell phenotypic marker CD34.

**Patients and methods:** This is a study of a retrospective (cross-sectional) of sixty cases with total abdominal hysterectomy and bilateral salpingo-oophorectomy collected from the department of Histopathology – Teaching Laboratories / Medical City Teaching Hospital, as well as Al alwya hospital and Al Habibia hospital in Baghdad during the period of study from December 2007 to December 2012. Thirty cases diagnosed as surface epithelial ovarian tumors and thirty cases of histologically normal ovarian tissue which were included as a control group. Formalin-fixed, paraffin-embedded ovarian tissue blocks from 60 cases were used. Three sections of 4 microns for each taken and stained with WT1, CD34, and CA125 immunohistochemical marker on positively charged slides.

**Results:** there was a significant correlation between expression of WT1 and histological types of surface epithelial ovarian tumor with a higher expression in serous tumors among other cancer types (P-value < 0.001). There was a significant positive correlation between the expression of WT1 and CA125 scores (p-value < 0.001). There was a significant correlation between WT1 microvessel density (MVD) expression and CD34- microvessel density (MVD) expression in ovarian tumors (P-value = 0.05). On the other hand, there were no significant correlations of WT1 with the age of cases (P-value = 0.9) and with the grade of ovarian tumors (P-value = 0.23).

**Conclusions:** The present study demonstrates high expression of WT1 in both tumor and endothelial cells in surface epithelial ovarian tumors, and it had dual usages in evaluation of both ovarian tumor cells and the vascular density. That was proved by demonstrating a significant correlation between WT1 and CA125 expression, and between WT1-MVD and CD34- MVD. There was no statistically significant association between WT1 expression and different tumor grades. There were significant differences in WT1 expression among different histological subtypes of primary ovarian carcinomas, with serous carcinoma as the most frequent type.

**Key words:** Ovarian tumor; WT1; CA125; CD34.

*Fac Med Baghdad*  
2015; Vol.57, No.2  
Received: July, 2014  
Accepted: Mar, 2015

## Introduction:

Ovarian cancer is the second leading cause of cancer-related death in women worldwide. Since most patients are diagnosed in advanced disease stages. In Iraq, ovarian tumors rank the 6th commonest cancer and constituted 3.81% according to Iraqi Cancer Board Registry in 2009. These tumors comprise several distinct histological types. The surface epithelial tumors account for 60% of all ovarian neoplasms. Its etiology is poorly understood. It's more common in nulliparous women, in those living in industrialized countries and epidemiological studies have shown a significant reduction in ovarian cancer in

women who have used oral contraceptive pills. Most cases of epithelial ovarian cancer are sporadic, occurring with no family history of the disease. Wilms' tumor 1 (WT1) is a transcription factor first found in Wilms' tumor of the kidney, where it acts as a tumor suppressor gene. The gene is located in chromosome 11p13. And WT1 was associated with cell proliferation in many solid tumors (malignant melanoma, breast cancer, gliomas, desmoplastic small round cell tumors, and epithelial ovarian tumors). And also found in hematologic malignancies (myeloid leukemia cells). Recent studies have reported correlations between WT1 and neovascularization in histogenesis, normal genitourinary development, cardiac malformation and tumor angiogenesis. WT-1 is a useful

\*Dept. of Pathology/ College of Medicine/ University of Baghdad.  
Email: dr.monaes@yahoo.com

marker for detection of ovarian tumor cells, and is also consistent with that of a recent study in 2008, which reported that "Endothelial WT-1 expression was detected in 95% of 113 tumors of different origin", including expression of WT1 in endothelial cells in human breast tumors. Li HJ., et al in 2009 assessed that WT-1 immunohistochemistry have dual usages in evaluation of the myoepithelial cells and micro-vessel density in breast cancer. As the human ovary is rich in blood vessels and WT-1 has been used as a biomarker for ovarian tumors. Together, these findings suggest that a single WT1 immunohistochemistry have dual usages in evaluation of both ovarian tumor cells and the vascular density. Single WT-1 immunohistochemistry can be used to assess both the tumor cells and micro-vascular density in ovarian tumors as Yi-Hsuan H. Et al in 2010 suggest that WT-1 is expressed in both tumor and endothelial cells in ovarian tumor. It is co-expressed with a well-defined ovarian tumor marker CA125, and also with an endothelial cell phenotypic marker CD34, in the same cells. Especially in serous tumor whereas in other surface epithelial tumors was with no benefit.

#### **Patients and Methods :**

This is a retrospective ( cross sectional ) study of ( 60 ) cases with total abdominal hysterectomy and bilateral salpingo – oophorectomy collected from department of Histopathology –Teaching Laboratories / Medical City Teaching Hospital , as well as Al alwya hospital and Al Habibia hospital in Baghdad , the period of study from December 2007 to December 2012. Thirty cases diagnosed as surface epithelial ovarian tumors and thirty cases of histologically normal ovarian tissue which were included as a control group. Formalin-fixed paraffin-embedded ovarian tissue blocks from 60 cases were used . Three section of 4micron for each taken and stained with WT1, CD34, and CA125 immunohistochemical marker on positively charged slides. All the clinicopathological parameters such as (age, gender, site of tumor and grade ) were obtained from histopathological reports available in labrotories of the Hospital mentioned above. Tumor grading was according to FIGO grading criteria. And For the thirty cases of surface epithelial ovarian tumor classified into different histological type according to WHO classification. The immunohistochemical procedure was carried out, at the Oncology Teaching Hospital and Forensic medical institute in accordance with the manufacturer's instructions with modifications to optimize the results. The primary antibody CD34 class 2 (DAKO Denmark) monoclonal mouse (QBEnd 10); diluted against 1:25mol/L Tris/Hcl was incubated with tissue sections for 30-60 min. And the Primary antibody CA125M11(DAKO Denmark) monoclonal mouse ; diluted against 1:20mol/L Tris/Hcl was incubated with tissue sections for 30-60 min. The (BioGenex, USA) detection kit, QD430-

Xake was used for antigen visualization. The primary antibody WT1 6F-H2 (DAKO Denmark), monoclonal mouse , ready to use.

The(Mouse specific HRP\DAB abcam ) detection kit Ab 64259. Paraffin sections of Fallopian tube, were run with each batch to serve as a positive control for WT1, CA125 and normal ovarian tissue as positive control for CD34.

#### **Results:**

WT1 was observed as brown precipitation in the nuclei of surface epithelial tumor cells. WT1 was scored, and graded on a 0 to 3 scale :0 (negative), 1 (weak), 2 (medium) and 3 (strong) ; While the extent of staining was scored as : 0 (0 % ) , 1 ( 1- 25 % ) , 2 (26-50% ) , 3 (51-75% ) and 4 (76-100% ) The sum of the intensity and extent score was used as the final staining score (0-7) for WT1. CD34 was observed red-brown colored precipitate at the specific cytoplasmic site and cell membrane of CD34 antigen. Estimation of microvessel density(Weidner's method): slides were first scanned at 100× magnification, and five areas of maximum microvessels density (MVD) called hot spots were identified at 200× magnification on each slide. In each of these hot spots, microvessels (capillaries and small venules) were counted at 400×. In each case, means of the hot spots were counted. CA125 was observed a brown colored in the cell membrane of surface epithelial tumor cells. Intensity of CA125 was graded on a 0 to 3 scale ( 0 for no staining , + for weak ; ++ for moderate; and +++ for strong ). The percentage of cells was scored as follows : 1 for (0–25%) ; 2 for ( 26–50%) ; 3 for (51–75%) ; and 4 for (76–100%). The values of the staining intensity and the percent of immunoreactive cells were multiplied to obtain a composite score ranging from 0 to 12.

Statistical Analysis: Spss version 20 was used for data entry and analysis. Tests used : One - Way – Anova test, tukey B post – hoc test , Kruskal – Wallis test where P- value  $\leq 0.05$  was significant. Spearman rho correlation test where P – value  $\leq 0.01$  was significant.

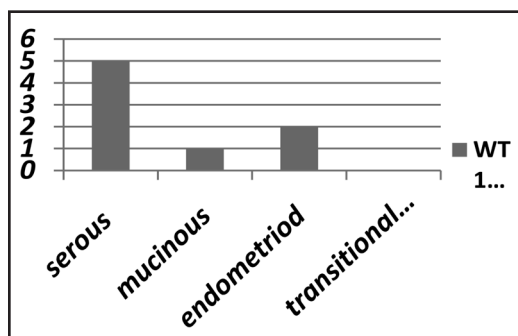
#### **Results:**

A total of sixty female patients ; thirty cases were diagnosed as surface epithelial tumors of the ovary , an additional 30 patients with normal ovary were taken as a control study group. The mean age of the patients with malignant ovarian tumor was (49 ±13.5 ) years , and for the control group was (49.8 ± SD 6.7 ) years.

The WT1 scores expression was highly significant in serous tumors than other cancer types. As shown in table (1) , figure (1) .

Table (1) : Distribution of WT1 scores among histological type of surface epithelial tumors.

surface epithelial tumor types	WT1 expression				p-value*
	Mean	Standard Deviation	Minimum	Maximum	
serous tumor	5	2	0	7	<0.001
mucinous cyst adenoma	1	2	0	3	
endometrioid adenocarcinoma	2	2	0	3	
transitional cell carcinoma	0	0	0	0	



Figure(1): correlation of WT1 expression by histological type

No significant statistical correlation found in distribution of WT1 expression scores among the tumor grades . ( p-value = 0.23) as seen in table (2)

Table ( 2 ) : Distribution of WT1 scores by tumor grades.

Tumor grade	WT1 expression			p-value*
	Count	Median	Range	
borderline	14	5	7	0.23
well differentiated	4	4	7	
moderately differentiated	6	3	5	
poorly differentiated	6	6	4	
<b>Total</b>			<b>30</b>	

\* Kruskal Wallis test

A positive correlation was found between expression scores of WT1 and CA125 markers (p-value < 0.001). as seen in figure (2)

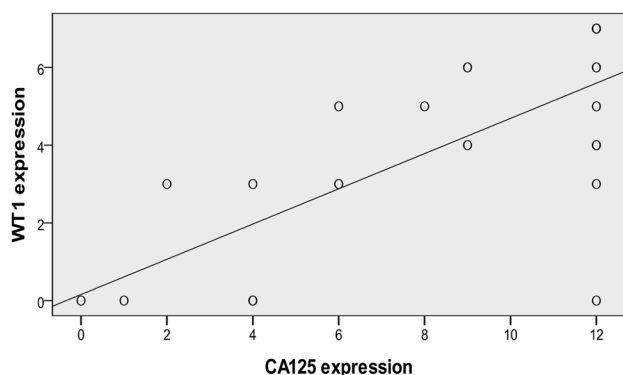


Figure (2): scatter plot and line between WT1 and CA125 expression scores

There was statistical significant positive correlation between WT1 microvessel density (MVD) and CD34 MVD (p-value = 0.05). as seen in figure (3).

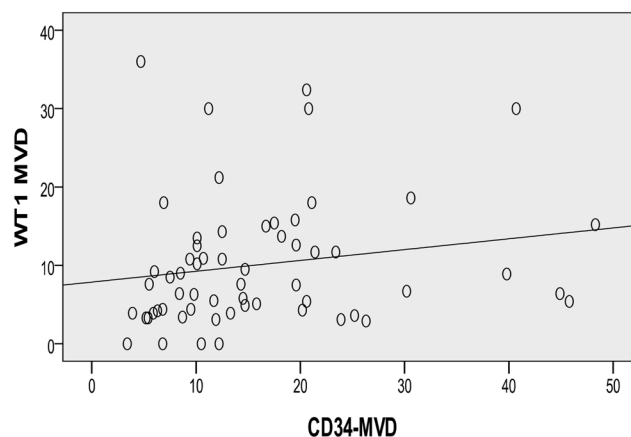


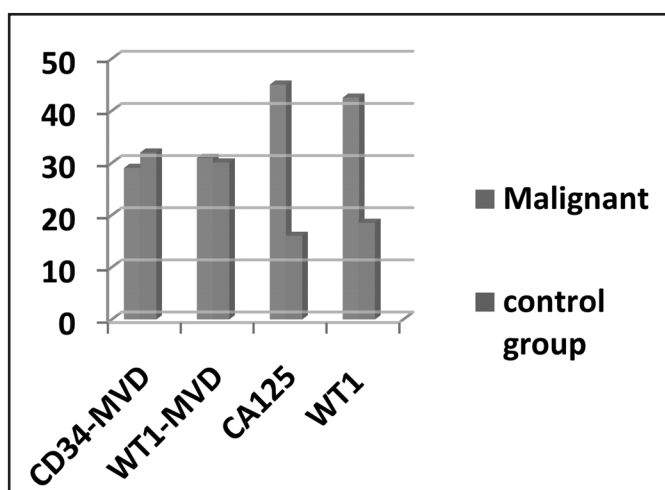
Figure (3): scatter plot and line of between WT1-MVD and CD34-MVD

Assessing the differences in distribution of immunomarker expressions between malignant cases and control group :

- There was no significant difference in CD34-MVD expression between malignant and control group cases. ( p-value =0.5).
- There was no significant difference in WT1-MVD expression between malignant and control group cases. ( p-value = 0.8)
- There was significant difference in CA125 expression between malignant and control group cases. ( p-value < 0.001)
- There was significant difference in WT1 expression between malignant and control group.( p-value < 0.001).as seen in table (3), figure (4).

Table ( 3 ) : WT1, CA125 and CD34 Immunomarkers expressions in malignant and control group cases.

	Cases	Mean	P-value*
CD34-MVD	malignant	29.03	0.5
	Control group	31.97	
WT1 MVD	malignant	30.93	0.8
	Control group	30.07	
CA125 expression	malignant	45.00	<0.001
	Control group	16.00	
WT1 expression	malignant	42.50	<0.001
	Control group	18.50	



Figure(4): Distribution of immunomarkers among studied cases

**Discussion:**

Ovarian cancer is second most commonly diagnosed gynecological malignancy after endometrial cancer. 20 In Iraq, it is the sixth most common cancer among females, it constituted 3.81% according to Iraqi Cancer Board Registry in 2009. 2 Due to their nonspecific initial symptoms, 70% of patients have widespread metastatic disease at the time of diagnosis.21 Various recent immunohistochemical studies of ovarian cancer have suggested that expression of particular markers may help in predicting outcome, and therefore guide therapeutic choices. 22 the present study showed no significant correlation between patient age and degree of WT1 expression ) P - value . (0.9 = There is no previous or similar studies found for comparison, but a study on thyroid gland

done by Katsuhiko et al 2007 . 24 agrees with our study which revealed no significant relationship between the age and the expression of WT1. The present study has shown that WT1 expression was significantly higher in serous than other ovarian tumor type (P-value 0.001) . And this agree with previous studies done by Goldstein et al. 2001,20 Al- Hussaini M. et al. 2004,25 Shimizu M. 2000, 9Acs G. et al. 2004, 26Euscher E. et al. 2005, 27 Goldstein N. et al 2002, 28Hylander B. et al 2006.29 While disagreed with other studies done by Lee B. et al. 2002,30 Hecht JL. et al. 2002, 31Goldestein N. et al. 2002, 28 who found that negative reaction of WT1 in serous ovarian carcinoma, the differences in the results may be due to differences in sample size, IHC protocols and the use of different primary antibody clone. The present study showed that no correlation of WT1 expression to the histological grade. (P-value 0.05). This result is in agreement with the results of the studies done by Shimizu et al., 9 Lee et al., 30 Hashi et al., 32 Al- Hussaini et al., 25Acs et al. 26 In contrast to Marianne W. et al 2005 study 33 result indicate that the expression related to the histological grade of differentiation, and these difference may be due to sample size, IHC protocol. there was marked significant correlation between WT1 and CA125 expression score (P-value 0.001) . This result is supported by studies done by Tornos C. et al. 2005 34 which shows (76% ) of ovarian carcinomas were positive for WT1, including ( 94% ) serous carcinomas, (90%) ovarian carcinomas were positive for CA125, most of them with strong and diffuse staining. there was significant correlation between WT1- MVD and CD34- MVD (P-value = 0.05). Unfortunately no similar study could be found either in Iraq or regional countries . But Satoshi D. et al 2010 35 studied endometrial cancer and revealed a strong association between WT1 expression and CD31 expression ( p< 0.001) . In contrast Iraqi study done by Mustapha et al 2013 36 on chronic myeloid leukemia revealed that there was no significant correlation between CD31 expression and WT1 expression. Assessment of immunomarkers expressions in malignant and control group cases:

In the present study there is no statically significant of WT1-MVD expression between malignant and control group cases (P- value = 0.8) There is no previous and similar study could be found for comparison. Regarding CD34-MVD there is no difference between malignant and control group cases in our study(P- value = 0.5). And this agree with Yi-Hsuan H. 2010, 14ES Bamberge 2002, 37and Makoto et al 1997 . 38 And the similarlarity in MVDs in the benign and malignant tumors suggested that angiogenesis in ovarian tumors is responsible for tumor growth rather than malignant transformation. Regarding WT1 expression in malignant and control group cases there is no correlation) .P -value. (0.001 And this agreed with Yi-Hsuan H. 2010 study .14 Regarding

the CA125 expression between malignant and control group cases in the present study showed marked correlation) P-value (0.001 and this agreed with

Yi-Hsuan H. 2010 . 14

**Author Contribution:**

Muna I. AL Hafedh : study conception ,design, practical part of IHC ,drafting of manuscript, interpretation of data and critical revision.

Sahira A. Ali : interpretation of data, histopathological examination and critical revision.

Lubab F. Talal: interpretation of data and critical revision.

**Reference:**

1-Greenlee RT, Murray T, Bolden S, Wingo PA. et al.: Cancer statistics. *CA Cancer J Clin*2000;50:7-33.

2-Ministry of Health results on Iraqi Cancer Registry 2009. Iraqi Cancer Board, Baghdad- Iraq.

3-Russell P. :Surface epithelial-stromal tumors of the ovary, in Kurman RJ. (ed):*Blaustein's Pathology of the Female Genital Tract*, New York, Springer- Verlag. 1994: 705-782.

4-Scott JR, Disaia PJ, Hammond CB, et al.: *Diseases of the ovary and fallopian tubes*. In: *Danforth's Obstetric and Gynecology*, LippincotWilliams and Wilkins (ed) . 8th ed. Philadelphia, wolters Kluwer Company 1999: 837-908.

5-Wagner N, Panelos J, Massi D , et al.: *The Wilms' tumor suppressor WT1 is associated with melanoma proliferation*. *PflugersArch* 2008; 455: 839-847.

6-Caldon CE, Lee CS, Sutherland RL, et al: *Wilms'tumor protein1: an early target of progesterin regulation in T-47D breast cancer cells that modulates proliferation and differentiation* . *Oncogen*. 2008;27:126-138.

7-Hashiba T, Izumoto S, Kagawa N, et al: *Expression of WT1 protein and correlation with cellular proliferation in glial tumors*. *Neurol Med Chir (Tokyo)* 2007. 47: 165-170.

8- Charles A. K. , I. E. Moore, P. J. Berry: *Immunohistochemical detection of the Wilm s'tumor gene WT1 in desmoplastic small round cell tumor*. *Histopathology*. 1997; 30:312-314.

9-Shimizu M, Toki T, Takagi Y, et al.: *Immunohistochemical detection of the Wilms' tumor gene (WT1) in epithelial ovarian tumors*. *Int J Gynecol Pathol*. 2000; 19:158-163.

10- Mi Y, Wang L, Bian S, et al.: *Effect of WT1 gene expression on cell growth and proliferation in myeloid leukemia cell lines*. *Chin Med J (Engl)* 1999;112:705- 708.

11- Köbel M, Kalloger SE, Carrick J, et al . :*A limited panel of immunomarkers can reliably distinguish between clear cell and high-grade serous carcinoma of the ovary*. *Am J Surg Pathol*.2009; 33(1):14-21 .

12- Semenza GL : *Angiogenesis in ischemic and neoplastic disorder*. *Annu Rev Med*. 2003;54: 17-28.

13- Li HJ. , Man YG.: *Dual usages of single Wilms'*

*tumor1immunohistochemistry in evaluation of breast tumors: Apreliminary study of 30 cases, cancerbiomarker* .2009;5(3):109- 16.

14- Yi-Hsuan H. , Sarwat S. , Yan-gao M.: *Dual use of a single Wilms'tumor Immunohistochemistry in evaluation of ovarian tumors: a preliminary study of 20cases*, *J Cancer*2010; 1:93-97. ( *IVSL*).

15- Markman M, Petersen J, Belland A, et al. : *CA-125 monitoring in ovarian cancer: Patient survey responses to the results of the MRC/EORTC CA-125 Surveillance Trial*. *Oncology*.2010; 78: 1-2.

16- Hylander B, Repasky E, Shrikant P, et al.: *Expression of Wilm s'tumor gene WT1 in epithelial ovarian cancer*. *Gynecol Oncol*.2006;101:12-17.

17- Satoshi O. , Satoshi D. , Yumiko O. , et al :*Immunohistochemical detection of WT1 protein in endometrial cancer* *Int J Gynecol Pathol*. 2000; 19:158-163.

18- Weidner N.: *Tumor Angiogenesis :Review of current applications in tumor prognostication*. *Seminars in Diagnostic Pathology*1993;vol.10,no.4: 302-313.

19-Subhash C , Ajay P , Fernanda R, et al: *Aberrant expression of MUC4in ovarian carcinoma: diagnostic significance alone and in combination with MUC1 and MUC16(CA125)*, 2006 July;19: 1386 1394-.

20- Goldstein NS et al: *WT1 is an Integral Component of an antibody Panel to distinguish Pancreaticobiliary and some ovarian epithelialneoplasms*. *Am J Clin Pathol*. 2001; 116 (2):246-52.

21-Smith EM, Anderson B: *The effects of symptoms and delay in seeking diagnosis on stage of disease at diagnosis among women with cancers of the ovary*. *Cancer*1985; 56:2727-2732.

22- Daponte A, Guidozi F, Tiltman AJ, et al: *p53 as a prognostic factor for stage III serous adenocarcinoma of the ovary*. *Anticancer Res* .1999; 19:2387-2389.

23- Carlson JW, Nucci MR, Brodsky J, et al.: *Biomarker-assisted diagnosis of ovarian, cervical and pulmonary small cell carcinomas: the role of TTF-1, WT1 and HPV analysis*. *Histopathology*. 2007; 51(3) : 305-312.

24- Katsuhiko T. , Masahiko I , Hiroshi S. , et al: *The relationship between wilm's tumor 1 (WT1) and paired Box 8 ( Pax-8) protein expression in papillary and anaplastic thyroid carcinomas*. *Kawasaki med J*. 2007 ; vol 33, no. 1:23-33.

25-Al-Hussaini M, Stockman A, Foster H, et al.: *WT-1 assists in distinguishing ovarian from uterine serous carcinoma and in distinguishing between serous and endometrioid ovarian carcinoma*. *Histopathology*. 2004; 44:109-115.

26- Acs G, Pasha T, Zhang PJ.: *WT1 is differentially expressed in serous, endometrioid, clear cell, and mucinous carcinomas of the peritoneum, fallopian tube, ovary, and endometrium*. *Int J Gynecol Pathol*. 2004; 23:110-118.

- 27- Euscher ED, Malpica A., Deavers MT : Differential expression of WT-1 in serous carcinomas in the peritoneum with or without associated serous carcinoma in endometrial polyps. *Am J Surg Pathol.* 2005; 29:1074– 1078.
- 28- Goldstein NS, Uzieblo A. : WT1 immunoreactivity in uterine papillary serous carcinomas is different from ovarian serous carcinomas. *Am J Clin Pathol.* 2002;117: 541–545.
- 29- Hylander B, Repasky E, Shrikant P, et al.: Expression of Wilm's tumor gene (WT1) in epithelial ovarian cancer. *Gynecol Oncol.* 2006;101:12–17.
- 30- Lee BH, Hecht JL, Pinkus JL: WT1, estrogen receptor and progesterone receptor as marker for breast or ovarian primary sites in metastatic adenocarcinoma to body fluids. *Am J Clin Pathol.* 2002;117:745–750.
- 31- Hecht JL, Lee BH, Pinkus JL: The value of Wilms tumor susceptibility gene 1 in cytologic preparations as a marker for malignant mesothelioma. *Cancer Cytopathol.* 2002; 96:105–109.
- 32- Hashi A, Yuminamochi T, Murata S, et al : Wilms tumor gene immunoreactivity in primary serous carcinomas of the fallopian tube, ovary, endometrium and peritoneum. *Int J Gynecol Pathol.* 2003; 22: 374–377.
- 33- Marianne W., Anni G.: Immunohistochemical Expression of Wilms Tumor Gene Protein in different histologic subtypes of ovarian carcinomas . 2005; vol.129, Issue 1:85- 88.
- 34- Tornos C, Soslow R, Chen S, et al : Expression of WT1, CA 125, and GCDFP-15 as useful markers in the differential diagnosis of primary ovarian carcinomas versus metastatic breast cancer to the ovary. *Am J.* 2005; 29(11):1482-9.
- 35- Satoshi D., Satoshi O., Yumiko O., et al : WT1 expression correlates with angiogenesis in endometrial cancer tissue. *Anticancer research.* 2010; 30: 3187-3192 .
- 36- Mustpha A., Raad J., Qais A., et al : Immunohistochemical assessment of the role of WT1 protein expression in CML and its correlation with CD 31 as an angiogenic marker. *Iraqi J Med Sci* 2013; vol 11(3) : 297- 302.
- 37- E S Bamberger, C W Perrett : Angiogenesis in epithelial ovarian cancer. *Mol Pathol.* Dec 2002; 55(6): 348–359.
- 38- Makoto E., Hiroshi I., Kumi M., et al: Differences in the angiogenesis of benign and malignant ovarian tumors, demonstrated by analyses of color doppler ultrasound, immunohistochemistry and microvessel density. *American Cancer Society.* 1997; vol. 80 , issue 5:899–907.