

Do low back pain changes correlate with sagittal lumbar alignment changes after total hip replacement arthroplasty?

Firas Abdalhadi Alobidi* FICMS (Ortho.)

Abstract

Background: The hip joint and lumbar spine are both anatomically and functionally closely related as had shown by many authors. So the abnormality in one area can affect the other e.g. hip joint osteoarthritis can cause lumbar sagittal malalignment and backache.

Objectives: is to see if there is significant improvement in backache after total hip replacement? And which degree of backache improvement is associated with significant changes in lumbar lordosis?

Methods and patients: a prospective open trial study was performed on 30 patients who had severe hip osteoarthritis and chronic low back pain. Total hip replacement was performed to all patients. Backache and lumbar lordosis were measured by visual analogue scale and Cobb's angle respectively both before and 6 months after surgery. Patients were divided into 3 groups according to grade of improvement in backache after surgery.

Results: The improvement in low back pain after surgery was statistically significant for all patients and for each group separately, while the changes in lumbar lordosis were not statistically significant neither for all patients nor for any group separately.

Conclusions: total hip replacement surgery has significant positive effect on backache. There is no significant correlation between improvement in backache and changes in lumbar lordosis.

Key words: low back pain+lumbar lordosis+hip replacement.

Fac Med Baghdad
2015; Vol.57, No.2
Received: April, 2015
Accepted: May, 2015

Introduction:

The hip joint, pelvic girdle and lumbar spine movements are highly coordinated(1).Farfan (2) showed that normal lumbar lordosis and normal hip extension are important for normal function and activity in standing position and that they are closely related to each other. The hip-spine movement relationship was confirmed by Lee and Wong(3) who used video and electromagnetic study. Offierski and MacNab(4) were the first who used hip-spine syndrome term in 1983, when they reviewed 35 patients, they used the term simple hip-spine syndrome for those patients with clear coexistence of both hip and spine diseases, and they used the term secondary hip-spine syndrome for those patients in which the hip deformity aggravated their spine symptoms. Dubousset(5) used the term (pelvic vertebra) and he considered the pelvis as vertebra while treating complex pelvic deformities, indicating the effect of pelvic morphology on spine. when the hip joint was arthrodesed in wrong position, there was severe and rapid negative effect on the spine(6) whereas arthrodesing the hip joint in correct position had much better effect on the spine for up to 20 years of follow up(7,8). on the other hand, when the lumbar spinal fusion was accompanied by loss of normal lumbar lordosis, this had adverse effect on the hip joint(9). Kerboull et al, showed improved spinal outcome after total hip replacement(10,11). in 2007, Ben-Galim et al(12) reported improvement in both spinal function and low back pain after total hip replacement which was performed for 25 patients with severe osteoarthritis of the

hip joint, they followed their patients for sagittal spinal profile for up to 3 months after surgery, their patients age ranged from 32 to 84 years. In these studies, authors didn't evaluate if there is any significant correlation between different degrees of low back pain improvement on one side and their corresponding changes in lumbar lordosis on the other side after total hip replacement. So in the current study the aim was to evaluate if such correlation is present. In current study patients were followed for up to 6 months after surgery and patients aged more than 55 years were excluded from this study to rule out any age-related effects on the spine.

Patients and methods:

A prospective open trial nonrandomized study was performed on 30 patients(11 females, 36.7% and 19 males 63.3%), with an average age of 42.7 years, ranging from 27 to 55 years, who had diagnosed to have severe primary or secondary osteoarthritis in their hip joints and necessitated total hip replacement during the period from March 2012 to May 2014. The patients included in this study were those who needed unilateral total hip replacement and had low back pain for more than 3 months without any radiological features of spine disease and this low back pain was developed after hip pain, they were without history of any other chronic diseases, significant trauma, or previous spine surgery. Exclusion criteria were radicular limb pain, vascular claudication, any inflammatory or infectious disease of the spine, patient taking pain killers for their pain frequently, any neurological deficit, patients without any improvement in low back pain 6 months after surgery and

*Dept. of surgery, College of medicine, University of Baghdad.
E mail = firas75ortho@yahoo.com

any case with complicated surgery e.g. significant limb length discrepancy. Total hip replacement surgery was performed for all patients who were included in this study according to our routine. Pain in the lower back was measured by visual analogue scale (VAS) (13), hip function was measured by Harris hip score HHS (14), and spine function was measured by Oswestry disability index (ODI), for all patients before and 6 months after surgery. Standing lateral x-ray film, showing all lumbar, lower thoracic and upper sacral vertebrae was taken for all patients, both before and 6 months after surgery. Lumbar lordosis was measured by the Cobb's angle between the upper line passing through the superior endplate of first lumbar vertebra and lower line passing through superior endplate of first sacral vertebra (16), for all patients both before and 6 months after surgery (figure 1). The patients were divided into 3 groups according to the grade of improvement in their low back pain measured by VAS=

Group A= included those patients with 1 to 2 grade of improvement in VAS. Group B= included those patients with 3 to 4 grades of improvement in VAS. Group C = included those patients with more than 4 grades of improvement in VAS.

The evaluation of any statistically significant difference in lumbar lordosis before and 6 months after surgery was done firstly for all patients and secondly for each group separately, in order to see if there is any correlation between the changes in lumbar lordosis and the degree of improvement in low back pain after total hip replacement surgery.

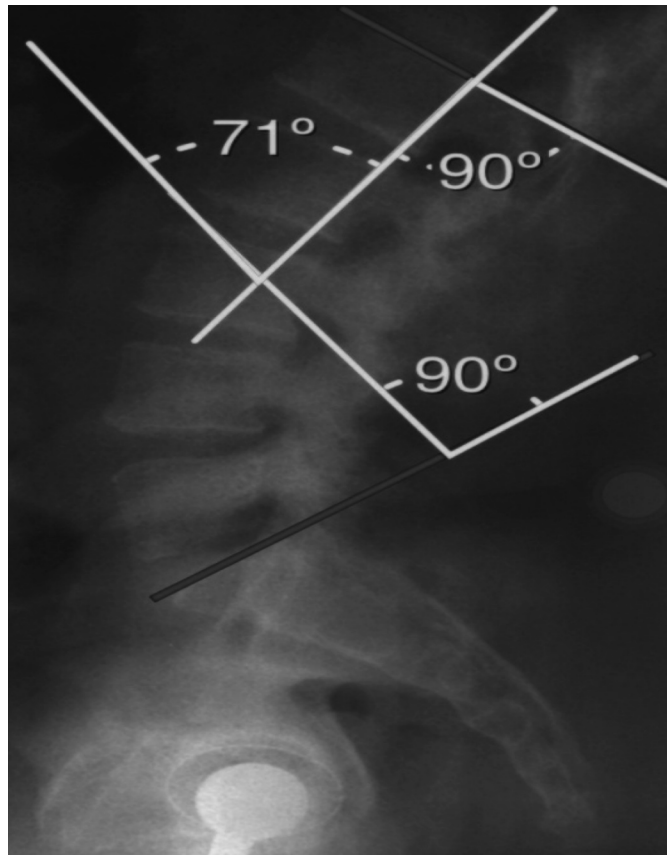


Figure 1

Results:

30 patients (11 females 36.7% and 19 males 63.3%) were included in this study with an average age of 42.7 years ranging from 27 to 55 years.

Regarding all patients=

The mean VAS score for pain in the lower back was 6.03 before surgery and 2.6 six months after surgery and this result was statistically significant ($p \text{ value} \leq 0.05$). The mean ODI score was 32.7 before surgery and 21.9 six months after surgery and this result was statistically significant ($p \text{ value} \leq 0.05$). The mean of HHS was 38.8 before surgery and 79.2 six months after surgery and this result was statistically significant ($p \text{ value} \leq 0.05$), this means that both spine and hip functions were improved significantly six months after surgery. The mean Cobb's angle of lumbar lordosis was 56.8° before surgery and 56.5° six months after surgery and this result was statistically not significant ($p \text{ value} > 0.05$).

Regarding groups=

In group A (made of 8 patients) the mean VAS score was 4.5 before surgery and 3 six months after surgery, and the mean of lumbar lordosis was 51.9° before surgery and 51.6° six months after surgery. The result was statistically significant for VAS score ($p \text{ value} \leq 0.05$) but statistically not significant for lumbar lordosis angle ($p \text{ value} > 0.05$).

In group B (made of 15 patients) the mean VAS score was 6.13 before surgery and 2.53 six months after surgery, and the mean of lumbar lordosis angle was 56.9° before surgery and 56.6° six months after surgery. The result was statistically significant for VAS score ($p \text{ value} \leq 0.05$) but statistically not significant for lumbar lordosis angle ($p \text{ value} > 0.05$).

In group C (made of 7 patients) the mean VAS score was 7.57 before surgery and 2.28 six months after surgery, and the mean lumbar lordosis angle was 62.3° before surgery and 61.8° six months after surgery. The result was statistically significant for VAS score ($p \text{ value} \leq 0.05$) and statistically not significant for lumbar lordosis ($p \text{ value} > 0.05$).

Discussion:

chronic low back pain continues to represent a difficulty in regard to both diagnosis and treatment (17). It is usually due to multifactorial etiology (18). Given the relationship between the lumbar spine, pelvic girdle and hip joint as mentioned above, the hip joint abnormality may be considered as a potential source of low back pain. Many authors had reported an increase in lumbar lordosis and sacral slop in patients complaining of hip joint disease (19,20). Offierski and MacNab (4) reported that fixed flexion deformity of the hip joint is compensated by pelvic rotation and increased lumbar lordosis and this can increase the load on the facet joints and ligaments in lumbar area causing pain. So treating the hip joint deformity and pathology during total hip replacement is expected to have

positive effect on low back pain by decreasing the lumbar lordosis and pelvic rotation. The results of the current study showed statistically significant improvement in low back pain measured by VAS six months after surgery both for all patients and for each group separately. But this was not accompanied by statistically significant change (decrease) in lumbar lordosis six months after surgery both for all patients and for each group separately. In spite of there was greater change (decrease) in lumbar lordosis in group C but again this was statistically not significant. This can be explained by the presence of other important etiological factors for low back pain in cases of osteoarthritis of the hip joint and not only the increased load on the facet joint. Many muscles have common attachment sites between hip joint and lumbar spine e.g. gluteus maximus, psoas, quadratus lumborum, etc and contracture, stretching or weakness in these muscles may affect movement of the spine, hip joint and pelvis. It was shown that decrease range of movement of the hip joint and weakness in the hip extensor, adductors or flexor endurance can cause low back pain (18). In addition, the diseased hip joint will affect the lumbar spine not only in the sagittal plane, but also in the coronal plane because those patients who have diseased hip joint e.g. osteoarthritis of the hip or weak abductors will bend their trunks laterally to the diseased hip during the stance phase of the gait in order to shift the line of gravity closer towards the diseased hip joint, this will shorten the moment arm between the hip joint and centre of body weight and will decrease the effort on hip abductors muscles (21), so there will be more load on one side of the lumbar spine in coronal plane which is the same side of the diseased hip joint during walking.

The normal range of lumbar lordosis is still unknown and it is related to many individual factors e.g. body weight, level of activity, strength of muscles (22). This indicates that some patients have relatively larger lumbar angle from the start and that their compensatory increase in their lumbar lordosis was less in comparison to other patients, so they may show less change (reduction) in their lumbar angle post surgery in spite of significant improvement in their low back pain.

Conclusions and recommendations:

The current study showed that doing uncomplicated total hip replacement surgery for patients who have both osteoarthritis of the hip joint and chronic low back pain without radiological spine disease have significant positive effect on low back pain.

All degrees of improvement in low back pain were not associated with significant change in lumbar lordosis.

Further studies are needed to outline other causes of low back pain in patients with osteoarthritis of the hip joint rather than sagittal lumbar spine abnormality.

References:

- 1-Redmond M, Gupta A, Nasser R, Domb B. *The hip-spine connection: understanding its importance in the treatment of hip pathology.* *cme ARTICLE* 2015; 38(1):49-55.
- 2-Farfan HF. *The biomechanical advantage of lordosis and hip extension for upright activity: man as compared with other anthropoids.* *Spine (phila pa 1976)* 1978; 3(4):336-342.
- 3-Lee RY, Wong TK. *Relationship between the movements of the lumbar spine and hip.* *Hum Mov Sci* 2002; 21(4):481-494.
- 4-Offierski CM, MacNab I. *Hip- spine syndrome.* *Spine (phila pa 1976)* 1983; 8(3):316-321.
- 5-Dubousset J. *Pelvic obliquity.* *Orthopedics* 1991; 14(4):479-481.
- 6-Gore DR, Murray MP, Sepic SB, Gardner GM. *Walking patterns of men with unilateral surgical fusion.* *J Bone Joint Surg* 1975; 57 A: 759-765.
- 7-Callaghan JJ, Brand RA, Pedersen DR. *Hip arthrodesis. A long- term follow up.* *J Bone Joint Surg* 1985; 67 A: 697-704.
- 8-Sponseller PD, McBeath AA, Perpich M. *Hip arthrodesis in young patients. A long term follow up study.* *J Bone Joint Surg* 1984; 66 A: 853-859.
- 9-Lazennec Y, Rumares S, Arafati N, Laudet G, Gorin M, Roger B et al. *Sagittal alignment in lumbosacral fusion : relations between radiological parameters and pain.* *European Spine Journal* 2000; 9(1):47-55 (VL).
- 10-Kerboull M, Hamadouche M, Kerboull L. *Total hip arthroplasty for Crowe type 6 developmental hip dysplasia.* *J Arthroplasty* 2001; 16(8, suppl.1):170-176.
- 11-Hamadouche M, Kerboull L, Meunier A, Courpied JP, Kerboull M. *Total hip arthroplasty for the treatment of ankylosed hips.* *J Bone Joint Surg* 2001; 87 A: 992-998.
- 12-Ben-Galim P, Ben- Galim T, Rand N, et al. *Hip- spine syndrome: the effect of total hip replacement surgery on low back pain in severe osteoarthritis of the hip.* *Spine (phila pa 1976)* 2007; 32(19):2099-2102.
- 13-McCormack HM, Horne DJ, Sheathers S. *Clinical applications of visual analogue scales: a critical review.* *Psychol Med* 1988; 18: 1007-1019.
- 14-Harris WH. *Traumatic arthritis of the hip after dislocation and acetabular fractures: treatment by mold arthroplasty. An end- result study using a new method of result evaluation.* *J Bone Joint Surg Am* 1969 ; 51(4):737-755.
- 15-Fairbank JC, Pnsent PB. *The Oswestry Disability Index.* *Spine* 2000; 25(22):2940-2952.
- 16-Zhu Z, Xu L, Zhu F, Jiang L, Wang Z, Liu Z. *Sagittal Alignment of the spine and pelvis in Asymptomatic Adults.* *Spine* 2013; 39(1):E1-E6.
- 17-Lotz JC, Fields AJ, Liebenberg EC. *The Role of the*

Vertebral End Plate in Low Back Pain. Global Spine J 2013; 3:153-164.

18-Reiman P, Weisbach P, Glynn E. The Hip's influence on Low Back Pain: A Distal link to a proximal problem. Journal of Sport Rehabilitation 2009; 18, 1-10.

19-Okuda T, Fujita T, Kaneuji A, Miaki k, Yasuda Y, Matsumoto T. Stage- specific sagittal spinopelvic alignment changes in osteoarthritis of the hip secondary to developmental hip dysplasia. Spine (phila pa 1976) 2007;32(26) :E 816-E819.

20- Yoshimoto H, Sato S, Masuda T, et al. Spinopelvic alignment in patients with osteoarthrosis of the hip : a radiographic comparison to patients with low back pain. Spine (phila pa 1976) 2005; 30(14):1650-1657.

21-Reininga I, Stevens M, Wagenmakers R, Bulstra S, Groothoff J, Zijlstra W. Subjects with hip osteoarthritis show distinctive patterns of trunk movements during gait- a body fixed- sensor based analysis. J Neuroeng Rehabil 2012; 9:3.

22- Been E, Kalichman L. Lumbar lordosis. The Spine Journal Jan 2014; 14(1):87-97 (VL).