

Immunohistochemical Expression and Histopathological Role of CD47 in Colorectal Cancer in Iraqi Patients

Fatima O. Abd alkareem*¹ , Ban J. Mohamad¹ 

¹ Department of Biology, College of Science, University of Baghdad. Baghdad, Iraq.



©2024 The Author(s). Published by College of Medicine, University of Baghdad. This open-access article is distributed under the terms of the Creative Commons Attribution 4.0 International License, which permits unrestricted use, distribution, and reproduction in any medium, provided the original work is properly cited.

Abstract

Background: Bowel cancer is the most prevalent digestive system cancer and is the 4th largest cause of cancer-related death worldwide. In Iraq, colon and rectal cancer (CRC) is the 6th most common malignancy in males and the 5th in females. This cancer is sluggish in growth, which gives a window of opportunity to screen for both precursor lesions and early cancer. The Cluster of Differentiation 47 (CD47) protein is a type of transmembrane glycoproteins found on nearly all human cells, including non-hematopoietic and hematopoietic cells. CD47 promotes CRC growth by triggering angiogenesis and apoptosis of tumor cell.

Objectives: To evaluate the immunohistochemical expression of (CD47) in various colorectal samples from Iraqi patients with CRC by immunohistochemistry (IHC) assay.

Methods: A total of 45 paraffin-embedded CRC tissue specimens and clinical data were obtained from the Medical City Teaching Hospital in Baghdad and a number of private laboratories in Baghdad, Iraq. In addition, 30 control colon and rectum tissues with no significant pathology were collected from the Forensic Medicine Department for comparison purposes after taking the official approvals.

Results: The results revealed a high expression of CD47 in CRC cases, but with no significant correlation with clinicopathological features. Also, the result of figures in this study revealed negative membranous expression of CD47 (score 0), strong membranous expression of CD47 (score 8), moderately membranous expression of CD47 (score 7), and weak membranous expression of CD47 (score 4)

Conclusion: Patients with CRC had high CD47 expression, allowing tumor cells to modulate CD47SIRP inhibitory signaling and prevent immune cell attack.

Keywords: Colorectal cancer; Cluster of Differentiation 47; Immunohistochemistry; Integrin-associated protein.

Received: Dec. 2023

Revised: Jan. 2024

Accepted: Feb. 2024

Published: Jul. 2024

Introduction

Colon and rectal cancer (CRC), also known as bowel cancer, is the 4th most prevalent malignant disease worldwide, characterized by irregular growth of the colon epithelium which occupies the entire wall thickness of the colon, with metastasis to the surrounding lymph nodes and neighboring tissues, and finally distant metastatic spread (1). Most CRCs are slow-growing lesions that develop from polyps that are adenomatous or sessile serrated lesions (2). The probability of developing CRC is influenced by genetic and/or environmental factors (3).

CRC begins with vague signs and symptoms such as altered bowel habits, including constipation or diarrhea, changes in stool consistency, bleeding from the rectum, persistent gastrointestinal discomfort, e.g., cramps, pain or gases, tenesmus, fatigue, and unexplained weight loss. Screening for CRC can be done by measuring serum levels of various tumor markers, such as CA19-9, CEA, CCA-3, and CCA-4 (4). In accordance with the American Cancer Society, approximately 1 in 21 males and 1 in 23 females in the United States will develop CRC

over their lifetime (5). CRC can be classified as proximal or right side if it develops from proximal portions to the splenic flexure (cecum, transverse colon and ascending colon), distal or left side if it originates distally to the descending colon or sigmoid, and rectal if it develops within 15 cm of the anal sphincter. (6).

CRC become more prevalent with increasing age, especially after the age of 55 years, with roughly 60% of the cases affecting those 70 years or older. Iraq has a low incidence of CRC, although it has been steadily increasing over time (7).

Prediction models based on tumor markers, as well as clinicopathological and demographic factors, have recently been broadly developed for the prognosis of CRC (8).

Cluster of differentiation 47 (CD47) (also referred as OA3 and IAP) a transmembrane glycoprotein that is present on nearly all cells in the human body. CD47 was found independently in numerous cell types, resulting in a wide range of nomenclature. Because it was found to be associated with integrins, such as v3, on various types of cells, it was first referred as Integrin-Associated Protein (IAP). Furthermore,

*Corresponding author:
<mailto:fatma.omar1602a@sc.uobaghdad.edu.iq>

being highly expressed on ovarian malignant cells, this antigen was also identified as OA3 (9). CD47 is the signaling receptor with high affinity for the secretory protein thrombospondin-1 (THBS1) and a counter-receptor for the signal regulatory protein alpha (SIRP α) (10). The binding of SIRP α to CD47 triggers SIRP α phosphorylation of ITIMs (immunoreceptor tyrosine-based inhibitory motifs) resulting in deactivation of myosin IIA, which is a critical step to block phagocytosis (11).

Specimens and Methods

From October 2022 to January 2023, 75 cases of colonic biopsies (excisional biopsy and total colectomy) were collected. The tissue samples were collected in the form of formalin-fixed paraffin-embedded (FFPE) blocks of tissue from the archive files of the Pathology Department/ Teaching Laboratories/ Baghdad Medical City Teaching Hospital and a number of private laboratories in Baghdad, Iraq. These samples belong to the years 2019, 2020, 2021, 2022, and 2023. The samples were further classified into 45 cases of malignant tumors from CRC cases and 30 colon biopsies from cadavers in the Forensic Medicine Department (not CRC cases) for comparison purposes after obtaining the official approvals. They were preserved in 10% formalin before being subjected to the standard tissue processing sequence and being turned into paraffin blocks.

Demographic and clinical data including age, gender, size and site of tumor, pathological stage, and grade were collected from the patients' records. All the preparations for slide sectioning, Hematoxylin/Eosin staining, and IHC staining were performed at a private laboratory.

Immunohistochemistry staining: The specific antibody/ antigen binding in tissue is the basic concept of this method. A variety of spotting techniques are then used to visualize the bound antigen-antibody complex. IHC detects the antigens of interest using a variety of enzymatic markers, including alkaline phosphatase and peroxidase (12). The IHC staining process was followed exactly as specified by the kit manufacturers' protocols (Abcam, anti-CD47 antibody, EPR21794, ab218810 and PolyExcel, HRP/DAB Detection System). The general protocol was adopted in accordance with Magaki *et al.*, 2019 (13). First, the tissue sections were de-waxed by heating the slides in an oven at 60-65°C for 30 minutes, followed by rapid rinsing in xylene and re-heating in the oven for 5 minutes. The sections were hydrated again via immersing them in decreasing concentrations of alcohol. After dipping the slides in the solution of antigen retrieval, they were put in a water bath heated to (95 °C) and allowed to boil for 30 minutes. After that, the slides were treated for 10 minutes with a Peroxidase Quencher (H2O2) solution. (CD47) primary antibody diluted to (1:2000) was applied to the tissue sections, and incubated at room temperature in a humidity chamber

for 30 minutes. After cleaning the tissue sections, the PolyExcel Target Binder (Cat# IPS006) was added to the slides which were then incubated for 15 minutes at room temperature in the humidity chamber. The slides were then coated with PolyExcel PolyHRP (Cat# IPS007) and incubated in the humidity chamber for 15 minutes at room temperature. Afterwards, PolyExcel StunnDAB with its substrate were applied to the slides and incubated in a humidity chamber at room temperature for 5 minutes until the brown stains appeared. The tissue sections were then washed two times with Tris-Buffer-Saline (TBS) for 5 minutes each. The slides were then counterstained with drops of Mayer' Hematoxylin for 1-2 minutes before being carefully cleaned in distilled water (DW) until clear. The slides were then dehydrated in increasing concentrations of alcohol and cleared in xylene for two times at two minutes each. In the end, by using the DPX mounting medium, the slides were mounted and coverslipped.

Scoring system of immunohistochemistry: CD47 scoring system was applied according to Allred score (14). The altered score was calculated using the formula clarified in Table 1. The findings were evaluated and analyzed by a pathologist.

Table 1: Formula and scores employed based on the Allred score system for immunohistochemistry

Intensity score (IS)	Proportion score (% Stained Cells) (PS)
0 (non-staining)	0 (no cells)
1 (stain is weak)	1 (<1%)
2 (stain is moderate)	2 (1-10%)
3 (stain is strong)	3 (11-33%)
	4 (34-66%)
	5 (67-100%)

Total score (TS)= PS+IS; total score ranges from (0-8), where (0-2) were considered negative and (3-8) was considered positive

Statistical analysis

For data analysis, the SPSS-28 (Statistical Packages for Social Sciences - Version 28) was used. The data were presented in simple frequencies, percentages, means, standard deviations, and ranges. To test for associations between variables, the Chi-square test was performed (15), and a P value of <0.05) was considered significant.

Results

Immunohistochemical expression of CD47 in CRC: CD47 expression is observed in tumor cells as brown membranous staining (Figures: 1, 2, 3, and 4).

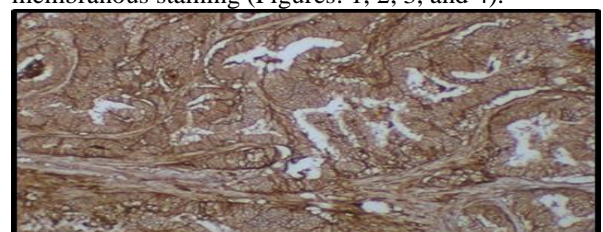


Figure 1: Strong membranous expression of CD47 in CRC (score 8) (4X)

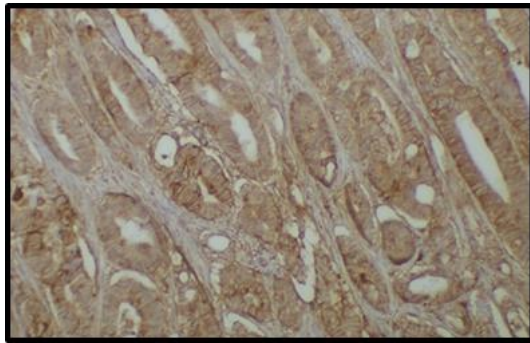


Figure 2: Moderate membranous expression of CD47 in CRC (score 7) (4x)

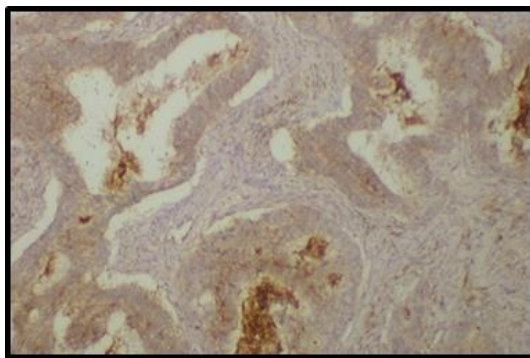


Figure 3: Weak membranous expression of CD47 in CRC (score 4) (4x)

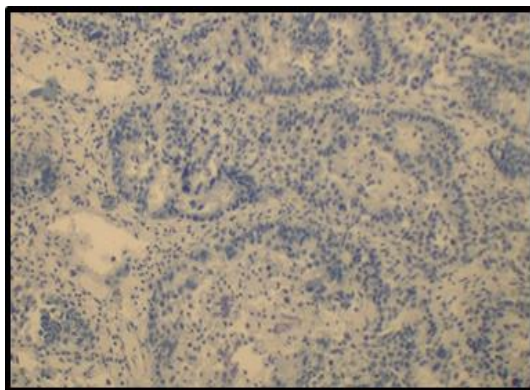


Figure 4: Negative membranous expression of CD47 in CRC (score 0) (4x)

CD47 expression was positive in 91.1% of malignant cases, while it was negative in 100% of normal colorectal tissues, with a significant association, (Table 2).

Table 2: Expression of CD47 malignant colon tissue from CRC patients and controls

Expression	CD47		Control	
	No.	(%)	No.	(%)
Positive	41	91.1	0	0
Negative	4	8.9	45	100
P value	(<0.001) *			

Significant association between CD47 expression in CRC cases and controls using Chi-square test.

Association of CD47 with demographic and clinicopathological features: The results showed no significant associations between CD47 expression

and age, gender, tumor site and diameter, tumor stage and grade, histological type, and lymph node metastasis (Table 3).

Table 3: Associations of CD47 with demographic and clinical variables in Iraqi CRC patients

Clinicopathological features		CD47		p-value
		+	-	
Age	<40	6	0	0.754 NS
	40-49	7	0	
	50-59	10	3	0.213 NS
	>60	18	1	
Gender	Male	19	2	0.165 NS
	Female	22	2	
Tumor Size	<5 cm	29	1	0.213 NS
	>5 cm	12	3	
Tumor Site	Left	26	4	0.574 NS
	Right	15	0	
Stage	IIA	13	3	0.463 NS
	IIC	2	0	
	IIIA	3	0	
	IIIB	18	1	
	IIIC	5	0	
Grade	I	1	1	0.092 NS
	II	38	4	
	III	1	0	
Histological Type	Adenocarcinoma	35	4	0.756 NS
	Mucinous	4	0	
	Signet ring cell	2	0	
Lymph Node Metastasis	Positive	19	0	0.307 NS
	Negative	22	4	

No significant associations were found using the Chi-square test.

Discussion

In the recent years, extensive research has been carried out in an effort to predict illness progression and discover novel treatments for CRC. Immunotherapy has been a significant advance in cancer treatment. This immunotherapy works through blocking checkpoints, one of which is CD47 (16). CD47, an important molecule for the macrophage checkpoint, was discovered to be excessively expressed in the hematological and solid cancers with poor prognosis. CD47 tumor expression is associated with immune evasion via malignant cells through the CD47-SIRP alpha pathway (17). CD47 was first identified as a tumor antigen on human ovarian cancer in the 1980s, and its overexpression is associated with a poor prognosis in ovarian cancer (18).

Most normal cells have the CD47 integrin, which binds to the extracellular domain of SIRP on macrophages and inhibits their phagocytic activity. When mature blood cells, such as RBCs lose their CD47 molecules, they become the target for macrophage-mediated removal from the circulation (19). Cancer cells overexpress CD47 in order to avoid the innate immune response of M1 macrophages by attaching to their SIRP receptor.

The host's adaptive and innate immune systems play essential roles in eliminating malignant cells and preventing progression of tumors, while cancer cells display immunological escape by expressing immune checkpoint proteins such as CD47 (20). When activated by CD47 binding, the regions of

immunoreceptor tyrosine-based inhibitory motif (ITIM) turn into phosphorylated, resulting in activation and recruitment of the protein tyrosine phosphatases, which results in the dephosphorylation of next molecules, like myosin IIA, and the suppression of phagocytosis activity (21). Many studies reported that expression of CD47 is a prognostic marker in many different types of malignancy (22).

In the current study, 45 cases of CRC were immunohistochemically examined for CD47, and the association of their CD47 expression with demographic and clinicopathological characteristics was investigated.

The result demonstrated that CD47 was positively expressed in (91.1%) of all malignant cases. This result is in corresponds to those reported by Sugimura-Nagata et al who found a higher expression of CD47 in malignant than in normal cells. This suggests that the limitedly-expressed CD47-dependent activation of the CD47–SIRPA signaling in the CRC microenvironment has a significant impact on the clinical outcome of CRC, as similarly observed for other malignancies (17).

Another aspect of the current study is the association between CD47 expression and different demographic and clinicopathological features, especially age. The lack of association between the expression of CD47 and age groups is in agreement with the results of Fujiwara-Tani et al (23) who reported no such association between the expression of CD47 and age groups in CRC cases. A study on stomach cancer also found no such association (24).

In the current study, there was no association between tumor site and size of CRC with CD47 expression. These findings correspond with those reported by Hu et al (25). A study on gastric carcinoma (26) reported no association between expression of CD47 and tumor diameter and location. Moreover, there was no association between CD47 expression in CRC cases and gender in the current study, and in that conducted by Ji et al on CRC cases (27) and that conducted by Peng et al on lung squamous cell cancer (28).

The current study found no association between CD47 expression and the histological type of the malignant tumor. Similarly, Bang found no association between CD47 expression and histological type of non-melanoma skin cancers (29), while Sugimura-Nagata et al (17) reported that CD47 positivity was associated with histological differentiation in CRC. The current investigation found no association between CD47 and the stage or grade of CRC, whereas Yuan et al in their breast cancer study, found a statistically significant association between CD47 expression levels and the stage and grade of breast cancer (30).

Immune avoidance is critical for progressing to the developed stage of colorectal adenoma (CRA), and some researchers have found that a higher concentration of tumor-associated macrophage (TAM) associate with more developed CRC stages. This might indicate that, through the “don't eat me

signal”, the CD47 expression, which inhibits phagocytic activity, rises in more developed stage as well (31). The current study found no association between CD47 expression and lymph node involvement. In CRC patients, CD47 was found to be strongly associated with recurrence, American Joint Committee on Cancer (AJCC) stage, and metastasis. A study on CD47 expression in triple negative breast cancer found no significant association with lymph node metastasis (32). These findings strongly suggest that CD47 expression may play an important role in controlling human CRA progression. Our findings show that CD47 overexpression enhances CRC metastasis and cell proliferation.

The differences between our results and those of other studies may due to differences in histological specimens, race, genetic factors, methodology and kits used. This is the first study in Iraq on CD47 in CRC patients.

Conclusions

The study suggests that increased CD47 expression in CRC patients, allows tumor cells to control CD47/SIRP inhibitory signals and prevent immune cell attack. There was no association between CD47 expression and demographic and clinicopathological features of CRC patients.

Authors' declaration:

We confirm that all the Figures and Tables in the manuscript are mine/ ours. Besides, the authors have signed an ethical consideration's approval-Ethical Clearance. The project was approved by the local ethical committee in the College of Science, according to the guidelines on biomedical research, the license has the code number CSEC/0922/0109 and is dated September 28, 2022.

Conflicts of Interest: None

Funding: None.

Author contributions:

Study conception & design: (Fatima O. Abd alkareem) and Dr. Ban J. Mohamad), Literature search: (Fatima O. Abd alkareem), Data acquisition: (Fatima O. Abd alkareem), Data analysis & interpretation, Manuscript preparation (Fatima O. Abd alkareem and Dr. Ban J. Mohamad).

References

1. Mahmood AH, Zeiny SM, Mahmood AS. Serological markers “CEA test & sAPRIL test” in Iraqi patients with colon cancer. *Journal of the Faculty of Medicine Baghdad*. 2017;59(4):317-20 <https://doi.org/10.32007/jfacmedbagdad.59472>.
2. Shaukat A, Levin TR. Current and future colorectal cancer screening strategies. *Nature Reviews Gastroenterology & Hepatology*. 2022;19(8):521-31 <https://doi.org/10.1038/s41575-022-00612-y>
3. Ahmed M. Colon cancer: a clinician's perspective in 2019. *Gastroenterology research*. 2020; 13 (1): 1 <https://doi.org/10.14740/gr1239>.

4. AL-Obaidy AA, AL-Hadithi HS, Mahmood AS. The value of serological markers (CA19-9 & CCSA4) in the screening and prognosis of colon cancer. *Journal of the Faculty of Medicine Baghdad*. 2017;59(1):93-7 <https://doi.org/10.32007/jfacmedbagdad.591176>.
5. Al-Rubaiaee SAT, Al-Tae JTK. Detection of BRAFV600E Biomarker in Patients with Colorectal Cancer Using Immunohistochemical Techniques/A ClinicPathological Study. *Journal of the Faculty of Medicine*. 2022;64.(1) <https://doi.org/10.32007/jfacmedbagdad.6411888>.
6. Sabry SA, Ibrahim MJ, Jabarah MA. Relationship of the quality of life in capecitabine-treated colorectal cancer patients to sociodemographic characteristics and drug-related adverse effects. *Journal of the Faculty of Medicine Baghdad*. 2022;64(3):175-82 <https://doi.org/10.32007/jfacmedbagdad.6431970>.
7. Aljarshawi M, Albadree H, Bahar H, Al-Imam A. Misleading Presentation of Colorectal Cancer in an Otherwise Healthy Patient. *J Fac Med Baghdad*. 2020;62(4):132-8 <https://doi.org/10.32007/jfacmedbagdad.6241800>.
8. Li C, Zhao K, Zhang D, Pang X, Pu H, Lei M, et al. Prediction models of colorectal cancer prognosis incorporating perioperative longitudinal serum tumor markers: a retrospective longitudinal cohort study. *BMC medicine*. 2023;21(1):63 <https://doi.org/10.1186/s12916-023-02773-2>.
9. Behrens LM, van den Berg TK, van Egmond M. Targeting the CD47-SIRPα innate immune checkpoint to potentiate antibody therapy in cancer by neutrophils. *Cancers*. 2022;14(14):3366 <https://doi.org/10.3390/cancers14143366>.
10. Kaur S, Isenberg JS, Roberts DD. CD47 (cluster of differentiation 47). *Atlas of genetics and cytogenetics in oncology and haematology*. 2021;25(2):83 <https://www.ncbi.nlm.nih.gov/pmc/articles/PMC8547767/>.
11. Jia X, Yan B, Tian X, Liu Q, Jin J, Shi J, et al. CD47/SIRPα pathway mediates cancer immune escape and immunotherapy. *International journal of biological sciences*. 2021;17(13):3281 <https://doi.org/10.7150%2Fijbs.60782>.
12. Hussaini HM, Seo B, Rich AM. *Immunohistochemistry and immunofluorescence. Oral Biology: Molecular Techniques and Applications*: Springer. 2022: 439-50 https://link.springer.com/protocol/10.1007/978-1-0716-2780-8_26.
13. Magaki S, Hojat SA, Wei B, So A, Yong WH. An introduction to the performance of immunohistochemistry. *Biobanking: Methods and Protocols*. 2019: 289-98 https://link.springer.com/protocol/10.1007/978-1-4939-8935-5_25.
14. Yordanov A, Shivarov V, Kostov S, Ivanova Y, Dimitrova P, Popovska S, et al. Prognostic Utility of CD47 in Cancer of the Uterine Cervix and the Sensitivity of Immunohistochemical Scores. *Diagnostics*. 2023; 13(1):52. <https://doi.org/10.3390/diagnostics13010052>
15. Torres JA, Brito ABC, Silva VSe, Messias IM, Braun AC, Ruano APC, et al. CD47 Expression in Circulating Tumor Cells and Circulating Tumor Microemboli from Non-Small Cell Lung Cancer Patients Is a Poor Prognosis Factor. *International Journal of Molecular Sciences*. 2023;24(15):11958
16. Murata Y, Saito Y, Kotani T, Matozaki T. CD 47-signal regulatory protein α signaling system and its application to cancer immunotherapy. *Cancer Science*. 2018;109(8):2349-57 <https://doi.org/10.1111/cas.13663>.
17. Sugimura-Nagata A, Koshino A, Inoue S, Matsuo-Nagano A, Komura M, Riku M, et al. Expression and prognostic significance of CD47-SIRPα macrophage checkpoint molecules in colorectal cancer. *International Journal of Molecular Sciences*. 2021;22(5):2690 <https://doi.org/10.3390/ijms22052690>.
18. Tian L, Xu B, Teng K-Y, Song M, Zhu Z, Chen Y, et al. Targeting Fc receptor-mediated effects and the “Don't Eat Me” signal with an oncolytic virus expressing an anti-CD47 antibody to treat metastatic ovarian cancer. *Clinical Cancer Research*. 2022;28(1):201-14 <https://doi.org/10.1158/1078-0432.CCR-21-1248>
19. Melo Garcia L, Barabé F. Harnessing macrophages through the blockage of CD47: implications for acute myeloid leukemia. *Cancers*. 2021;13(24):6258 <https://doi.org/10.3390/cancers13246258>.
20. Feng M, Jiang W, Kim BY, Zhang CC, Fu Y-X, Weissman IL. Phagocytosis checkpoints as new targets for cancer immunotherapy. *Nature Reviews Cancer*. 2019;19(10):568-86 <https://doi.org/10.1038/s41568-019-0183-z>.
21. Dizman N, Buchbinder EI. Cancer therapy targeting CD47/SIRPα. *Cancers*. 2021; 13(24):6229 <https://doi.org/10.3390/cancers13246229>.
22. Chen Y, Klingen TA, Aas H, Wik E, Akslen LA. CD47 and CD68 expression in breast cancer is associated with tumor-infiltrating lymphocytes, blood vessel invasion, detection mode, and prognosis. *The Journal of Pathology: Clinical Research*. 2023;9(3):151-64 <https://doi.org/10.1002/cjp2.309>.
23. Fujiwara-Tani R, Sasaki T, Ohmori H, Luo Y, Goto K, Nishiguchi Y, et al. Concurrent expression of CD47 and CD44 in colorectal cancer promotes malignancy. *Pathobiology*. 2019;86(4):182-9 <https://doi.org/10.1159/000496027>.
24. Sudo T, Takahashi Y, Sawada G, Uchi R, Mimori K, Akagi Y. Significance of CD47 expression in gastric cancer. *Oncology letters*. 2017;14(1):801-9 <https://doi.org/10.3892/ol.2017.6257>.

25. Hu T, Liu H, Liang Z, Wang F, Zhou C, Zheng X, et al. Tumor-intrinsic CD47 signal regulates glycolysis and promotes colorectal cancer cell growth and metastasis. *Theranostics*. 2020;10(9):4056
<https://doi.org/10.7150/thno.40860>.
26. Zhao Q, Cai Q, Yu S, Ji J, Zhu Z, Yan C, et al. Combinatorial Analysis of AT-Rich Interaction Domain 1A and CD47 in Gastric Cancer Patients Reveals Markers of Prognosis. *Frontiers in cell and developmental biology*. 2021; 9:745120
<https://doi.org/10.3389/fcell.2021.745120>.
27. Ji K, Zhang Y, Jiang S, Sun L, Zhang B, Hu D, et al. SIRPα blockade improves the antitumor immunity of radiotherapy in colorectal cancer. *Cell Death Discovery*. 2023;9(1):180
<https://doi.org/10.1038/s41420-023-01472-4>.
28. Peng Y, Qiu B, Tan F, Xu J, Bie F, He H, et al. TIGIT/CD47 dual high expression predicts prognosis and is associated with immunotherapy response in lung squamous cell carcinoma. *Thoracic Cancer*. 2022; 13(14):2014-23
<https://doi.org/10.1111/1759-7714.14478>.
29. Bang S, Jee S, Son H, Cha H, Park H, Myung J, et al. CD47 Expression in Non-Melanoma Skin Cancers and Its Clinicopathological Implications. *Diagnostics*. 2022;12(8):1859
<https://doi.org/10.3390/diagnostics12081859>.
30. Yuan J, He H, Chen C, Wu J, Rao J, Yan H. Combined high expression of CD47 and CD68 is a novel prognostic factor for breast cancer patients. *Cancer Cell International*. 2019; 19:1-12
<https://doi.org/10.1186/s12935-019-0957-0>.
31. Kang JC, Chen JS, Lee CH, Chang JJ, Shieh YS. Intratumoral macrophage counts correlate with tumor progression in colorectal cancer. *Journal of surgical oncology*. 2010;102(3):242-8
<https://doi.org/10.1002/jso.21617>.
32. Yuan J, Shi X, Chen C, He H, Liu L, Wu J, et al. High expression of CD47 in triple negative breast cancer is associated with epithelial-mesenchymal transition and poor prognosis. *Oncology Letters*. 2019; 18(3):3249-55
<https://doi.org/10.3892/ol.2019.10618>.

How to Cite

Abd alkareem FO, Mohamad BJ. Immunohistochemical Expression and Histopathological Role of CD47 in Colorectal Cancer in Iraqi Patients. *J Fac Med Baghdad*. 2024;66(2):122-8.

Available from:

<https://ijmc.uobaghdad.edu.iq/index.php/19JFacMedBaghdad36/article/view/2275>

التعبير النسيجي الكيميائي المناعي لبروتين CD47 في سرطان القولون في المرضى العراقيين

فاطمة عمر عبدالكريم¹، بان جاسم محمد¹
¹ قسم علوم الحياة، كلية العلوم، جامعة بغداد، بغداد، العراق.

الخلاصة:

خلفية البحث: سرطان الأمعاء هو أحد أكثر الأورام الخبيثة شيوعاً في الجهاز الهضمي ويعتبر السبب الرابع للوفيات بسبب السرطان في العالم. في العراق، يعتبر سرطان القولون والمستقيم أحد الأورام الخبيثة والسادس الأكثر شيوعاً في الرجال والخامس في النساء. بسبب النمو البطيء لهذا النوع من السرطان، هناك فرصة لفحص كل من السرطان المبكر والآفات المسببة. مجموعة التمايز 47 (CD47) هو أحد أنواع البروتينات الغشائية السكرية ويوجد تقريباً في جميع خلايا جسم الإنسان، والتي تشمل الخلايا المكونة للدم وغير المكونة للدم. CD47 يحفز نمو سرطان القولون عن طريق تكوين الاوعية الدموية والموت المبرمج للخلايا السرطانية.

الاهداف: تقييم التعبير النسيجي المناعي ل(CD47) في عينات مختلفة لسرطان القولون في المرضى العراقيين عن طريق الفحص الكيميائي المناعي النسيجي.

المنهجية: تم جمع 45 عينة من سرطان القولون والمستقيم المدمجة في شمع البارافين والمعلومات السريرية من مستشفى مدينة الطب التعليمية المختبرات الخاصة في بغداد، العراق. بالإضافة الى ذلك تم جمع 30 عينة من القولون والمستقيم التي لا تعاني حالة مرضية من قسم الطب الشرعي لأعراض المقارنة في هذه الدراسة بعد اخذ الموافقات الرسمية.

النتائج: اظهرت النتائج وجود تعبير عالي ل CD47 في سرطان القولون والمستقيم، ولم يظهر أي ارتباط معنوي بين السمات السريرية والمرضية. أيضاً، اظهرت نتائج الصور في هذه الدراسة عن تعبير غشائي سلبي ل CD47 (النتيجة 0)، وتعبير غشائي قوي ل CD47 (النتيجة 8)، وتعبير غشائي معتدل ل CD47 (النتيجة 7)، وتعبير غشائي ضعيف ل CD47 (النتيجة 4). **الاستنتاجات:** اظهرت الدراسة الحالية تعبيراً عالياً ل CD47 في المرضى الذين يعانون من سرطان القولون والمستقيم، مما يسمح للخلايا السرطانية بالتحكم بالإشارات المثبطة ل CD47-SIRP α وتجنب هجوم الخلايا المناعية.

مفتاح الكلمات: سرطان القولون والمستقيم، مجموعة التمايز 47، الكيمياء المناعية النسيجية، البروتين المرتبط بالإنترغرين