

# Does the local Application of Platelet-Rich Plasma Reduce Hemorrhage after Tonsillectomy? A Comparative Study

Ahmed M. Rasheed<sup>1</sup>  <sup>1</sup>Dept. of Surgery-Otolaryngology, College of Medicine, University of Baghdad, Baghdad, Iraq.

©2024 The Author(s). Published by College of Medicine, University of Baghdad. This open-access article is distributed under the terms of the Creative Commons Attribution 4.0 International License, which permits unrestricted use, distribution, and reproduction in any medium, provided the original work is properly cited.

## Abstract:

**Background:** Tonsillectomy is one of the most common surgical operations in otolaryngology, post-tonsillectomy hemorrhage is a dangerous complication. Several methods have been used to decrease the rate of post-tonsillectomy hemorrhage, one of these methods; which is a relatively recent method, is local application of platelet-rich plasma (PRP) to the tonsillar beds.

**Objectives:** To evaluate the role of local application of autologous PRP to the tonsillar beds, at the time of tonsillectomy, in post-tonsillectomy hemorrhage.

**Methods:** A prospective comparative study enrolled 64 patients with ages ranging from 6 to 10 years who underwent tonsillectomy with or without adenoidectomy. In each patient, PRP was applied at the time of tonsillectomy to one tonsillar bed (PRP side), while the other side was used as a control side. So, the total sides were 128 (64 PRP and 64 control sides). The patients were followed-up for 10 days and the outcome measure was the occurrence of post-tonsillectomy hemorrhage on the PRP side versus the control side. The association between the variables was established using chi-square test ( $X^2$ -test).

**Results:** Thirty-eight patients (59.4%) were males and twenty-six patients (40.6%) were females. Adenotonsillectomy was performed in 35 patients (54.7%), while 29 patients (45.3%) underwent tonsillectomy alone. There was no post-operative hemorrhage from the adenoid beds. Post-tonsillectomy hemorrhage occurred in 1 patient (1.6%) on the PRP side and 3 patients (4.7%) on the control side ( $P$ -value=0.31).

**Conclusions:** The local application of autologous PRP to the tonsillar bed only once, at the time of tonsillectomy, is not significantly effective in reducing post-tonsillectomy hemorrhage.

**Keywords:** Post-tonsillectomy hemorrhage; Tonsillectomy; topical application of platelet-rich plasma.

Received: Jun. 2023

Revised: July 2023

Accepted: July, 2023

Published: Oct. 2023

## Introduction:

Tonsillectomy is one of the most common surgical procedures in otolaryngology practice. (1) It is the most common operation for recurrent tonsillitis and obstructive sleep apnea due to tonsillar enlargement in children. (2) Unfortunately, tonsillectomy is often associated with significant post-operative pain and about 4% risk of post-tonsillectomy bleeding. (3,4) One of the most common complications of tonsillectomy is post-operative hemorrhage. Post-tonsillectomy hemorrhage usually requires re-admission to the hospital, it can result in significant morbidity including the need for blood transfusion, shock, and airway obstruction. The post-operative hemorrhage in tonsillar surgeries is considered as the most serious complication, it is classified into primary hemorrhage within 24 hours of surgery and secondary hemorrhage after the first 24 hours. (5, 6) Platelet-rich plasma (PRP) is a concentrated volume of platelets that contain multiple growth and healing factors. (7, 8) PRP can be used as an adjuvant therapy to accelerate the healing of surgical wounds

in several clinical situations. (9, 10) The local application of PRP to decrease post-tonsillectomy complications is gaining importance. A randomized controlled trial conducted by Nanditha et al. and a systematic review and meta-analysis of seven randomized controlled trials conducted by Albazee et al. to study the effects of PRP on post-tonsillectomy complications have been published recently. (11, 12) The current study was conducted to evaluate the effect of autologous PRP application on the tonsillar bed, at the time of tonsillectomy, on a post-tonsillectomy hemorrhage. After tonsillectomy, the PRP is applied locally to one tonsillar bed (test side), and the other bed is left without PRP application (control side), then a comparison is made between both sides regarding the occurrence of post-tonsillectomy hemorrhage.

## Patients and methods

The current prospective comparative study was conducted at Al-Alloys Private Hospital in Baghdad, Iraq, for the period from January 2021 to March 2023.

\*Corresponding

[ahmed.muhei@comed.uobaghdad.edu.iq](mailto:ahmed.muhei@comed.uobaghdad.edu.iq).

Author:

The Local Health Ethics Committee in the College of Medicine, University of Baghdad granted the study clearance. After explaining the nature of the study, informed written consent was obtained from the parents/guardians of the patients.

After taking history and performing a routine ear, nose, and throat examination, 64 patients, who attended the private clinic, with an age range from 6 to 10 years admitted for tonsillectomy alone or adenotonsillectomy due to recurrent tonsillitis and/or obstructive sleep apnoea were included in this study. The study was single-blinded; the patients /family members did not know the tested side. Each patient was given a code number; the tested side was the right side in patients with an odd number, while the left side was the tested side in patients with even numbers. PRP was applied on one side "test side"; at the time of tonsillectomy, and the other side was used as a control. The total number was 64 patients; 128 sides (64 control sides and 64 test sides, with 32 right sides and 32 left sides for each group). Patients with bleeding-related diseases were excluded from the study.

Ten milliliters of autologous blood were drawn from the patient mixed with 1ml of anticoagulant (citrate phosphate dextrose adenine) during induction of anesthesia and was processed while performing tonsillectomy using a laboratory centrifuge (Heraeus Labofuge 200, Germany). "The double-spin open method was used to prepare the PRP. Centrifugation of blood was achieved in 2 sessions, the first one (soft spin: speed of 3000 rpm; 704g ×3 minutes) allows the blood to be separated into 3 layers: bottom-most RBCs layer, the top-most acellular plasma layer which is called platelet-poor plasma (PPP) and the intermediate PRP layer. The PPP, PRP, and some RBCs were transferred into another tube which will undergo a second centrifugation (hard spin: speed of 4000 rpm; 1252g×15 minutes) which is faster and longer than the first spin. The platelets would settle at the bottom of the tube with a few RBCs."(13, 14)

An oral endotracheal tube was used to deliver general anesthesia. The patient was placed in the supine position and adenoidectomy was done by curate (in patients who underwent adenotonsillectomy). Tonsillectomy was performed using the dissection technique, the neck was extended by placing a sandbag beneath the shoulders, and hemostasis was stabilized by ligations (Figure 1). The PRP was applied, using a syringe, on one tonsillar bed "test side"; at the time of tonsillectomy, and the other side was used as a control. Precautions taken to avoid rapid wash out of PRP from the tonsillar beds included no washing of the oropharynx and no suction applied to the tonsillar beds after the application of PRP.

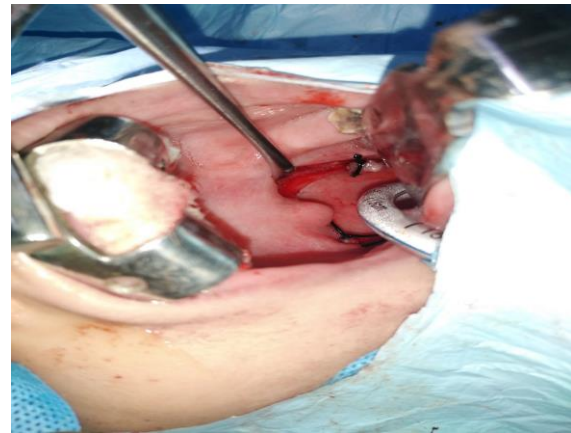


Figure 1. Tonsillectomy in a 7-year-old boy.

The patients were discharged on the day of surgery (after 6 hours). Instructions were given to the medical caregivers and the patient's family to contact the investigator through the provided phone number, if the patient was spitting up blood, if vomiting occurs containing blood or if any other complications occur. In case of spitting up blood or vomiting blood, the patient is admitted to the hospital to be examined to ensure that bleeding has occurred and is classified as post-tonsillectomy hemorrhage. Post-operative management included 5ml of 250mg/5ml paracetamol syrup adjusted according to the clinical situation of the patient; up to four doses/day, and amoxicillin-clavulanic acid 40mg/kg/day in two divided doses. The patients were encouraged to eat a normal diet. The follow-up of the patients was achieved on the 1st, 5th, and 10th postoperative days. A phone number has been given to the patient's family to contact the investigator in the event of an emergency.

The data was managed using the Statistical Package for Social Sciences (SPSS) version 23. The association between the categorical variables was tested using the Chi-square test ( $\chi^2$ -test). The 95% confidence level was assigned and a 5% margin of error was accepted.  $P$ -value  $< 0.001$  was considered highly significant and  $P$ -value  $< 0.05$  was considered significant. Power analysis was done using G power software, the significance level ( $\alpha$ ) was 0.05 and the power was 0.8 with a minimal effect.

## Results

Sixty-four patients with an age range of 6-10 years (Mean±SD=7.88±1.35) of whom 38 patients (59.4%) were males and 26 patients (40.6%) were females, were included in this study.

Adenotonsillectomy was performed in 35 patients (54.7%), while 29 patients (45.3%) underwent tonsillectomy alone. The performance of adenoidectomy did not affect the results of post-tonsillectomy hemorrhage in both sides ( $\chi^2=0$ ,  $P$ -value=1). There was no post-operative hemorrhage from the adenoid beds.

Regarding post-tonsillectomy hemorrhage, which was secondary hemorrhage on both PRP and control

sides, it occurred in one patient (1.6%) on the PRP side, while three patients (4.7%) suffered from bleeding on the control side as shown in Table 1. The post-tonsillectomy hemorrhage in the four patients was minor. They were admitted to the hospital for monitoring of the heart rate, respiratory rate, blood pressure, and pulse oximetry. The conservative treatment also included suction of the clot (if present), hydrogen peroxide gargles (1-3 dilution), adrenaline (1:10000) applied to the bleeding point, and antibiotics.

Statistical analysis showed that there was no significant difference between the PRP and the control sides concerning the occurrence of post-tonsillectomy hemorrhage ( $X^2=1.032$ ,  $P$ -value=0.31), Table 1.

**Table 1. Comparison between PRP side and control side regarding bleeding.**

Bleeding	PRP side (number=64 sides)		Control side (number=64 sides)		Total Sides
	Post-operative day		Post-operative day		
Yes	1 (1.6%)	6th day	3 (4.7%)	6th & 7th days	4
NO	63 (98.4%)		61 (95.3%)		124
$X^2=1.032$ , $P$ -value=0.31					128

**Discussion**

The rates of secondary hemorrhage revealed in the current study did not exceed the 1% to 5% risk of post-operative bleeding reported in the literature. (15,16) The need for surgical intervention in post-tonsillectomy hemorrhage depends on the physical findings and the surgeon’s experience. (17) However, operative control is needed in 0.2-5.7% of children suffering from post-tonsillectomy hemorrhage. (18,19)

Many topical biomaterials have been tried to prevent post-tonsillectomy hemorrhage such as fibrin-based, cellulose-based, and gelatin-based biomaterials. "The biomaterial is expected to facilitate hemostasis by improving coagulation and clot formation, stabilize the clot, improve wound healing and remucosalization, and provide a physical barrier for the duration of the wound healing process".(20) PRP is now widely used to promote wound healing with a satisfactory outcome in various clinical conditions. However, the use of PRP in otolaryngology is not yet common. The investigations on PRP in wound healing have risen sharply in recent years and are being used more and more frequently in many surgical specialties, it has been used for the treatment of chronic skin and soft tissue ulcers, in orthopedics surgery, and in tonsillectomy. (21-24) a randomized controlled study conducted by Nanditha et al enrolled 56 patients, in which patients were allocated to two groups, a peri-operative PRP intervention group, and a control group. They concluded that the local application of PRP was significantly effective in accentuating healing and

reducing post-tonsillectomy pain and morbidity. (11) The main advantage of PRP is that it is an autologous material. PRP is particularly interesting to otolaryngologists because of its healing properties. (21, 24)

The current study has investigated the role of the local application of PRP to the tonsillar beds, at the time of tonsillectomy, in reducing post-tonsillectomy hemorrhage. The results revealed that the bleeding rate on the PRP side was lower than the bleeding on the control side, but not significantly so. This result may be due to the rapid slough of the PRP from the tonsillar beds and not staying in contact with the raw tissue for a sufficient time. Moreover, the application of PRP was done only once at the time of tonsillectomy.

Salah Eldin, et al in a randomized single-blinded study on 38 patients admitted for tonsillectomy, found that the rate of postoperative bleeding was 2.6% on the PRP side and 10.5% on the control side. They concluded that the local application of PRP to the tonsillar beds at the time of tonsillectomy did not have an effective role in significantly reducing post-tonsillectomy bleeding. (10) Similarly, in a study conducted by Saad et al on 40 children who underwent tonsillectomy or adenotonsillectomy, there was no bleeding in the PRP group, with only one patient in the control group suffering from bleeding. Again, the difference between the two groups was not significant. They concluded that the local application of PRP to the tonsillar beds is not useful for ameliorating post-tonsillectomy bleeding. (25) On the other hand, a randomized controlled study performed by Kutuk et al on 80 pediatric tonsillectomy patients, revealed that tonsillectomy with PRP was superior to tonsillectomy alone in terms of reducing the risk of post-tonsillectomy bleeding during the first 10 postoperative days.(26) A similar result was reported by Chettri et al.(27) A recent systematic meta-analysis of seven randomized controlled trials, conducted by Albazee et al., concluded that the rate of post-tonsillectomy hemorrhage was significantly reduced in favor of the PRP groups compared with the control groups. (14) However, the effect of PRP on post-tonsillectomy hemorrhage has not been adequately studied. Its influence on post-tonsillectomy hemorrhage severity and morbidity needs to be verified with more clinical studies. (19)

**Conclusions**

The local application of autologous PRP to the tonsillar bed only once, at the time of tonsillectomy, was not found to significantly reduce post-tonsillectomy hemorrhage.

**Authors’ Declaration:**

I hereby confirm that all the Figures and Tables in the manuscript are mine. Besides, the Figures and images, which are not mine, have been given permission for re-publication attached to the manuscript. Author sign on ethical consideration’s



**Approval-Ethical Clearance:** The project was approved by the local ethical committee in the College of Medicine, University of Baghdad according to the code number (137-14/12/2020).

**Conflicts of Interest:** None.

**Funding:** None

## References

1. Nunez D.A., Provan J, Crawford M. Post-operative tonsillectomy pain in pediatric patients. *Arch Otolaryngology Head and Neck Surg.* 2000; 126:837-41. <https://doi.org/10.1001/archotol.126.7.837>.
2. Ding XX, Zhao LQ, Cui XG, Yin Y, Yang HA. Clinical observation of softpalate-pharyngoplasty in the treatment of obstructive sleep apnea hypopnea syndrome in children. *World J Clin Cases.* 2020; 8:679-88. <https://doi.org/10.12998/wjcc.v8.i4.679>.
3. Østvoll E, Sunnergren O, Stalfors J. Increasing Readmission Rates for Hemorrhage after Tonsil Surgery: A Longitudinal (26 Years) National Study. *Otolaryngol Head Neck Surg.* 2018; 158:167-76. <https://doi.org/10.1177/0194599817725680>.
4. Sakki A, Mäkinen LK, Roine RP, Nokso-Koivisto J. Changing trends in pediatric tonsil surgery. *Int J Pediatr Otorhinolaryngol.* 2019; 118:84-89. <https://doi.org/10.1016/j.ijporl.2018.12.028>.
5. Tomkinson A, Harrison W, Owen D, Harris S, McClure V, Temple M. Risk factors for postoperative hemorrhage following tonsillectomy. *Laryngoscope.* 2011; 121:279-88. <https://doi.org/10.1002/lary.21242>.
6. Attner P, Haraldsson PO, Hemlin C, Hessen Soderman AC. A 4-year consecutive study of post-tonsillectomy hemorrhage- ORL J Otorhinolaryngol Relat Spec. 2009; 71:273-78. <https://doi.org/10.1159/000245160>.
7. Sanchez AR, Sheridan PJ, Kuppli LI. Is platelet-rich plasma the perfect enhancement factor? A Current Review. *International Journal of Oral & Maxillofacial Implants.* 2003; 18(1):93-103. PMID: 12608674
8. Man D, Plosker H, Winland-Brown J. The use of autologous platelet-rich plasma and autologous platelet-poor plasma in cosmetic surgery. *Plast Reconstr.* 2001; 107:229-37. <https://doi.org/10.1097/00006534-200101000-00037>.
9. Fernandez-Moure JS, Van Eps JL, Cabrera FG, Barbosa Z, Del Rosal GM, Weiner BK, et al. Platelet-rich plasma: A biomimetic approach to enhancement of surgical wound healing. *J Surg Res.* 2017; 207:33-44. <https://doi.org/10.1016/j.jss.2016.08.063>.
10. Salah Eldin AHS. Role of platelet-rich plasma to decrease post-tonsillectomy pain and bleeding. *The Medical Journal of Cairo University.* 2011; 175-78.
11. Nanditha S, Gopalakrishnan S, Karthikeyan P, Bakshi SS. Efficacy of topical application of autologous platelet-rich plasma in adult tonsillectomy patients: a randomized control study. *The Journal of Laryngology & Otolaryngology.* 2021; 135(6):539-44. <https://doi.org/10.1017/S0022215121000402>.
12. Albazee E, Diab S, Awad AK, Aboeldahab H, Abdella WS, Abu-Zaid A. The analgesic and anti-hemorrhagic effect of platelet-rich plasma in tonsillectomy: a systematic review and meta-analysis of randomized controlled trials. *Clinical Otolaryngology.* 2023; 48(1):1-9. <https://doi.org/10.1111/coa.13977>.
13. Eby BW. Platelet-rich plasma harvesting with a single spin centrifuge. *J Oral Implant.* 2002 [https://doi.org/10.1563/1548-1336\(2002\)028<0297:PPHWAS>2.3.CO;2](https://doi.org/10.1563/1548-1336(2002)028<0297:PPHWAS>2.3.CO;2)
14. Sonnleitner D, Huemer P, Sullivan DY. A simplified technique for producing platelet-rich plasma and platelet concentrate for intraoral bone grafting: A technical note. *Int J Oral Maxillofacial Implant.* 2000; 15:879-82. PMID: 11151589.
15. Krishna P, Lee D. Post-tonsillectomy bleeding: A meta-analysis. *Laryngoscope.* 2001; 111:1358-61. Doi: 10.1097/00005537-200108000-00008. PMID: 11568568 <https://doi.org/10.1097/00005537-200108000-00008>.
16. Theilgaard SA, Nielson HU, Siim C. Risk of hemorrhage after outpatient versus inpatient tonsillectomy. *Ugeskrift for Laeger.* 2001; 163:5002-5. PMID: 11573376
17. Clark CM, Schubart JR, Carr MM. Trends in the management of post-tonsillectomy hemorrhage in children. *Int J Pediatr Otorhinolaryngol.* 2018; 108:196-201. doi: 10.1016/j.ijporl.2018.03.004. PMID: 29605354 <https://doi.org/10.1016/j.ijporl.2018.03.004>.
18. Tolska HK, Takala AJ, Jero J. Peritonsillar infiltration of lidocaine with adrenaline is associated with increased risk of secondary post-tonsillectomy haemorrhage. *J Laryngol Otol.* 2018; 132:911-22. <https://doi.org/10.1017/S0022215118001731>.
19. Morris S, Hassin E, Borschmann M. Overnight in-hospital observation following tonsillectomy: retrospective study of post-operative intervention. *J Laryngol Otol.* 2018; 132:46-52. doi: 10.1017/S0022215117002171. PMID: 29103384 <https://doi.org/10.1017/S0022215117002171>.
20. Liu L, Rodman C, Worobetz NE, Johnson J, Elmaraghy C, Chiang T. Topical biomaterials to prevent post-tonsillectomy hemorrhage. *J Otolaryngol Head Neck Surg.* 2019; 48(1):45. <https://doi.org/10.1186/s40463-019-0368-1> <https://doi.org/10.1186/s40463-019-0368-1>.
21. Suthar M, Gupta S, Bukhari S, Ponemone V. Treatment of chronic non-healing ulcers using autologous platelet rich plasma: a case series. *J Biomed Sci.* 2017; 24: 16. <https://doi.org/10.1186/s12929-017-0324-1> <https://doi.org/10.1186/s12929-017-0324-1>.
22. Lana JFSD, Santana MHA, Belangero WD, Luzo ACM. Platelet-Rich Plasma - Regenerative Medicine: Sports Medicine, Orthopedic, and

Recovery of Musculoskeletal Injuries. 2014. <https://www.springer.com/gp/book/9783642401169> <https://doi.org/10.1007/978-3-642-40117-6>.

23. Mohammed S, Yu J. Platelet-rich plasma injections: an emerging therapy for chronic discogenic low back pain. *J Spine Surg.* 2018 Mar; 4(1):115-22. doi: 10.21037/jss.2018.03.04. PMID: 29732431; PMCID: PMC5911760 <https://doi.org/10.21037/jss.2018.03.04>.

24. Srinivasa V, Muthu Ramanathan AN, Nanditha S, Sandravelu T, Dharshana G, Ajmal A. Role of platelet-rich plasma in post-tonsillectomy pain. *European Journal of Molecular & Clinical Medicine.* 2023;10(1):162-71.

25. Saad HAE, Mandour MF, Behery AS, Sheleb WA. Determining the impact of platelet-rich plasma on short-term postoperative outcomes of pediatric tonsillectomy patients in Egypt. *Journal of Advances*

*in Medicine and Medical Research.* 2021; 33(22):1-7. DOI:<https://doi.org/10.9734/jammr/2021/v33i2231153>.

26. Kutuk SG, Ozdas T. The impact of platelet-rich plasma therapy on short-term postoperative outcomes of pediatric tonsillectomy patients. *European Archives of Oto-Rhino-Laryngology.* 2019; 276:489-95. <https://doi.org/10.1007/s00405-018-5211-1>.

27. Chettri M, Jayagandhi S, Konyak Y, Sobita P, Singh M, Singh A. Hemostasis and analgesia with autologous platelet-rich plasma in tonsillectomy. *The Journal of Laryngology & Otology.* 2019; 133(7):615-21. <https://doi.org/10.1017/S0022215119001488>.

#### How to cite this Article

Rasheed AM. Does the local application of Platelet-Rich Plasma Reduce Hemorrhage after Tonsillectomy? A Comparative Study. *JFacMedBagdad* [Internet]. Available from: <https://ijjmc.uobaghdad.edu.iq/index.php/19JFacMedBaghdad36/article/view/2153>

## هل التطبيق الموضعي للبلازما الغنية بالصفائح الدموية يقلل من النزيف بعد استئصال اللوزتين؟ دراسة مقارنة

الاستاذ المساعد الدكتور احمد محي رشيد -شعبة الانف و الاذن و الحنجرة- فرع الجراحة كلية الطب جامعة بغداد

### الخلاصة

**الخلفية:** يعتبر استئصال اللوزتين من أكثر العمليات الجراحية شيوعاً في طب و جراحة الأنف والأذن والحنجرة ، ويعتبر نزيف ما بعد استئصال اللوزتين من المضاعفات الخطيرة. تم استخدام عدة طرائق لتقليل معدل نزيف ما بعد استئصال اللوزتين ، إحدى هذه الطرائق ؛ وهي طريقة حديثة نسبياً ، هي التطبيق المحلي للبلازما الغنية بالصفائح الدموية (PRP) على قاع اللوزتين.

**هدف الدراسة:** تقييم دور التطبيق المحلي للبلازما الغنية بالصفائح الدموية على قاع اللوزتين ، في وقت استئصال اللوزتين ، في نزيف ما بعد استئصال اللوزتين.

**المرضى والطرائق:** دراسة مقارنة مستقبلية مسجلة على 64 مريضاً تتراوح أعمارهم من 6 إلى 10 سنوات خضعوا لاستئصال اللوزتين مع أو بدون استئصال الغدانيان. في كل مريض ، تم تطبيق PRP في وقت استئصال اللوزتين على جانب واحد (جانب PRP) ، بينما تم استخدام الجانب الآخر كجانب تحكم. لذلك ، كان إجمالي الجوانب 128 جانباً (64 جانباً لل PRP و 64 جانب تحكم). تمت متابعة المرضى لمدة 10 أيام وكان قياس النتيجة حدوث نزيف ما بعد استئصال اللوزتين على جانب PRP مقابل جانب التحكم. تم فحص الارتباط بين المتغيرات باستخدام اختبار مربع كاي (اختبار X<sup>2</sup>).

**النتائج:** حدث نزيف ما بعد استئصال اللوزتين في مريض واحد (1.6%) على جانب البلازما الغنية بالصفائح الدموية و 3 مرضى (4.7%) في جانب التحكم (قيمة الاحتمال = 0.31).

**الاستنتاجات:** إن التطبيق المحلي للبلازما الغنية بالصفائح الدموية على قاع اللوزتين مرة واحدة فقط ، في وقت استئصال اللوزتين ، ليس فعالاً بشكل كبير في الحد من نزيف ما بعد استئصال اللوزتين.

**الكلمات الرئيسية:** استئصال اللوزتين؛ نزيف ما بعد استئصال اللوزتين. التطبيق الموضعي للبلازما الغنية بالصفائح الدموية.