

# Traumatic Haemothorax: Diagnostic approaches and surgical management

DOI: <https://doi.org/10.32007/jfacmedbagdad.6421889>.

Waleed M. Hussen\*

Ahmed Noureldin Abdulkadir\*\*

Akeel S. Yuser\*\*\*

FIBMS (Th.C.V.S). FACS, MRCS, .FRCS (Glasgow)

FIBMS (Th.C.V.S)

FIBMS (Th.C.V.S)



This work is licensed under a [Creative Commons Attribution-NonCommercial 4.0 International License](https://creativecommons.org/licenses/by-nc/4.0/).

## Abstract:

**Background:** Traumatic haemothorax is a collection of blood within the pleural cavity due to a penetrating or blunt injury leading to blood accumulation inside the pleural space with its respiratory and hemodynamic consequences.

**Objectives:** Is to retrospectively study eighty victims of traumatic haemothorax regarding their age, gender, types of injury, and their sequel, as well as the methods of investigation, treatment modality (conservative or operative) and their outcome.

**Patients and methods:** The data of 80 patients with traumatic haemothorax admitted to Ibn AL-Nafees teaching hospital from (1st of August 2018 to 30th. of September 2019), was collected. The data was analyzed according to age, gender, clinical features, associated findings, mechanism of injury, imaging, procedure performed, operative finding, post-operative outcome, morbidity, mortality and follow up.

**Result:** Seventy-four (92.5%) of our patients were males, and 32 (40%) were between 21-30 year of age. Fifty-four patients (67.5%) were injured by bullet, stab or shell injury. The remaining 26 patients (32.5%) were affected by blunt injury. Sixty patients (75%) were treated successfully with tube thoracostomy only. Eight patients (10%) required emergency thoracotomy after the insertion of chest tube, ten patients (12.5%) needed elective thoracotomy for (clotted haemothorax, foreign body extraction or empyema), and the remaining two patients (2.5%) presented with minimal haemothorax and didn't need any intervention. Sixty-two of our patients (77.5%) were discharged well within 7 days. Those with air leak or who needed thoracotomy (elective or emergency) had longer hospitalization periods. Only one patient with empyema needed to stay more than 30 days. Sixty-nine (86.3%) of our patients were discharged well, while complication occurred in three patients (3.8%) with air leak, two (2.5%) ended with empyema and four patients (5%) with clotted haemothorax. Two patients (2.5%) died due to sever uncontrolled bleeding.

**Conclusion:** Most of the patients with traumatic haemothorax were simply managed by tube thoracostomy only. In haemodynamically unstable patients, no time should be wasted for investigations and a resuscitative thoracotomy can save the patient's life. Rapid assessment and early intervention will save the life of patient with traumatic haemothorax.

**Keywords:** Chest trauma, Chest tube thoracostomy, Emergency thoracotomy, Clotted haemothorax

## Introduction:

Traumatic haemothorax is the collection of blood within the pleural cavity due to penetrating or blunt injury leading to blood accumulation inside the pleural space with its respiratory and hemodynamic consequences [1].

In 1794 several surgeons, including John Hunter advocated the creation of an intercostal incision and drainage of the haemothorax. By the 18th century, some treatment for haemothorax was available. Early haemothorax evacuation by trocar and cannula or by intercostal incision was considered standard practice in early 1870, and then underwater seal drainage was described by several different physicians. This basic technique has remained the most common form of treatment for haemothorax and other pleural fluid collections to this day [2]. The most common causes of haemothorax are the penetrating injuries of the lungs, heart, great vessels, or chest wall. They may be accidental, deliberate, or iatrogenic in origin. In particular, central venous catheter and thoracostomy

\* Correspondence Author: College of Medicine, University of Baghdad and Medical City Teaching Complex. Email: [dr\\_waleedmustafa@yahoo.com](mailto:dr_waleedmustafa@yahoo.com)

\*\* Specialist Thoracic and Vascular Surgeon, Azadi Teaching Hospital, Kirkuk. Iraq. [ahmednoureldin1988@gmail.com](mailto:ahmednoureldin1988@gmail.com)

\*\*\* Consultant Thoracic and Vascular Surgeons, Ibn Al-Nafees Teaching Hospital, [drakeelsy@yahoo.com](mailto:drakeelsy@yahoo.com).

tube placement are cited as primary iatrogenic causes [3, 4, and 5]. Haemothorax can be occasionally due to blunt trauma leading to laceration of the internal vessels [6].

Blood into the pleural space may be due to extra pleural injury, which leads to traumatic disruption of the chest wall tissues with violation of the pleural membrane can cause bleeding into the pleural cavity, the intercostal and internal mammary arteries are the most likely sources of significant or persistent bleeding from chest wall injuries [2], or intrapleural injury by blunt or penetrating injury involving any intrathoracic structure can result in haemothorax. Massive haemothorax may result from injury to major arterial or venous structures contained within the thorax or from the heart itself. (2-7).

Hemodynamic changes vary, according to the amount of bleeding and the rapidity of blood loss. Exsanguinating hemorrhage can occur without external evidence of blood loss [4]. Abnormalities of ventilation and oxygenation may result, especially if associated with injuries to the chest wall. A large enough collection of blood causes the patient to experience dyspnea and tachypnea [8].

Deformation of the blood may occur so that incomplete clotting occurs. Within several hours of cessation of bleeding, lysis of existing clots by pleural enzymes begins [4]. Two pathologic states are associated with the later stages of haemothorax: empyema and fibrothorax, which traps the lung in position and prevents it from expanding fully [9].

Depending on the severity of the injury, the patient may have dyspnea, restlessness, thirst and chills, with clinical evidences of penetrating injury wounds on the affected side. Chest wall bruises or laceration, reduced chest expansion on the affected side, collapsed neck veins, diminished breath sound on the affected side with tachycardia and hypotension [10,11]. The ideal primary diagnostic study in the evaluation of haemothorax is the chest X-ray. Ultrasonography, echo and computed tomography (CT) of the chest, may sometimes be required for accurate evaluation of the haemothorax [12]. CT does not play a primary role in the diagnosis of haemothorax in the trauma setting, but is complementary to chest X-ray. Currently, CT is of the greatest value later in the management of the chest trauma patient, for precise localization and quantification of any retained collections of clots within the pleural cavity [13, 14].

For the management, tube thoracostomy is indicated if the haemothorax is large enough to obscure the costophrenic angle on the chest X-ray or if it is associated with a pneumothorax.

Surgical exploration should be performed in the following circumstances:

- 1-Drainage of more than 1500 ml of blood immediately after tube thoracostomy.
- 2-Continuous bleeding through the chest tube, defined as 150-200 ml/hr. for 2-4 hours.

3- Blood transfusion is required repeatedly to maintain hemodynamic stability.

When thoracotomy is performed, the source of bleeding is controlled and the haemothorax is evacuated.

Later in the course of treating the haemothorax, residual clots, infected collections, and trapped lung, require additional treatment and, most often, surgical intervention [15]. Several centers have used Video-assisted thoracoscopic surgery (VATS), which is an alternative treatment that permits direct removal of clots and precise placement of chest tubes. It can successfully identify and control the source of bleeding. VATS is associated with fewer postoperative complications and shorter hospital stays [16].

The prognosis of patients with traumatic haemothorax is generally good. Mortality is directly related to the nature and severity of the injury. Morbidity is also related to these factors and to the risks related to retained haemothorax, namely empyema and fibrothorax (trapped lung) [17-18].

#### Patients and methods:

A retrospective review of the records of 80 patients admitted to Ibn Al-Nafees teaching hospital with traumatic haemothorax, during the period from (1st of August 2018 to 30th of September 2019).

**Exclusion criteria:** Non-traumatic haemothorax (hemorrhagic effusion) and multiple injured patients (associated head and abdominal injuries) were excluded.

**Study design:** Patients' data was collected from patients' record and surgical notes and analyzed based on their age, gender, presenting features, associated findings, and mechanism of injury, imaging, procedure performed, operative findings, post operative outcome, morbidity, mortality and follow up.

**Methods:** The following therapeutic Procedures were used

1. *Conservative:* Two patients were managed conservatively with follow up by chest x-ray or CT-chest which revealed minimal haemothorax.

2. *Chest tube thoracostomy*[a1]: Large size (usually 36-French) was used to achieve adequate drainage. Smaller sizes were used in pediatric patients. Under sterile conditions, the insertion site was infiltrated with a local anesthetic. The chest tube was inserted in the safe triangle (formed anteriorly by the lateral border of the pectoralis major, laterally by the anterior border of the latissimus dorsi, inferiorly by the line of the 5th intercostal space or superior border of the nipple in male patients, and superiorly by the base of the axilla).. Chest radiograph was done in stable patients, to identify chest tube position, and helps determine complete haemothorax evacuation

3. *Surgery:* Eight patients needed emergency thoracotomy, all of whom were victims of penetrating injury and ten patients required elective thoracotomy. The decision to perform thoracotomy was based on several factors, including the volume and persistence of

blood loss. Volume resuscitation should be performed according to Advanced Trauma Life Support (ATLS) protocol and should be continued to the operating room. Intravenous antibiotics were administered before emergency exploration. Maintaining normal body temperature is extremely important to prevent complications such as cardiac arrhythmias and coagulopathy.

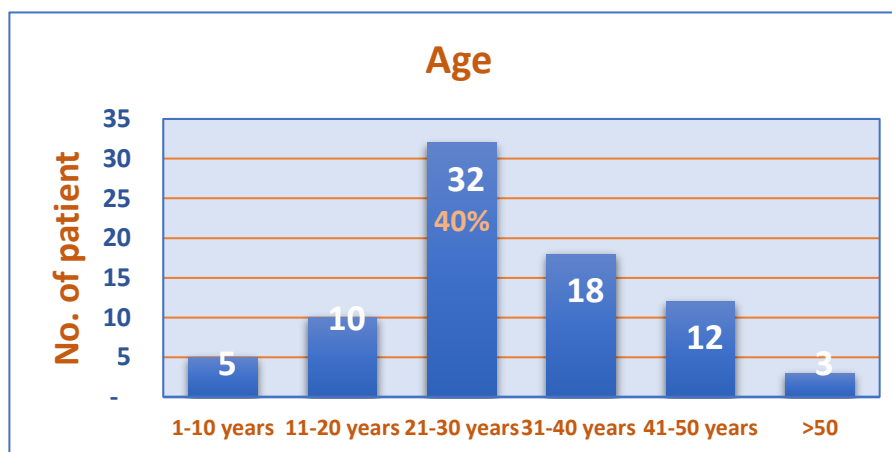
Posterolateral thoracotomy was used in six patients in need for emergency thoracotomy and in ten patients in need for elective thoracotomy. The patient is positioned in the lateral decubitus; the skin incision is started at the level of the anterior axillary line over the fifth or sixth intercostal space. It is gently curved around the tip of the scapula and continued posteriorly along a line between the medial aspect of the scapula and the spine. The latissimus dorsi is first opened; then, the serratus anterior muscle is spared. Pulmonary resections are mostly done through the fifth intercostal space. Access to the pleural space is completed by opening the endothoracic fascia and parietal pleura. While anterolateral thoracotomy was performed in two patients with left sided haemothorax and haemodynamically unstable upon the anterior chest

wall 4th or 5th intercostal space incision made from anterior axillary line to the sternum. Before closing and after control of obvious bleeding and evacuation of clot and blood, a thorough exploration of the entire chest cavity performed. Unstable rib fractures were stabilized with stainless steel wires to prevent further rib injury to the lung or adjacent chest wall structures. Two chest tubes were inserted, one positioned posteriorly and the other positioned anteriorly.

**Data collection:** A data collection form was used, and data was analyzed according to age, gender, mechanism of injury, lab investigations, methods of intervention, outcome, associated findings, hospitalization period and thoracotomy findings.

### Results:

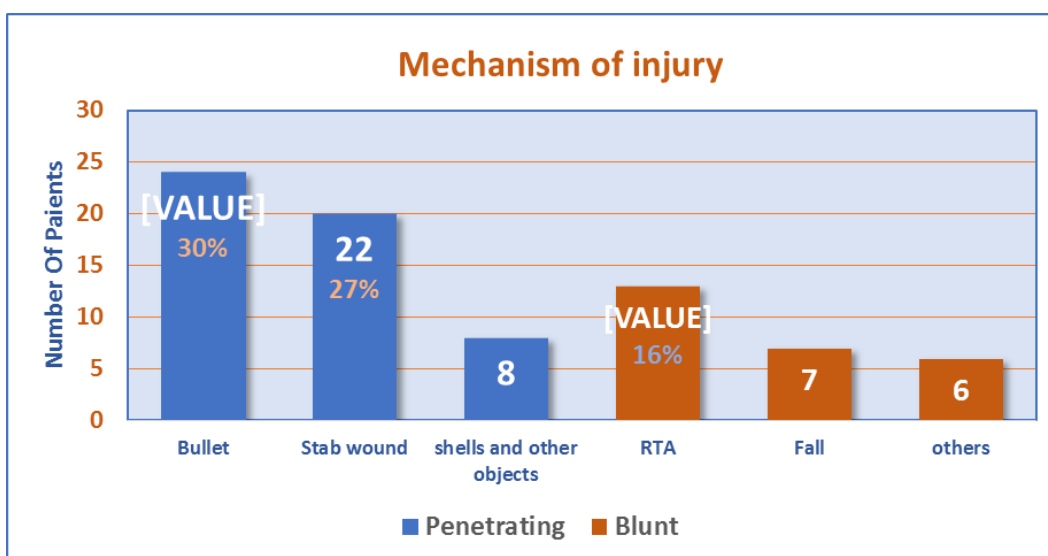
Seventy-four of our patients with traumatic haemothorax were males constituting (92.5%) and the remaining six were females (7.5%), with a male: female ratio of 11.3:1. A two- years old boy was the youngest patient, while the oldest was a 64-years-old man. Thirty- two of our patients (40%) fall between 21 - 30 years age group, with a mean age of 33 years. The age distribution of our patients is shown in figure (1)



**Figure 1:** Age distribution of the study group with traumatic haemothorax

The mechanism of injury was penetrating in 54 patients (67.5%) and blunt in 26 (32.5%) patients. Of those with penetrating injury, 24 patients (30%) were bullet

injuries, and 22 (27.5%) patients were stab wounds. As for blunt injuries 13 (16.3%) were due to road traffic accidents (RTA) as shown in figure (2).



**Figure 2: Distribution of the causes of trauma in the haemothorax study group**

Routine blood investigations and chest x-ray were done for 79 patients as diagnostic or follow up investigations. Twenty-two patients (27.5%) required CT-chest for preoperative assessment in complicated cases or during visit. Fourteen patients (17.5%) required ultra-sound (US) for the chest to evaluate residual collection and only two cases needed bronchoscopy. Only one patient was haemodynamically unstable and was transferred to the operation room urgently without laboratory studies or chest x-ray. Sixty patients (75%) were treated successfully with tube thoracostomy only and required no further therapy. Eight (10%) cases needed emergency thoracotomy after the insertion of the chest tube, and 10 (12%) needed further surgical intervention later on (4 retained haemothorax, 4 foreign body extraction and 2 empyema). The remaining two patients were conservatively managed with very mild haemothorax as shown in table 1.

**Table 1: Investigations done to and management procedures for patients with traumatic haemothorax.**

Investigations	No.	Percentage
Lab studies	79	98
Chest x-ray	79	98
CT-scan	22	27
Ultrasound	14	17
Bronchoscopy	2	2.5
Procedures	No.	Percentage
Tube thoracostomy only	60	75.0
Elective Thoracotomy	10	12.5
Emergency Thoracotomy	8	10.0
Conservative	2	2.5
Total	80	100.0

Eight (10%) patients with traumatic haemothorax required emergency thoracotomy; four cases had extensive parenchymal laceration, three cases with

chest wall and intercostal vessels injury and one case with right pulmonary vein and parenchymal injury. Isolated unilateral haemothorax was found in 25 (31.3%) patients. Hemithorax was associated with pneumothorax was in 28 (35%), ribs fractures 17 (21.3%) and only 6 patients (7.5%) of cases were bilateral haemothorax. Patients with haemothorax and associated with head and abdominal injuries were referred or to be managed in other hospitals so they were not included in our study as shown in table (2)

**Table 2: Emergency thoracotomy and associated findings in patients with traumatic haemothorax**

Emergency Thoracotomy findings	No.	Percentage
Parenchymal injury	4	50.0
Chest wall and Intercostal injury	3	37.5
Pulmonary vein injury	1	12.5
Total	8	100.0
Associated finding	No.	%
Pneumothorax	28	35.0
Ribs fracture	17	21.3
Lung contusion	10	12.5
Bilateral haemothorax	6	7.5
Total	80	100.0

The majority of patients with traumatic haemothorax 62 (77.5%) who were treated with tube thoracostomy only or conservatively were discharged well within seven days. Those with air leak who needed thoracotomy had longer hospitalization periods. Only one of two patients with empyema post-penetrating injury were discharged after one month. Sixty-nine (86.3%) of our patients were discharged home well without complications. Three patients (3.75%) developed air leak, two patients (2.5%) developed empyema and needed thoracotomy and four (5%) developed clotted haemothorax and needed surgery. Two patients ended with death due to severe uncontrolled bleeding. The remaining 78

patients (97.5%) attended the follow up clinic irregularly, were healthy looking and in a good general condition, the outcome of traumatic haemothorax shown in table 3.

**Table 3: Hospital length of stay and outcome in patients with traumatic haemothorax**

Hospital length of stay	No.	%
3-7 days	62	77.5
8- 14 days	12	15.0
15- 30 days	3	3.7
More than 30 days	1[ <a href="#">a2</a> ]	1.3
Outcome	No.	%
Discharged well	69	86.3
Clotted haemothorax	4	5.0
Air leak	3	3.8
Empyema and Fibrothorax	2	2.5
Death	2	2.5
Total	80	100.0

### Discussion:

Traumatic haemothorax, whether due to penetrating or blunt injury is still being encountered in the daily practice of thoracic surgery in our country due to political instability. Eighty patients, who sustained trauma to the chest and developed traumatic haemothorax were studied retrospectively. The male predominance among the cases is due to the fact that most of the workforce consists of males due to social traditions. This result agrees with similar studies conducted in Iraq where (94%) [19] and (88%) [20] of the cases were males, and in Turkey where (75%) [21] of the cases were males. Regarding age, the highest frequency of the cases (40%) was seen in the third decade of life which can be explained by the fact that this age group is engaged in the workforce in our community. This agrees with the findings of other Iraqi studies were (44%) [19] and (36%) [20] were in this age group, and in the USA where (34%) [21] were in this

age group. Two thirds of the cases, had penetrating injury had penetrating injury compared to (33%) who were affected by blunt injury. This is higher than the results of some international studies where (15%) [21] were affected by penetrating injuries, but is in agreement with other Iraqi studies (19-20) where the rates of penetrating injury were (82%) and (94%) respectively. This can be explained by the availability of weapons and political instability in our country. Chest x-ray is the simplest and fastest investigation which is done in nearly all patients to establish the diagnosis and follow up. Other investigations like CT-scan or ultrasound were used in less frequency for complicated and localized haemothorax. This agrees with the results of studies from Iraq and from other countries [19, 20,21] the majority of patients were treated successfully by tube thoracostomy without the need to other interventional therapy, which agrees with all studies from Iraq [19, 20], Turkey [21], and USA [22], with the high percentages of patients were treated with tube thoracostomy only. Elective thoracotomy was done for a minority of our cases, this was found to be higher in all of the four compared studies. This can be explained by using of VATS or second chest tube insertion which mentioned in the study from Turkey [21] and USA [22], which is not a routine procedure in our hospital yet. Emergency thoracotomy was done for few of our patients in comparison with other studies of (9.6%) [19], and (16%) [20] may due to the high rate of penetrating injury in our study. In the study from Turkey [21] (13%) had emergency thoracotomy, and in the USA [22] (7.5%) had emergency thoracotomy. Only two patients (2.5%) with blunt trauma and a small amount of haemothorax were managed conservatively, which agrees with a study from Iraq [19] where (2.5%) were managed conservatively, and disagrees with other studies based on the estimated blood amount and on hospital protocol. The management of traumatic haemothorax in different studies is illustrated in table 4.

**Table 4: Management of traumatic haemothorax in different studies**

Study	Conservative No. (%)	Chest tube only No. (%)	Elective Thoracotomy No. (%)	Emergency Thoracotomy No. (%)
Our study	2 (2.5)	60 (75)	10 (12)	8 (10)
Yaser A. 2009(19) Iraq	4 (2.5)	127 (81)	9 (6)	15 (9.6)
Abdulameer M 2014(20). Iraq	37 (13)	168 (67)	14 (5)	44 (16)
Haberal M. et al, 2013(21) Turkey	0 (0)	92 (85)	2 (1.8)	14 (13)
MacLeod J. et al., 2011 [22] USA	146 (19)	522 (69)	26 (3.4)	56 (7.5)

Isolated haemothorax was found in nearly a third of patients with traumatic haemothorax, a quarter of whom were bilateral and three quarters one sided. More than a third of traumatic haemothorax was associated with pneumothorax, 21% with ribs fracture and 12% with lung contusion. This result coincides with other studies [20], [22] Ribs fracture in Turkey [21] happened in (28%) of cases which is higher than our study due to the higher rate of blunt trauma in the aforementioned study.

In our study three quarters of the cases were treated and discharged in one week, and a quarter patients needed more. This agrees with another Iraqi study [19]. and differs from a study in the USA [22] where (3%) needed more than one week of hospitalization due the frequent use of VATS and streptokinase use which is not a routine procedure in our hospital.

A tenth of our patients, underwent emergency thoracotomy, few of them had parenchymal injury and



laceration, and few had chest wall and intercostal vessels injury. This result agrees with all of four studies from Iraq [19],[20], Turkey [21] and. USA [22].

A few of our patients (11%) developed complications, continuous air leak, and empyema and clotted haemothorax) this result was higher than in the study from Turkey 8% [21] and the USA 5% [22], this is due to high rate of penetrating injury in our society and a limited use of thoracoscopy in our hospital. Two deaths occurred in our series which is lower than the other studies from Iraq [19] [20]. This can be explained by the fact that those patients with traumatic haemothorax and associated injuries which are at a high risk of death, were managed or referred to other hospital and they were not included in our study.

#### Conclusion:

Most of the patients with traumatic haemothorax can be treated by tube thoracostomy only. In haemodynamically unstable patients, there is no time to waste for investigations and a resuscitative thoracotomy can save the patient's life. Rapid assessment and early intervention will save the life of patient with traumatic haemothorax.

**Conflicts of interest:** There is no conflict of interest.

#### Author's contributions:

Waleed M. Hussen: contributed to study conception, study design, data analysis and interpretation, drafting of the manuscript.

Ahmed Noureldin Abdulkadir and, Akeel S.Yuser: contributed to study conception, study design

#### References

- Livingston DH, Hauser CJ, Chest WL. In: Feliciano DV, Mattox KL, Moore EE, eds. *Trauma*, 6th edition. New York: McGraw-Hill, 2008: 539.
- Tatebe S, Kanazawa H, Yamazaki Y, Aoki E, Sakurai Y. Spontaneous hemo- pneumothorax. *Ann Thoracic Surg*. 1996 Oct. 62(4):1011-5.
- Johnson EM, Saltzman DA, Suh G, Dahms RA, Leonard AS. Complications and risks of central venous catheter placement in children. *Surgery*. 1998 Nov. 124(5):911-6.
- Helling TS, Gyles NR, Eisenstein CL, Soracco CA. Complications following blunt and penetrating injuries in 216 victims of chest trauma requiring tube thoracostomy. *J Trauma*. 1989; 29:1367-70.
- Leshner AP, Kratz JM, Smith CD. Removal of embedded central venous catheters. *J Pediatr Surg*. 2008 Jun. 43(6):1030-4.
- Ota H, Kawai H, Matsuo T. Video-assisted minithoracotomy for blunt diaphragmatic rupture presenting as a delayed hemothorax. *Ann Thorac Cardiovasc Surg*. 2014. 20 Suppl:911-4.
- Rusch VW, Ginsberg RJ. Chest wall, pleura, lung and mediastinum. Schwartz SI, ed. *Principles of*

*Surgery*. 7th ed. New York: McGraw-Hill; 1999. 667-790.

8. Di Crescenzo V, Laperuta P, Napolitano F, Carlomagno C, Garzi A, Vitale M. Pulmonary sequestration presented as massive left hemothorax and associated with primary lung sarcoma. *BMC Surg*. 2013 Oct 8. 13 Suppl 2: S34.

9. Broderick SR. Hemothorax: Etiology, diagnosis, and management. *Thorac Surg Clin*. 2013 Feb. 23(1):89-96, vi-vii.

10. Caplan ES, Hoyt NJ, Rodriquez A, Cowley RA. Empyema occurring in the multiply traumatized patient. *J Trauma* 1984; 24:785-9

11. Rousset P, Rousset-Jablonski C, Alifano M, Mansuet-Lupo A, Buy JN, Revel MP. Thoracic endometriosis syndrome: CT and MRI features. *Clin Radiol*. 2014 Mar. 69 (3):323-30.

12. Sinniah D, Nagalingam I. Hemothorax in the newborn. *Clin Pediatr (Phila)*. 1999 Feb. 11(2):84-5.

13. Oğuzkaya, F., 2003. Traumatic hemothorax and pneumothorax. In Yuksel, M., Çetin, G., *Thoracic trauma 1. Edition*, İstanbul. Turgut Publishing, Inc.

14. Jin W, Hyun SY, Ryoo E, Lim YS, Kim JK. Costal osteochondroma presenting as hemothorax and diaphragmatic laceration. *Pediatr Radiol*. 2005 Jul. 35(7):706-9.

15. Hazelrigg SR, Landreneau RJ, Boley TM, Priesmeyer M, Schmaltz RA, Nawarawong W, et al. The effect of muscle-sparing versus standard posterolateral thoracotomy on pulmonary function, muscle strength, and postoperative pain. *J Thorac Cardiovasc Surg* 1991; 101:394- 400.

16. Inci I, Ozcelik C, Nizam O, Eren N, Ozgen G. Penetrating chest injuries: a review of 94 cases. *J Pediatr Surg*. 1996 May. 31(5):673-6.

17. Issaivanan M, Baranwal P, Abrol S, Bajwa G, Baldauf M, Shukla M. Spontaneous hemopneumothorax in children: case report and review of literature. *Pediatrics*. 2006 Oct. 118(4): e1268-70.

18. Parry GW, Morgan WE, Salama FD. Management of hemothorax. *Ann R Coll Surg Engl*. 1996 Jul. 78(4):325-6.

19. Yasser A, Elhassany N. Acute traumatic hemothorax, submitted to the Scientific Council of Thoracic and Cardiovascular Surgery in partial fulfilment of the requirement for the degree of the fellowship of the Iraqi Board for Medical Specializations in Thoracic and Cardiovascular Surgery. 2009.

20. Abdulameer M. A Review of 277 Cases of Patients with Chest Trauma in the Medical city Teaching Complex. *Iraqi Academic Scientific Journal*. 2014, 13:16088360:599-605.

21. Haberal M, Köksal E, Civan M, Tülüce K, Karadağ H, Şentürk Köksal Z. Traumatic hemothorax: Analysis of 108 cases. *Journal of Experimental and Clinical Medicine*. 2013;30(1):31-33.

22. MacLeod J, Ustin J, Kim J, Lewis F, Rozycki G, Feliciano D. *The Epidemiology of Traumatic*

Hemothorax in a Level I Trauma Center: Case for Early Video-assisted Thoracoscopic Surgery. *European*

*Journal of Trauma and Emergency Surgery.* 2009;36(3):240-246.

23.

### إنصباب الجنب الدموي الرضي: أساليب التشخيص والعلاج الجراحي

أ.د. وليد مصطفى حسين / كلية الطب / جامعة بغداد

د. احمد نور الدين قادر / م. ازادي / كركوك

د. عقيل سلمان يسر / م. ابن النفيس التعليمي

#### الخلاصة

**الخلفية:** إنصباب الجنب الدموي الناتج عن الشدة الخارجية (بيلة دموية صادمة) هي تجمع الدم داخل التجويف الجنبي بسبب إختراق أو إصابة حادة تؤدي إلى تراكم الدم داخل التجويف الجنبي مع عواقبه التنفسية والديناميكية الدموية.

**الهدف:** هو دراسة بأثر رجعي لثمانين مريضاً يعانون من بيلة دموية صادمة من الراقدين في مستشفى ابن النفيس التعليمي خلال الفترة (1 أغسطس 2018 إلى 30 سبتمبر 2019) وتم جمع البيانات الخاصة بهم باستخدام استمارة لتقسيمهم وتحليلها حسب العمر، الجنس، السمات السريرية، النتائج المرتبطة بها، آلية الإصابة، التصوير الشعاعي، الإجراءات المنجزة، النتائج الجراحية، النتائج بعد المراجعة، الاعتلال والوفيات والمتابعة.

**النتائج:** كان أربعة وسبعون من مرضانا (92%) من الذكور، والستة الباقية (8%) من الإناث، 32 (40%) كانوا بين 21-30 سنة. كانت الإصابة المختزقة بسبب الرصاص أو الطعنة 54 (68%) من المرضى بينما كانت الإصابات غير المباشرة 26 (32%) من المرضى. عند إستقبال المرضى تم إجراء الفحوصات المخبرية والتصوير الشعاعي والموجات فوق الصوتية للصدر أو تنظيف الشعب الهوائية وفقاً لحاجة المريض. عولج 60 (75%) من مرضانا بنجاح من خلال فتحة الصدر الأنيوية فقط. 8 (10%) من الحالات تطلبت بضع الصدر الطارئ بعد إدخال أنبوب الصدر، و10 (12%) من الحالات إحتاجت إلى بضع الصدر الإختياري من أجل (بيلة دموية متجلطة، أو إستخراج جسم غريب، أو دبيلة) الحاجة إلى التدخل. خرج اثنان وستون من مرضانا (77%) بشكل جيد في غضون 7 أيام. أولئك الذين لديهم تسرب الهواء أو بضع الصدر تطلبوا فترة أطول في المستشفى. إحتاج مريض واحد فقط مصاب بالدمة إلى البقاء أكثر من 30 يوماً. خرج تسعة وستون (86%) من مرضانا بشكل جيد، وقعت مضاعفات في ثلاثة مرضى مع تسرب الهواء، واثنين انتهى مع دبيلة وأربعة مرضى بيلة دموية مخثربة. وقعت الوفيات في اثنين من المرضى بسبب نزيف حاد غير منضبط.

**الإستنتاج:** معظم المصابين ببيلة دموية صادمة من الممكن علاجهم عن طريق أنبوب الصدر فقط لتصريف الدم وتعويضه. في المرضى الذين يعانون من عدم إستقرار الدورة الدموية الديناميكية، لا يوجد وقت لإجراء الفحوصات ويمكن لإجراء بضع الصدر الطارئ أن ينقذ الحياة. عمل تقييم سريع والتدخل المبكر سوف ينقذ حياة المريض المصاب ببيلة دموية صادمة.

**الكلمات المفتاحية:** إصابات الصدر، صدمة تنبيب الصدر، فتح صدر طارئ، إنصباب دموي مختزق.