

Missed foreign body inhalation for 15-years Case report and Review of Literatures

DOI: <https://doi.org/10.32007/jfacmedbagdad.6331848>.

Waleed M. Hussen* FIBMS (Th.C.VS), FACS, MRCS, FRCS (Glasgow)



This work is licensed under a [Creative Commons Attribution-NonCommercial 4.0 International License](https://creativecommons.org/licenses/by-nc/4.0/)

Abstract

Background: Foreign body inhalation is a life-threatening event in children and is common in our country. It can lead to morbidity and even mortality in the hands of untrained or not well-trained doctors.

Objective: Current study was to report a case of missed foreign body inhaled 15-years back, which is uncommonly reported in the literature and to compare it with other studies reporting similar cases.

Methods: The details, presentation, clinical findings, radiological appearance and the successful removal by a rigid bronchoscope under general anesthesia will be presented.

Results: The successful removal of this long-standing impacted foreign body (plastic whistle) using the rigid bronchoscope and the eventful outcome of patient's clinical symptoms was elucidated.

Conclusion: Refractory respiratory symptoms of long duration without improvement justify the need for diagnostic bronchoscopy which will offer the best chance of cure in missed foreign body inhalation.

Keywords: Bronchoscopy, Inhalation, Foreign body, Bronchiectasis,

J Fac Med Baghdad
2021; Vol.63, No. 3
Received: Sept., 2021
Accepted: Oct., 2021
Published: Oct. 2021

Introduction:

Foreign body (FB) inhalation is a life-threatening emergency in children. In Iraq, published data documented a high prevalence of FB inhalation among children. (1, 2). It might be related to poor parental attention, dietary habit, carelessness, negligence, and ignorance. Generally, the most common aspirated FB is organic material e.g. seeds, nuts or beans. The nature of aspirated FB is influenced by age, sex, nutritional habits, geographical area and socioeconomic status. Recently, data on a scarf pin aspiration were published in the literature from two Iraqi Governorates (3, 4). FB inhalation initially is presented with choking, paroxysm of cough or airway obstruction, then quiescent phase i.e. asymptomatic phase. If the situation is neglected, it leads to the presentation of complications. A report from Baghdad showed that the majority of patients were between 6-months and two-years, whom constitute (63.93%) of our patients (5). This case report aimed to show an inhaled plastic whistle that was removed after 15 years.

Case history

A 30-years old man from southern part of Iraq, had a long history of repeated chest infection for 15-years. He had cough and expectoration of dark yellow sputum and he consulted many general practitioners and chest physician and the diagnosis was ranging

between recurrent asthmatic attacks or bronchiectasis depending on his clinical, chest x-ray and CT examinations which showed localized bronchiectatic changes involving apico-lower segment of the right lower lobe (Figure 1).

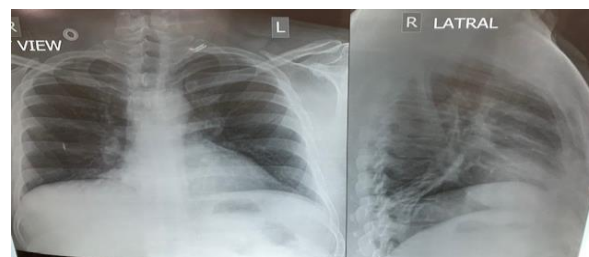


Figure (1) Segmental Bronchiectasis (apical segment of the right lower lobe).

Recently, the patient was referred to the pulmonology unit in the Medical City Teaching Complex, and the specialists there decided to do diagnostic Fiber optic Bronchoscopy under local anaesthesia and at that moment they discovered something obstructing the apical segment of the right lower lobe, stacked and impacted as well as very difficult to be disimpacted and retrieved. They terminated the procedure and discharged the patient. The patient was referred to me and on the next list, I did rigid bronchoscopy under general anaesthesia using Karl-storz rigid bronchoscope 8.5mm x 43cm and in the first trial I succeeded to dis impact and remove it. Then, I had to suck significant amount of pus distal to the site of impaction. The patient ran uneventful post-bronchoscopy course and discharged in a good condition for further follow up. Post bronchoscopy, he recalled that remote event and he thought that it had

* Department of Surgery, College of Medicine, University of Baghdad and Medical City Teaching Complex.

Email: dr_waleedmustafa@yahoo.com.

passed with bowel motion. The removed FB was shown in Figure (2).



Figure (2) Plastic whistle removed after 15-years of inhalation.

Discussion:

Foreign body inhalation may occur in both lay and professional populations of our society, although more common in those from lower socioeconomic status. The most important step in the diagnosis is the history as well as careful interrogation of the patient (1, 2). The usual presentation of foreign body inhalation is cough and dyspnoea, and this in agreement with study done by (6). However, the symptoms and signs depend on the type, size, shape, site of impaction and changes in the lung distal to the obstruction. Distally impacted foreign body usually presented late. Chest X-ray and CT findings may facilitate the diagnosis. No clear history of inhaled FB was in the presented case. Occult FB inhalation in adult had been reported to be undetected for years (7). The diagnostic delay might be explained by neglecting the importance of detailing remote history. Another factor for incorrect diagnosis was confusing the sequelae of FB inhalation with bronchiectasis secondary to infection. The latter was the situation in the presented case. However, it took a long time for complaining from late complications. Failure of diagnostic fiber-optic bronchoscopy was noticed in this case. Success of diagnosis and removal of FB was by rigid bronchoscopy under general anaesthesia. It was consistent with that reported in literature (8). Rigid bronchoscopy solved the problem of the observed case. Literature revealed that thoracotomy was used in missed inhaled FB for such a long period (7). In line with that reported in this study the aspirated FB was missed for 15 years. Surprisingly, although the inhaled FB was at age of 15 years, it was not detected by routine medical consultation. It might be explained by neglecting a detailed history. The patient was treated as a case of bronchiectasis or repeated chest infection. Patient's age at inhalation of FB in this case was 15 years. Such age was reported as a maximum age for FB inhalation in Kurdistan region of Iraq (8). This finding might be explained by dietary habit carelessness. The median duration between aspiration and bronchoscopic removal of the airway FB in the study of (6) was 21 days. One of the longest duration of endo-bronchial foreign body removed by rigid bronchoscopy was after 39-years of inhalation that was reported by (9).

Conclusion:

To pay attention for detailed history for cases of respiratory complains and bronchoscopy under general anesthesia will offer the best chance for removal of the foreign body.

Conflict of interest: Nothing to declare.

Funding: No financial support or sponsorship.

Declaration:

This is to declare that an informed consent was already taken on admission for any patient receiving our services as I am working in a Teaching Hospital entitled Medical City Teaching Hospital, Baghdad, Iraq.

References

- 1- Hussien WM. Tracheobronchial foreign bodies in paediatric age group. *J Fac Med Baghdad*. 1984; 26(4): (63-71).
- 2- Elhassani NB. Tracheobronchial foreign bodies in the Middle East. A Baghdad study. *J Thorac Cardiovasc Surg*. 1988; 96: 612-625.
- 3- Ragab A, Ebied OM, Zalt S. Scarf pins sharp metallic tracheobronchial foreign bodies: presentation and management. *Int J Pediatr Otorinolaryngol*. 2007; 71: 769-773.
- 4- Dagash MT. Foreign body inhalation of plastic headed pin of headscarf in Al-Fullujah, Iraq. *European J of Scientific Research*. 2014; 120: 177-183.
- 5- Hussein AM. Foreign bodies inhalation. *J Fac Med Baghdad* 2010; 52: 255-258.
- 6- Jeffrey Ng, et al. Clinical features and treatment outcome of air way FB Aspiration in adult, *Thorac Dis*. 2019; 11(3): 1056-1064.
- 7- Kamiyoshihare M, Ible T, Takeyoshi I. Inhaled foreign body overlooked for 25 years in an adult. *General Thoracic and Cardiovascular Surgery*. 2008; 56: 191-194.
- 8- Barama A, Sherzad H, Saeed S, Kakamad F, Hamawandi A. Tracheobronchial foreign bodies in children: the role of rigid bronchoscopy. *Global Pediatric Health*. 2017; 4: 1-6.
- 9- Kogure Y, Oki M, Aka H. Endo-bronchial foreign body removed by rigid bronchoscopy after 39-years: *Interact Cardiovasc Thorac Surg*. 2010; 11(6): 866-8.