

## **Diosgenin effect on rats and mice ovaries**

Israa M. Sulaiman Al-Chalabii \* M.B.Ch.B, Msc.

### **Summary:**

**Background:** Diosgenin is the main and the most important extract of crude fenugreek seeds' which was thought to be a precursor of steroidal materials.

**Aim of the work:** To advice Diosgenin application in future as a cheap ovulatory stimulator material, or as a low cost contraceptive pill.

**Materials and methods:** Sixty uncoupled female rats and mice were enrolled in this study, categorized into groups as mentioned in the text. Prolactin, estradiol and progesterone serum levels where measured for all groups. Histological and statistical analytical methods were applied to identify the increase in the folliculogenesis process within the ovaries of the studied animals.

**Results:** An elevation in prolactin, estradiol & progesterone serum levels was established in this study in all the experimental groups when compared to the control. These findings were confirmed histologically as shown in the figures present in the text.

**Conclusion:** In conclusion we can use the extracted diosgenin from the crude fenugreek seed's in medicine as an ovulatory stimulator material or as a low cost contraceptive pill depending on the dose given and the duration of treatment.

**J Fac Med Baghdad  
2005; Vol. 47, No.3  
Received June.2005  
Accepted Aug. 2005**

---

### **Introduction:**

The synthesis of pure new compounds obtained from phyto-chemistry has entered into medicine several years ago due to the fact that synthesizing and marketing of a new chemical drug is money and time consuming (1). In general Fenugreek herb and its seeds' was so popular in its use as a medicinal herb since the 19<sup>th</sup> century, all over the world, specially in our country; which was taken by many women as a cure for pre-menstrual syndrome.

The seeds of this herb after its extraction to its main extracts by (2) and due to the easily cultivation in most of Iraqi regions (1 & 3), and as the most effective medicinal part of this herb is its seeds; and traditionally cheap in our country and has had many advantages with no side effects (1, 2, 3, 4 & 5). As Sakran, 1999 (6) identified the histological and the histochemical effects of these crude seeds on the immature and mature ovarian rats.

Diosgenin is the main chemical component excreted from the fenugreek seeds oily embryo. It is one of the natural sources of steroids known (3 & 7) so it is the starting material for the partial synthesis of the medicinal steroids. The percentage of this saponifiable material within these seeds in total was reported to be 0.6-1.7% (1 & 8).

The rat's ovaries are lentiform in shape and have an irregular nodular surface. They are reddish in color. A single adult ovary weighs about 60 mg and measures 5x4x3mm (9). The ovary is covered by simple cuboidal or columnar epithelium (10) which merges at the hilus into the simple squamous epithelium of the ovarian bursa, the tunica albuginea is 5-16 µm thick and rich in argyrophilic and collagen fibers.

Depending on the age and the stage of the estrus cycle, a variable number of follicles and corpora lutea with groups of interstitial cells are found embedded in the meshes of the fibrous frame work (11). Most of the primordial follicles are found singly or in groups near the tunica, but some are scattered near the hilus. Growing follicles are located mainly deeper in the ovary. Mature Graafian follicles are located superficially and protruded on the surface of the ovary. Occasionally one is found deep in the parenchymatous zone (12).

In this study we used the main extracts of these seeds to identify its effects on adult female uncoupled mature rats and mice ovaries histologically, statistically and finally by hormonal assay. Since there are only a few studies that have been devoted to investigate the ovarian normal hyper-stimulation with contradictory results especially concerning outcome. Therefore this study was done in order to advice Diosgenin application in future as a cheap ovulatory stimulator material or as a low cost contraceptive pill!

---

\*Department of Anatomy, College of Medicine, University of Baghdad

**Materials and Methods**

**Materials**

Mammals enrolled in this study were sixty adult uncoupled female rats and mice. They were 30 in number each. Both had regular estrous cycle, and age range between 7-11 weeks. They were obtained from the animal breeding center of the drugs and biological quality control laboratory/Baghdad.

Two groups were involved, categorized according to the substances that have been given to them via oro-gastric tube daily for 14 days in addition to the normal range of tap water and food as shown in table(1).


**Table (1): Animal grouping according to the substances they received**

	GROUPS	NUMBER	SUBSTANCE RECEIVED	DOSAGES (mg/Kg body wt./day)
RATS	IR	10	Distilled water (DW)	2 ml
	IIR	10	Crude Fenugreek seeds' powder	1.6 suspended in DW
	IIIR	10	Extracted Diosgenin	0.024 suspended in DW
MICE	IM	10	Distilled water(DW)	2 ml
	IIM	10	Crude Fenugreek seeds' powder	1.6 suspended in DW
	IIIM	10	Extracted Diosgenin	0.024 suspended in DW

**Methods**

1. After anaesthetizing each animal by open ether [diethylether; (C<sub>2</sub>H<sub>5</sub>)<sub>2</sub>O, Fluka AC-Buchs SG], for about 90 seconds was used, the ovary with its surroundings fatty tissue was removed and immediately fixed for two hours in Carnoy's fluid [6 volumes absolute alcohol (GPR, BDH chemical LTD): 3 VOLUMES CHLOROFORM (GPR, BDH chemical LTD): 1 volume Glacial acetic acid (GPR, BDH chemical LTD)].

2. Hormonal Assay: Blood was from live anesthetized animals via cardiac puncture for hormonal assay. Hormones included in this study were estradiol, progesterone and prolactin. All these hormones were assayed using minVIDAS technique. The instrument used is shown in figure (1).



**Figure 1: mini VIDAS apparatus**

3. TLC: For identifying the presence of diosgenin, estradiol and progesterone with in the ovarian tissue after maceration in the group studied.

4. Histological morphometry: The fixed tissue specimens were processed for routine paraffin-wax embedding. This includes: Dehydration, Clearing, Infiltration, and Embedding. Sections were cut at 4-5 μm thickness, using electron microtome (Reichert-Jurg, 2030 MOT). Tissues were processed for routine haematoxylin and eosin stain (13). Later on the animals were sacrificed by cutting the abdominal aorta.

5. Statistical analysis: t- Test and histogram representations for the results obtained in this work was done by applying the excel program.

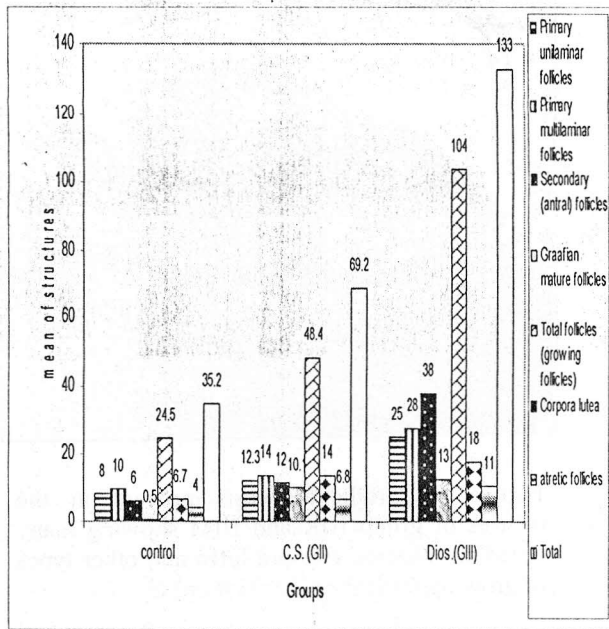
6. Photography: The pictures were taken by S.G. 35 Camera attached to the light microscope of Olympus type

**Results and discussion**

1. **Histological Morphometry:** By analysis done as shown in table (2) and figure (2) the following are identified:

**Table (2): The mean number of various ovarian components of control and experimental groups.**

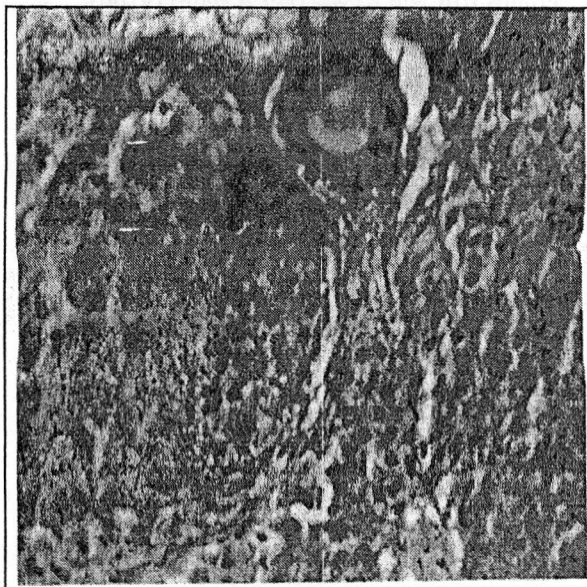
	various ovarian components	Control ± SD	C.S. (GII) ± SD	D.(GIII) ± SD
1	prim.Unilam.foll.	8 ± 4.8	12.3 ± 3.8	25 ± 2.3
2	prim.multilam.foll.	10 ± 3.1	14 ± 1.2	28 ± 1.9
3	sec. (antral) foll.	6 ± 0.1	12 ± 1.5	38 ± 8.1
4	Graafian matur.foll.	0.5 ± 2.1	10.1 ± 0.3	13 ± 9.1
5	tot.foll.(grow.foll.)	24.5 ± 7.1	48.4 ± 6.8	104 ± 21.4
6	Corpora lutea	6.7 ± 2.1	14 ± 0.1	18 ± 6.4
7	atretic foll.	4 ± 1.1	6.8 ± 1.3	11 ± 0.8
8	total	35.2 ± 10.3	69.2 ± 8.2	133 ± 28.6



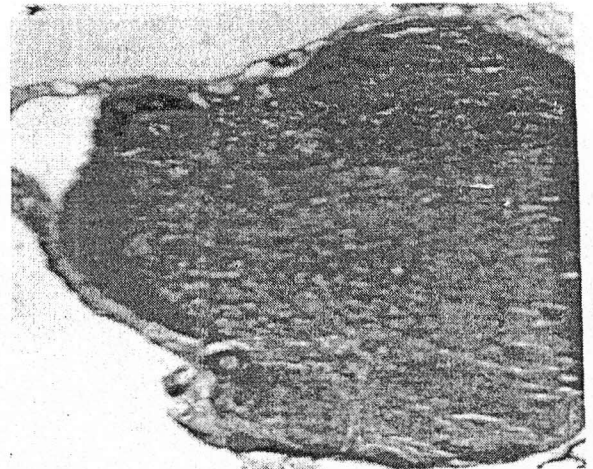
**Figure (2):** A frequency histogram the mean of different structures in the ovary of groups (IR, IM, IIR, IIM, IIR, IIM) in relation to the substances given mean obtained from 40 sections from 10 rats and other 40 sections from 10 mice.

**a. Control group I (R & M)**

The ovaries have smooth surface and friable on touch and surrounded by small amount of fatty tissue. By light microscope: we can observe different types of follicles (folliculogenesis process) (Figures 3&4).



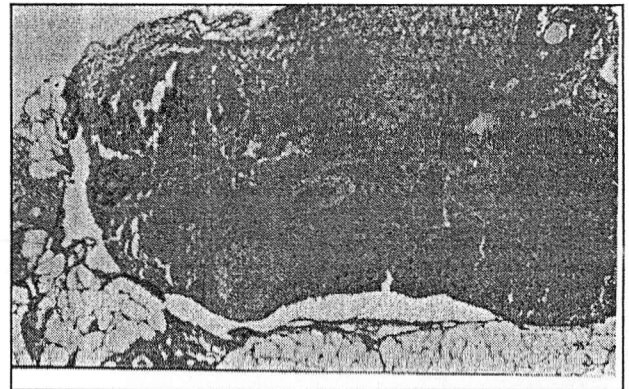
**Figure (3):** Growing ovarian follicles (vesicular follicles) stained by H & E stain as can be found in Groups IR and IM (x40)



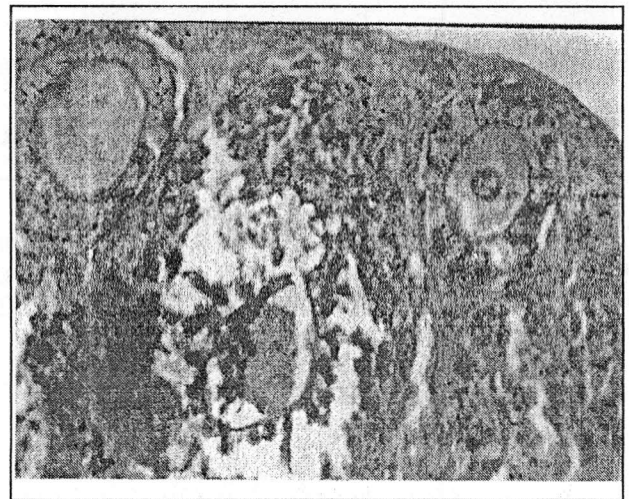**Figure (4):** A growing ovarian follicle with ovarian stroma stained by H & E stain as can be found in Groups IR and IM (x400)

**b. Crude Fenugreek seeds' treated group II (R & M):**

The growing ovarian follicles with the corpora lutea that are found in this group was enhanced more than the control one by as shown in figures (5, 6, & 7).




**Figure (5):** Growing ovarian follicles and Corpus luteum stained by H & E stain as found in Groups IIR and IIM (x100)



**Figure (6):** Growing ovarian follicles stained by H & E stain as found in Groups IIR and IIM (x100)

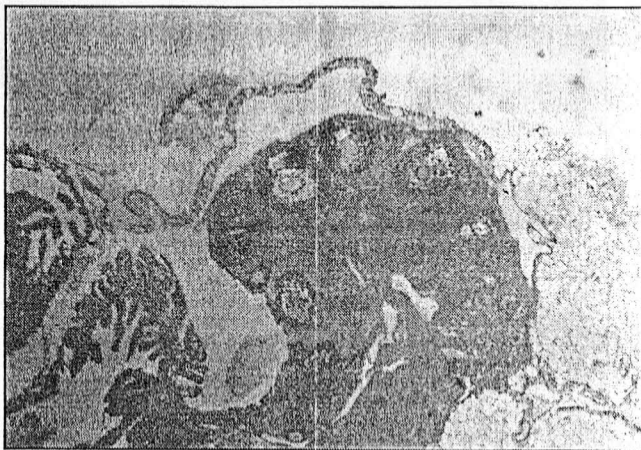




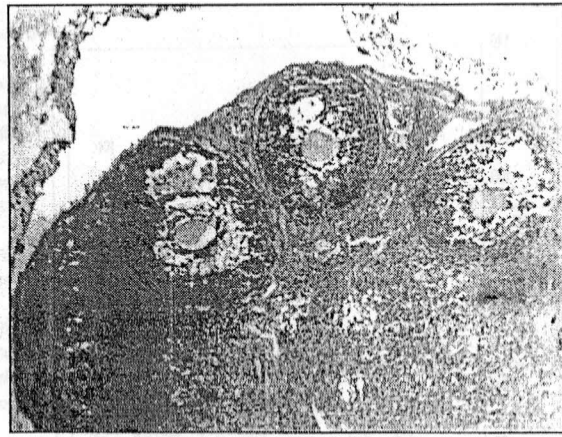
**Figure (7):** Folliculogenesis process in the ovaries of group IIR and IIM (HP) (H & E stain) (x100)

**c. Diosgenin treated group III (R & M)**

In contrast to the control and crude fenugreek seeds' treated groups there is a marked increase in the size of the ovaries (c. 2x2x1 mm) , while the fatty tissue around them is the same as in the other groups (non-significant difference) the ovary by itself become firmly in touch. By light microscope; marked increase in the number of growing follicles, atretic follicles and the total structures in the ovaries, as shown in figures (8, 9,10&11)



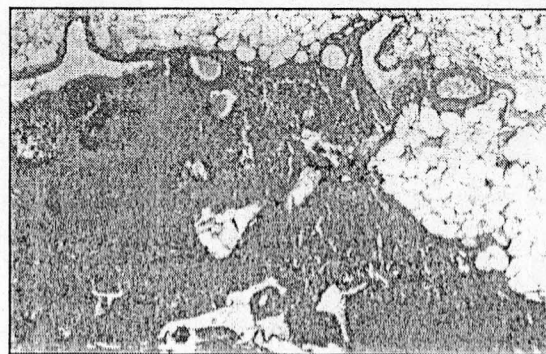
**Figure (8):** Folliculogenesis process in the ovaries of group IIIIR and IIIM showing many Graafian follicles, corpora lutea and other types of growing follicles. (H & E stain) (x40)



**Figure (9):** folliculogenesis process in the ovaries of group IIIIR and IIIM showing many Graafian follicles, corpora lutea and other types of growing follicles. (H & E stain) (x100)



**Figure (10):** Ovarian stroma showing growing follicles mostly secondary with presence of corpora lutea and regressing corpus luteum in groups IIIIR and IIIM. (H & E stain) (x100)



**Figure (11):** Folliculogenesis process in the ovaries of group IIIIR and IIIM showing many Graafian follicles, corpora lutea and secondary follicles. (H & E stain) (X100)

Diosgenin as it increases the serum sex hormones level it causes increase in the folliculogenesis process and causing the increase in thickness of the granulosa and theca interna cells around the growing follicles which by itself secret progesterone hormone in addition to increase number of corpora lutea that also secret progesterone hormone (18 and 19). These findings disagree with that of (20) who presumed that the ovary is the solitary site of sex hormone production. Diosgenin play a role in the rapidness of the maturation of the germinal epithelium of the ovary, demonstrated histological and biochemical. In conclusion we can use the extracted diosgenin from the crude fenugreek seed's in medicine as an ovulatory stimulator material or as a low cost contraceptive pill depending on the dose given and the duration of treatment.

2. Hormonal assay

An elevation in prolactin, estradiol & progesterone serum levels was established in this study in all the experimental groups when compared to the control one. The percentage of elevation of prolactin in groups II and III were (57% and 67.48% respectively). While the percentage of elevation of estradiol in groups II and III were (76% and 82.29% respectively). And the percentage of elevation of progesterone in groups II and III were (78% and 84.44% respectively). This elevation was significant in all groups as shown in figure (12).

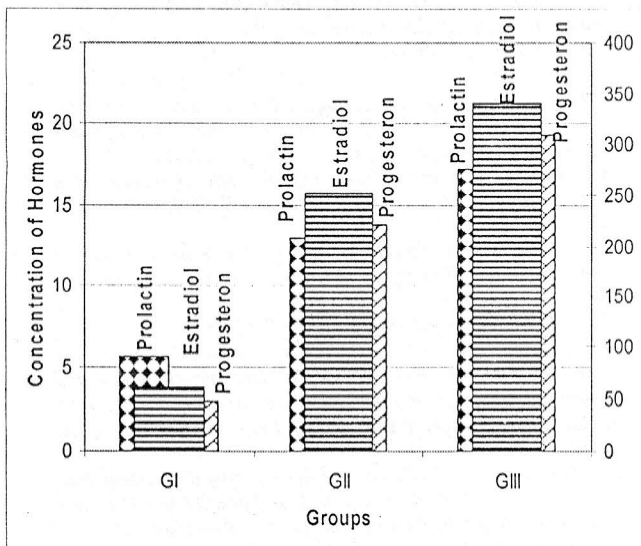
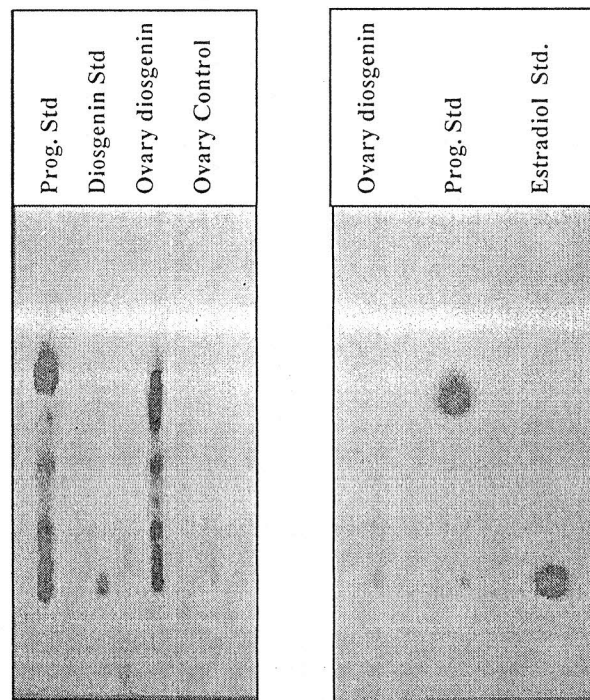


Figure (12): Comparison of Hormones level in the control and experimental groups. Thin layer chromatography

TLC) method was applied for the diosgenin treated group and compared with the standard diosgenin, estrogen and progesterone hormones after macerating the ovaries of the studied group. The results revealed that there is no diosgenin within the ovarian tissue but there occurs other metabolites from this material that resembles estrogen and progesterone TLC as shown in figures (13a & 13b).



13a

13b

Figure 13(a&b): TLC of control and diosgenin treated groups in comparison to the standards

As diosgenin is one of the two steroidal saponins diosgenin and gitogenin in 9:1 ratio. In addition two small amounts of yamogenin and hecogenin that were reported within the saponins after hydrolysis of fenugreek seeds (1, 2, 21, 22, 23, 24, 25 & 26). Those groups of glycosides, characterized by their property of forming durable foam when their watery solutions are shaken (8&24). Diosgenin, serves as starting material for the partial synthesis of the medicinal steroids, instead of synthesis of these steroids from acetate as shown in figure (14).

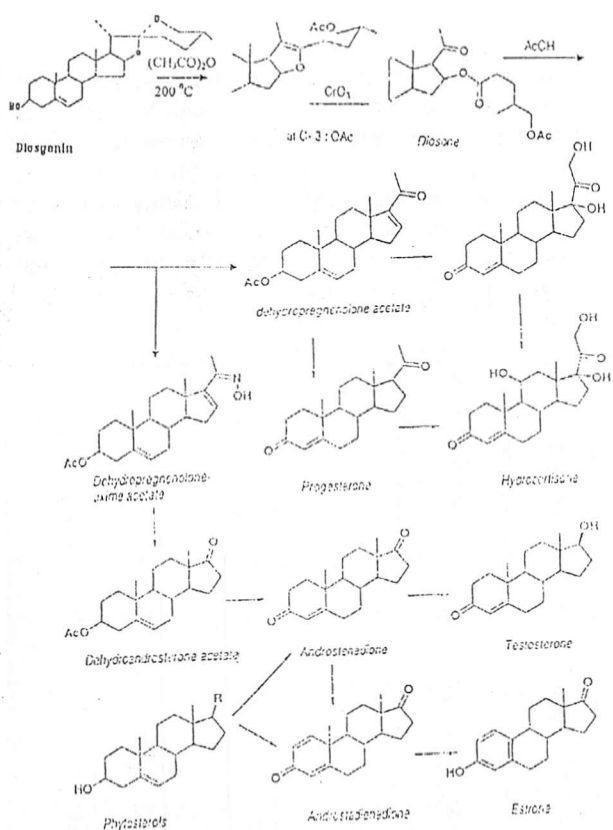


Figure (14): Chemical degradation of Diosgenin (7)

As a result, our outcome in this work suggests that the diosgenin extracted by Al-Chalabii 2000 (2) either has hormone like action by itself, or mostly it is metabolized in the liver or other organs forming materials that resembles the chemical structure of sex hormones (progesterone and estradiol) thus acting on their receptors and so giving the same hormonal effect on tissues. This explanation is based on the fact that diosgenin chemical structure resembles that of the precursor of these hormones (e.g. cholesterol structure) (Figure 12).

This fact also explains the significant elevation in the serum progesterone and estrogen levels and it is confirmed by TLC (Figure 13a&b). The increase in serum prolactin level as shown in figure 2 is may be due to the central action of diosgenin. This explanation is the most reliable in this work (18 & 27).

## References

- Newall C.A., Anderson L.A. and Phillipson J.D. (1996): *Fenugreek in Herbal Medicine: A guide for health care professionals*. The Pharmaceutical Press, London; pp: 114&118
- Al-Chalabii I. (2000): *The effect of various Fenugreek seeds, extracts on the adult virgin rat's mammary glands, histological and histochemical studies*. MSc thesis, Department of Anatomy, University of Baghdad
- Kotb F. (1985): *Trigonella foenum-graecum: Medicinal plants in Libya*. Arab Encyclopedia House. First edition. pp:85-86
- Al-khateeb H. (1996): *Some morphological and histochemical studies on rat's mammary gland*. Ph.D. thesis. Department of Anatomy, College of Medicine, University of Baghdad
- Al-Khalisi M. H. H. (2000): *The effect of fenugreek seeds on mammary gland, a histological and histochemical study*. M. Sc. Thesis, Department of Anatomy, College of Medicine, University of Baghdad.
- Sakran A. (1999): *The effect of Fenugreek seeds on rat's ovary histological and histochemical studies*. M.Sc. Thesis, Department of Anatomy, College of Medicine, University of Baghdad
- Evans, W.C.(2002): *Saponins, Cardioactive drugs and other steroids*. In: Part 6; *Pharmacopial and related drugs of biological origin*. In: Evans W.C., Trease and Evans, *Pharmacognesy*. Fifteenth ed. PP: 289-315 W.B. Sanders. Edinburgh London, New York Philadelphia St. Louis Sydney Toronto.
- Cave' A. (1995): *Introduction in pharmacognosy, phytochemistry, and medical plants*. Translated by Hatton C. K. *Universite'de Paris-Sud-Andover*, England, UK, London, New York; pp: 538-597.
- Hebel R. and Stromberg M.W. (1986): *Female reproductive organs*. In: Hebel R. and Stromberg M. W. *Anatomy and Embryology of the laboratory rat*. Bio. Med., Verlag Worthsee; PP: 81-88.
- Berralanffy and Lau (1963): *Quoted by: Hebel R. and Stromberg M. W. Anatomy and Embryology of the laboratory rat*. Bio. Med., Verlag Worthsee; 85
- Robertson W. B. (1981): *Normal endometrium In: Robertson W. B. the endometrium*. Butter Worth and Co. Pub. First Published; pp:7-44
- Bolling J L, Blandau A L, Soder wall, and Young W C (1941): *Growth of the Graaffian follicle and the time of ovulation in the Albino Rat*. *Anatomy. Rec.*; 79:313-331
- Bancroft-JD and Stevens-A (1987): *Theory and Practice of Histological Techniques*. Edinburgh: Churchill Livingstone.
- Al-Ayadi M (1944): *The nutritional value of breads made from grain mixtures*. *J. Egypt Med. Ass.* ;27: 248-257
- Hassan A and Al-Ayadi (1944): *The presence of a lactation stimulating factor in the fenugreek oil*. *J. Egypt. Med. Ass.* , 27;pp:236-247
- El-Ridi M. and Shahat M. (1944): *A preliminary note on a fat-soluble lactation factor*. *J.Egypt Med. Ass.* (27): pp:199-200
- Al-Chalabii Israa (2005): *To be Published*
- Ganong F. W. (1993): *Review of medical physiology; the female reproductive system, the gonads: development and function of the reproductive system*. Sixteenth edition. Pub. Appleton and Lange, Prentice-Hall International Inc. USA; 39411.
- Saladen K S (2001): *The female reproductive system*. Part five. In: Saladin K S (Ed.). *Anatomy and physiology. The unity of form and function*. Second edition; 28: 1046-1084
- Longcope C, Pratt H J and Schneider S (1978): *Aromatization of androgenby muscle and adipose tissue in vivo*. *J. Clin. Endocrino. Metab.*; 46:146-152
- Fazli and Hardman (1968): *Quoted by: Some morphological and histochemical studies on rat's mammary gland*. Ph.D. thesis, Department of Anatomy, College of Medicine, University of Baghdad (1996); pp:69-80
- Ross M and Brain (1977): *Steroid hormones*. In: *An introduction to Phytopharmacy*. Pitman Medica.; pp:43-45