

Modified Sugiura Operation for Portal Hypertension and Bleeding Esophageal Varices

Omar S. Khattab*, M.B.Ch.B , H.D.S , H.D.L.M , F.I.C.M.S, C.A.B.S
Samie B. Safar, M.B.Ch.B , F.R.C.P, F.R.C.S, F.A.C.S

Summary

Background: To find an operation that can be effectively carried out in both adults and children, equally applicable in the elective as well as in the emergency situation and for the good – risk as well as the poor – risk patients. Done by expert and junior surgeons in a short time.

Patients and Methods: Twenty patients with portal hypertension and bleeding varices aged 9-45 years were treated with shunting procedures (group 1, n=10), or a modified Sugiura operation (group 2, n=10) in accordance with the following therapeutic protocol: after resuscitation and diagnostic endoscopy, an emergency modified Sugiura operation was carried out if bleeding could not be controlled over 24 hours. When bleeding could be controlled, the patients underwent full investigation and were then treated with either shunting procedure or with a modified Sugiura operation. The Fisher exact probability test was applied for statistical analysis.

Results: Patients were evaluated at 1-3 years. The rates for operative deaths, recurrent hemorrhage, encephalopathy, late deaths, and patient survival at 1-3 years were as follows: 30%, 10%, 40%, 10% and 60% for group 1; 10%, 0%, 0%, 10%, and 80% for group 2, respectively. Within 3 months after the modified Sugiura operation, varices disappeared in most of the patients and hypersplenism was relieved in all.

Conclusion: We conclude that the modified Sugiura operation is probably a reasonable treatment for variceal hemorrhage because it is effective in arresting hemorrhage and its recurrence, with no encephalopathy, and a good survival rate.

Key Words: Portal hypertension, bleeding varices, non shunt operation, Sugiura operation.

J Fac Med Baghdad
2007; Vol. 49, No.2
Received Oct. 2006
Accepted March 2007

Introduction:

The Ebers Papyrus provides evidence that the Egyptians were aware of the relationship between ascites and diseases of the liver. It was not until the turn of the twentieth century that Gilbert and associates and Pichancourt reasoned that pressure within the portal system was elevated in patients with ascites; they introduced the term “portal hypertension”.

A consideration of the role of surgery in the treatment of portal hypertension must begin with the experimental work of Nicholas V. Eck, a Russian surgeon. In 1877, he reported that he had anastomosed the portal vein to the vena cava of eight dogs.^(1,2,3)

The treatment of portal hypertension and bleeding esophageal varices has remained a controversial problem in surgery for several decades and many shunting procedures have been described to treat this condition.^(4,5,6) Surgical therapy often remains the only method of treatment that save the patient from exsanguination. Although portal decompression is effective for the control and prevention of variceal hemorrhage, it is often associated with serious deterioration in the patient's quality of life because of resultant ecephalopathy and when carried out as an emergency procedure, it has a very high mortality rate.

To reduce the incidence of ecephalopathy, Warren et al. devised the selective distal spleno-renal shunt, and in an attempt to reduce the operative mortality rate and the technical difficulty of shunt operations, particularly in the emergency situation, Drapanas et al. Introduced the interposition mesocaval shunt. Although ecephalopathy is reduced with the Warren shunt, neither patient survival nor recurrent hemorrhage is any different from that obtained with standard Porto systemic shunting. In addition, recent reports appear to show a high incidence of ecephalopathy and shunt occlusion with the interposition shunt.^(7,8,9,10)

Because of the unsatisfactory results of shunting operations, several non shunting procedures have been described.^(11,12,13,14) These procedures have been the subject of several recent reviews and their results have been quiet variable in terms of operative mortality rates, recurrent hemorrhage, and long-term survival. Sugiura and futagawa described a non shunt therapy for variceal hemorrhage by a combined two-stage procedures of extensive devascularization of the abdominal and thoracic esophagus, esophageal transaction, splenectomy, vagotomy, and pyloroplasty. In a later report sugiura and futagawa reported a very low mortality rate, low incidence of recurrent bleeding, a seven year survival rate of 82% and no encephalopathy.^(2,8,15,16,17)

Although the results of the sugiura operation have not been reproduced by many investigators

* Lecturer of Surgery, Dep. Of Surgery, College of medicine, Baghdad University, Iraq

outside Japan, we became impressed both by the theoretical rational of this procedures and the excellent long-term results. In addition because of the complexity of the two stage procedure as described by sugiura, it was decided to modify and simplify this operation to a single stage, transabdominal operation, which can be done in a short time. And to overcome disadvantages of sugiura procedure which was mainly due to esophageal transection and pyloroplasty including early dysphagea, stricture requiring dilatation, esophageal reflux, esophageal leak, duodenal leak, and subphrenic abscess, we decided to perform continuous running through and through suturing of the anterior and posterior gastric wall instead of esophageal transaction, and pylormyotomy instead of pyloroplasty. Then we decided to evaluate the efficacy of this operation in Parallel with shunting procedures.

Patients And Methods:

Between October 1994 and October 1997, 20 patients with variceal hemorrhage were referred to our surgical unit in Medical City Teaching Hospital in Baghdad for surgical treatment. They included, 14 males and 6 females, with age range 9-45 years.

All patients were informed of the significance of this trial, including the risks, and written informed consent was obtained from all patients. The Fisher exact probability test was applied for statistical analysis

After resuscitative measures were begun, which included blood and fresh frozen plasma infusion and cold gastric lavage, endoscopy was carried out to confirm bleeding varices, and variceal sizes were classified into four grades (table1). Sengstaken – Blakemore tube was required once only in a patient who continue to bleed.

Then initial clinical, biochemical, and hematologic assessment was carried out and the patients were graded according to Child's classification into A, B, and C with modification into a flexible system using points (table 2).

Table1. endoscopic grading of varices.⁽¹⁸⁾

Grade I	≤ 3mm
Grade II	4-6mm
Grade III	7-10mm
Grade IV	≥ 10mm

Table2. modified flexible system of Child's classification.⁽¹⁹⁾

Serum bilirubin (mg/100ml)	< 2 (1) , 2-3 (2) , >3 (3)
Serum albumin (mg/100ml)	>3.5 (1) , 3-3.5 (2) , <3 (3)
Prothrombin time (second prolonged)	< 2 (1) , 3-5 (2) , >5(3)
Ascites	non (1), mild/moderate(2), gross(3)
Encephalopathy	none(1),minimal(2),moderate/severe(3)

The added points are classified as follows:

A=5-7 points

B=8-9 points

C=10-15 points

Ascites : none= no ascites

Mild/moderate=when ascites disappears spontaneously or with diuretics.

Gross=if this had accumulated rapidly and led to a tensely distended abdomen or if this was poorly controlled with diuretics.

If bleeding could not be controlled over 24 hours or if it recurred, the patient was treated with emergency surgery. If the bleeding was controlled, the patient was then given nutritional and liver support for a period of 1to 2 weeks, during which the following evaluation was carried out: complete blood count, platelet count, renal function test, liver function test, serum protein electrophoresis, prothrombin time, surface antigen test for hepatitis B, anti hepatitis C virus antibody, anti mitochondrial antibody, anti smooth muscle antibody, abdominal ultrasonography, percutaneous liver biopsy, oesophago gastroduodenocopy, barium swallow, splenoportography, and inferior venacavography sometimes (figure1 and figure2).

Then the same surgical team operated all patients on. Six types of surgical modalities had been utilized. The amount of intraoperative blood transfusion and the time taken for the operative procedure were recorded. Wedge liver biopsy was taken in all patients following surgical decompression.

Operative Procedures:

1. Mesoatrial Shunt:

Was performed for two patients with Budd-Chiari syndrome. One had occlusion of the inferior vena cava due to thrombosis extending from the hepatic veins and the other due to compression by the enlarged liver.

By upper midline incision and median sternotomy, 10 mm Goretex graft was used for both patients. The graft was anastomosed end to side to the superior mesenteric vein just before the vein passed behind the neck of the pancreas. the graft was then passed through the transverse mesocolon, anterior to the stomach and under the xiphoid process into the mediastinum. the graft was anastomosed end to side to the right atrium. The amount of intraoperative blood transfusion was 6

pints and the operative procedure lasted about 3 hours.

2. Distal Splenorenal Shunt:

Was performed for 2 patients. By upper midline incision, the spleen was not removed, and the splenic vein was dissected free from the posterior surface of the pancreas down to the junction with the mesenteric vein and divided. Its distal end was anastomosed end to side to the left renal vein. Included in the procedure was ligation of the coronary vein and devascularization of the stomach by ligation of all vessels with the exception of the right gastric artery and the short gastric veins.

The procedure required 4 pints of blood, lasted about 3 hours. And was favorable with patent splenic vein, adequate size of the left renal vein, and satisfactory liver function in the absence of marked ascites.

3. Central Splenorenal Shunt:

was performed for 2 patients. By upper midline incision, the short gastric vessels were doubly ligated and transected, the splenophrenic and splenorenal ligaments were then transected and dissection continued in the hilus until an ultimate pedicle of splenic artery and vein remains, the splenic artery was double ligated and transected. The splenic vein was freed as it courses along the pancreas, and transected as close to the hilus of the spleen as possible, and the spleen was removed. The splenic vein was then brought down to an appropriate site on the anterosuperior aspect of the left renal vein. An end to side anastomosis was performed.

The procedure required 4 pints of blood, lasted about 2-3 hours, and employed in patients with portal vein thrombosis.

4. Superior Mesenteric Inferior Vena Cava Shunt:

Was performed for 3 children. By right paramedian incision extended below the umbilicus. Upward traction on the transverse colon exposes the superior mesenteric vessels. The peritoneum was incised in the region of the superior mesenteric arterial pulse, and the superior mesenteric vein was identified and dissected free. The lateral reflection of the ascending colon was then incised along its entire length to permit medial displacement of the transverse and ascending colons and the medial reflection of the ascending mesocolon. This exposes the inferior vena cava and the third portion of the duodenum. The inferior vena cava was mobilized from its origin up to the entrance of the right renal vein. The paired lumbar veins are ligated and transected. The inferior vena cava was transected as far distal as possible and the caudal stump ligated. A window was created in the mesentery of the small intestine to permit approximation of the free end of the inferior vena cava to the right posterolateral aspect of the superior mesenteric vein. For 2 children with hypersplenism we added

ligation of the splenic artery instead of splenectomy.

The procedure required 2-3 pints of blood, lasted about 2-3 hours. This procedure was employed for children in whom a splenorenal anastomosis is doomed to failure because of the small size of the splenic vein.

5. Interposition Mesocaval Shunt (H-Shunt):

Was employed for one patient. We exposed the superior mesenteric vein and the inferior vena cava by the same technique employed in mesocaval shunt. Then Dacron graft 10 mm in diameter was interposed between the superior mesenteric vein and the inferior vena cava.

The procedure required 2 pints of blood, and lasted about 2 hours.

6. Modified Sugiura Operation:

Was performed for 10 patients. 2 patients were operated on as an emergency. By upper midline incision, gastric devascularization was performed by mobilization of both curvatures of the stomach, dividing the short gastrics, the right and left gastroepiploic vessels along with the coronary vein and the left gastric artery. So the right gastric vessels remain the only blood supply to the stomach.

To interrupt the intramural gastroesophageal venous connections we performed continuous running through and through suturing of the anterior and posterior gastric wall using 2/0 chromic catgut.

The vagal trunks were identified, truncal vagotomy done with pyloromyotomy as drainage procedure. Splenectomy or ligation of the splenic artery in patients with hypersplenism was done.

Extensive oesophageal devascularization from the cardioesophageal junction high up to the level of the inferior pulmonary vein was attempted (figure3).

Postoperative gastric decompression was maintained for 24 hours. The procedure required 1-2 pints of blood, and lasted about 1-2 hours.

Postoperatively all patients received prophylactic antibiotics for 5 days, with infusion of plasma, albumin and diuretic therapy as required. An esophageal endoscopy was performed on the 7th postoperative day to assess the varices.

After discharge from the hospital, all patients were evaluated as an outpatient at 3 months intervals with clinical, hematologic, biochemical, and upper gastrointestinal endoscopy assessment.

Results:

Age and Sex Distribution:

20 patients with portal hypertension were managed surgically. 14(70%) were males and 6(30%) were females. 18 patients were Iraqis, 1 Yemenis, and another from Sudan. The age range was 9-45 years. The highest age incidence was between 21-30 years (figure4).

Clinical Presentations:

Bleeding was the presenting symptom, the number of bleeding episodes ranged between 1-30, over 2 weeks- 10 years duration, the total amount of blood required was between 6-55 pints. The bleeding was self-limited in most cases, while 6 patients had already received endoscopic injection sclerotherapy (1-10 sessions). 16 (80%) patients presented with haematemesis and malaena, 4(20%) patients with malaena only.

Splenomegaly was the second manifestation in all patients (100%), 8(40%) of them with hypersplenism. The splenomegaly was detected clinically in 11(55%) patients, and by ultrasonography in 9(45%) patients.

Ascites was present in 15(75%) patients, it was mild / moderate in 10(50%) patients, and gross in 5(25%) patients. 7(35%) of the 15 patients with ascites were jaundiced.

Hepatomegaly was found in 6(30%) patients.

Abdominal pain was found in 2(10%) patients with Budd-Chiari syndrome.

Causes of Portal Hypertension:

The causes of portal hypertension were pre-hepatic in 7(35%), hepatic in 10(50%), and post-hepatic in 3(15%) patients (table3).

The clinical data and the causes of portal hypertension are shown in (table 4).

Table3.comparison of the aetiology of portal hypertension

Aetiology	Our study	Bailey and Love s. (20)
Pre hepatic	35%	20%
Hepatic	50%	80%
Post hepatic	15%	rare

Endoscopic Findings:

Upper gastrointestinal endoscopy shows esophageal varices in all patients (100%), with gastritis in 2 patients (10%), one of them had cirrhosis and the other had portal vein thrombosis. Gastric varices were found in 1 patient (5%) with portal vein thrombosis.

Treatment:

(Group 1) included 10 patients treated with shunting as an elective procedure. According to Child's classification, 5 were grade A, 2 grade B and 3 grade C. Oesophageal varices were grade I in 2 patients, grade II in 3 patients, grade III in 3 patients, and grade IV in 2 patients. The pathologic causes of portal hypertension were portal vein thrombosis in 4, Budd-Chiari syndrome in 2, non alcoholic cirrhosis in 2, a combination of primary biliary cirrhosis and portal vein thrombosis in 1, and

chronic active hepatitis with positive HBs Ag in 1 patient. Hypersplenism was present in 3 only. The shunting procedures were mesocaval shunt in 3, with added splenic artery ligation in 2 of them, mesoatrial shunt in 2, distal splenorenal shunt in 2, central splenorenal shunt in 2, and 1 patient had mesocaval H-shunt (table 5).

(Group 2) included 10 patients treated with modified Sugiura operation, in 8 as an elective procedure, and in 2 as an emergency. According to Child's classification, 4 were grade A, 3 grade B and 3 grade C. Esophageal varices were grade I in 1, grade II in 3, grade III in 3, and grade IV in 3 patients. The pathologic causes of portal hypertension were portal vein thrombosis in 3, non alcoholic cirrhosis in 1, a combination of non alcoholic cirrhosis and portal vein thrombosis in 1, alcoholic cirrhosis in 1, Bilharzial cirrhosis in 1, chronic active hepatitis with positive HBs Ag in 1, metastatic carcinoma in 1, and tuberculous pericarditis in 1 patient. Hypersplenism was present in 5 patients; splenectomy was added in 4, and ligation of splenic artery in one patient (table 5).

Mortality:

After shunting procedures (group 1), 3(30%) hospital deaths occurred, one on the 7th postoperative day in a patient with Budd-Chiari syndrome, Child's grade C, and the other two on the 10th postoperative day, one had portal vein thrombosis, Child's grade B, and the other had non alcoholic cirrhosis, Child's grade C, all were due to liver failure, 1(10%) late death occurred after 1.5 year in a patient with non alcoholic cirrhosis, Child's grade A, due to recurrent bleeding and liver failure, the 1-3 year survival rate was 60%.

After modified Sugiura operation (group 2), 1(10%) hospital death occurred on the 5th postoperative day in a patient with a combination of non alcoholic cirrhosis and portal vein thrombosis, Child's grade C, grade IV varices, operated on as an emergency. 1(10%) late death occurred after 1 year in a patient with metastatic carcinoma, Child's grade B, due to malignancy. The 1-3 year survival rate was 80%.

The mortality was recognized mainly in patients with liver damage, and showed a direct correlation with Child's grading for hepatic reserve.

(table 6) shows classification of the mortality rate according to Child's grading for hepatic reserve.

Recurrent Bleeding:

After shunting procedures (group 1), 1(10%) patient rebled from esophageal varices.

While after modified Sugiura operation (group 2), no patient developed recurrent bleeding (0%).

Encephalopathy:

After shunting procedures, 4(40%) patients developed acute encephalopathy.

While after modified Sugiura operation, no patient developed encephalopathy (0%).

By application of Fisher exact probability test resulted in p-value(p< 0.05) which was statistically significant.

The overall results in these two groups, in terms of mortality rates, recurrent hemorrhage, encephalopathy, and survival rate are compared in (table 7).

Effect on esophageal varices:

The disappearance of esophageal varices was seen in both groups, but this was slower and less complete in group 1(table8).

Hypersplenism and Splenomegaly:

Postoperatively hypersplenism was corrected in both groups whether we performed splenectomy or ligation of the splenic artery.

Reduction of the splenic size occurred in all patients undergone ligation of the splenic artery.

Table4. clinical data and aetiology

	No.of Pts.	Age Year	Sex	Duration Of illness	Pints Of Blood	Hepato megaly	Spleno megaly	Ascitis	Jaundice	Abd. Pain	Aetiology
Patients Treated by Shunting Procedures	1	30	M	4m	6	+	+	+++	+	+	Posthepatic
	2	28	F	2y	8	-	+	++	-	-	Hepatic
	3	40	F	5y	10	-	+	-	-	-	Prehepatic
	4	12	M	2m	16	-	+	++	+	-	Hepatic
	5	9	M	6y	55	+	+	++	-	-	Prehepatic
	6	25	F	1y	6	+	+	+	+	+	Posthepatic
	7	35	F	2wk	9	-	+	-	-	-	Prehepatic
	8	12	F	1y	11	+	+	+++	-	-	Hepatic
	9	15	M	4y	6	-	+	-	-	-	Prehepatic
	10	45	M	10y	9	-	+	++	+	-	Hepatic
Patients Treated by Modified Sugiura	1	28	M	8y	40	-	+	++	+	-	Posthepatic
	2	30	M	1y	8	-	+	+	-	-	Prehepatic
	3	23	M	1y	19	-	+	++	+	-	Hepatic
	4	10	M	2y	8	+	+	++	-	-	Hepatic
	5	23	M	6m	4	-	+	-	-	-	Prehepatic
	6	42	F	9m	20	+	+	+++	-	-	Hepatic
	7	34	M	1y	36	-	+	+++	+	-	Hepatic
	8	11	M	2y	10	-	+	+++	-	-	Prehepatic
	9	27	M	5y	30	-	+	+	-	-	Hepatic
	10	40	M	7y	8	-	+	-	-	-	Hepatic

Table5.comparison of the child's classification, endoscopic grading of the esophageal varices, and pathologic causes in the two treatment groups.

	Shunting procedures (group 1)	Modified Sugiura operation (group 2)
Number of patients	10	10
Age range	9y - 45y	10y - 42y
Male/Female ratio	5 - 5	9 - 1
Child's classification		
A	5	4
B	2	3
C	3	3
Endoscopic grading of varices		
Grade I	2	1
Grade II	3	3
Grade III	3	3
Grade IV	2	3
Pathologic causes	<ul style="list-style-type: none"> • Portal vein thrombosis 4 • Non alcoholic cirrhoses 2 • Chronic active hepatitis 1 + positive HBs Ag • Primary biliary cirrhosis 1 + portal vein thrombosis • Budd-Chiari syndrome 2 	<ul style="list-style-type: none"> • Portal vein thrombosis 3 • Non alcoholic cirrhoses 1 • Chronic active hepatitis 1 + positive HBs Ag • Non alcoholic cirrhoses 1 + portal vein thrombosis • Alcoholic cirrhosis 1 • Bilharzial cirrhosis 1 • Metastatic carcinoma 1 • Tuberculous pericarditis 1

Table6.mortality rates classified according to Child's criteria.

Grade	Group 1		Group 2		Total	
	No. of Pts (%)	Mortality No. (%)	No. of Pts (%)	Mortality No. (%)	No. of Pts (%)	Mortality No. (%)
A	5 (50)	1 (20)	4 (40)	0 (0)	9 (45)	1 (11.1)
B	2 (20)	1 (50)	3 (30)	1 (33.3)	5 (25)	2 (40)
C	3 (30)	2 (66.6)	3 (30)	1 (33.3)	6 (30)	3 (50)

Table7.comparison of the results of surgical treatment in the two treatment groups.

Group	No. of Pts	Hospital Deaths No. (%)	Recurrent Hemorrhage No. (%)	Encephalopathy No. (%)	Late death No. (%)	1-3 years survival No. (%)
1	10	3 (30)	1 (10)	4 (40)	1 (10)	6 (60)
2	10	1 (10)	0 (0)	0 (0)	1 (10)	8 (80)

Table8.changes in variceal findings by endoscopic examination.

Grade	Preoperative		Postoperative		Long term	
	Group 1 No. (%)	Group 2 No. (%)	Group 1 No. (%)	Group 2 No. (%)	Group 1 No. (%)	Group 2 No. (%)
I	2 (20)	1 (10)	2 (20)	3 (30)	1 (10)	1 (10)
II	3 (30)	3 (30)	2 (20)	1 (10)	1 (10)	0 (0)
III	3 (30)	3 (30)	1 (10)	0 (0)	0 (0)	0 (0)
IV	2 (20)	3 (30)	0 (0)	0 (0)	0 (0)	0 (0)

Ascites:

Ascites was present in 7 patients in group 1, and in 8 patients in group 2 at the time of operation and disappeared afterward.

Resistant ascites was present in 2 patients in group 1 and in 3 patients in group 2, which were possible to be controlled postoperatively with medical treatment.

Discussion:

Bleeding oesophageal varices represent a medical disaster of the first order that carries an immediate mortality rate of 20 % to 50 %.⁽¹⁾

Because the pathologic changes that cause portal hypertension cannot be altered (except by liver replacement in hepatic aetiology), all available methods of treatment are indirect procedures that deal with manifestations of the disease. Whatever the method, there remains a major therapeutic dilemma in the treatment of variceal hemorrhage because there is as yet no "ideal" therapy for this condition.

Such "ideal" therapy would be one that meets the following aims and objectives: to ensure speedy arrest of bleeding and prevent further hemorrhage, to carry minimal mortality and morbidity risks, to prevent late deaths from impaired hepatic perfusion or from recurrent bleeding, and to cause no deterioration in the quality of life from liver failure and encephalopathy.

The once popular total, or nonselective Portosystemic Shunt has failed to meet these

objectives in view of the high incidence of encephalopathy and its failure to prolong patient survival compared with medical therapy.

The patients with medical therapy tend to bleed to death, whereas those patients with portosystemic shunts tend to die of liver failure.

In our study we used variable shunting procedures, and we exclude portocaval shunt because of its high incidence of encephalopathy.

Our results, in terms of incidences of mortality, recurrent bleeding, encephalopathy, and long-term survival are comparable with those reported by others.

The works of Cleveland clinic,⁽⁴⁾ has shown that, in their hands, shunting procedures results in an operative mortality rate of 5 %- 25 %, rebleeding of 5%-25%, encephalopathy of 10 % - 25 % and 5 year survival of 50% - 60 %. In our series of 10 patients (group 1) we are able to reproduce these results in terms of hospital mortality rate, rebleeding, and 1-3 year survival, but our encephalopathy rate was higher (table 7).

So we believe that shunting procedures does not meet all the criteria for the "ideal" treatment for variceal hemorrhage.

Disappointment with shunt procedures has given rise in recent years to an active search for non-shunting procedures in the hope of approaching the "ideal" therapy. Of those, the reintroduction of endoscopic sclerotherapy is undoubtedly an important therapeutic advances. However, although this technique is effective in controlling acute variceal bleeding, recurrence of bleeding occurs in

20 % to 50 % of patients, ⁽¹⁾ and does not prolong patient survival.

Indeed, several patients in our series had had unsuccessful sclerotherapy before referral.

Other nonshunting procedures, such as limited gastroesophageal devascularization alone or oesophageal transection alone, have also proved ineffective in preventing recurrent hemorrhage and improving patient survival. ⁽²¹⁾

Sugiura, in 1977 realized that such limited local procedures are unlikely to succeed and he showed that only by interrupting all venous communications between oesophagogastric area of the varices and the high-pressure portal system is the surgeon likely to eliminate the varices. To achieve this, Sugiura devised his operation, which is based on separation of the venous circulation of the gastroesophageal area from the paraesophageal portal collateral vessels by devascularization; interruption of the intraesophageal collateral vessels to the region of the lower oesophagus by oesophageal transection; and splenectomy to reduce the portal inflow and thus lower the portal pressure. The long term result of this operation are impressive and are the best obtained so far by any one group concerned with the difficult problem of variceal bleeding. ⁽³⁾

The modified Sugiura operation that we performed is in our opinion simpler and easier than the two-stage procedures of Sugiura. Although the extent of the devascularization of the thoracic oesophagus in this modification is less than that achieved by a formal thoracotomy, the essential concepts of the Sugiura operation are maintained and the results are comparable.

Our modification includes, continues through and through suturing of the anterior and posterior gastric wall to interrupt the intramural gastroesophageal venous connection, we performed this suturing at the junction of the middle and upper third of the stomach, so as to interrupt gastric varices also. By this modification we overcame the disadvantages of oesophageal transection.

We maintain the right gastric vessels as the only blood supply to the stomach to overcome gastric congestion which leads to erosions and bleeding.

Although it might be possible to preserve the vagal trunks, we have not chosen to do so. Patients with portal hypertension have a high frequency of bleeding in the upper gastrointestinal tract from nonvariceal sources, ulcer or erosive gastritis. Subsequent development of such lesions may be prevented by vagotomy.

To overcome the complications of pyloroplasty, we performed pyloromyotomy as a drainage procedure.

Ligation of the splenic artery which was performed in combination with other procedures, is

not a new innovation, it was employed by Everson and Cole since 1948. ^(2,22)

The results obtained with the modified Sugiura operation in our series of 10 patients (group 2) are comparable to those of Sugiura operation, ^{3,23} in term of operative mortality rate, recurrent bleeding, survival, and the absence of encephalopathy. These superior results were obtained despite the fact that three patients were of child's class C, one had alcoholic cirrhosis, and two had the operation as an emergency procedure.

The early disappearance of varices in most of the surviving patients in this series is another important advantage of this operation. Sugiura and Futagawa reported disappearance of varices in 97% of the patients. ⁽²³⁾

Another gratifying result of the modified Sugiura operation in our series was the correction of secondary hypersplensim.

The operative time required to perform the procedure is of paramount significance in these seriously ill patients. The adverse effect of length of the operative time on survival is significant. ⁽¹⁴⁾ With practice the entire operation can be carried out within 1 hour, and it is possible to carry out the procedure without intraoperative blood transfusions.

It is theoretically possible that the oesophageal varices may reform after the new collateral pathways develop. However, Sugiura and Futagawa reported that this is not the case ⁽²³⁾, providing that the devascularization procedure has been meticulously carried out.

In our present knowledge we are inclined to believe that the modified Sugiura operation we performed provide a rational bases for the treatment of oesophageal varices because the real danger in portal hypertension is variceal bleeding and not portal hypertension perse. Therefore, what is required is the ablation of the dangerous oesophageal varices. Also it maintains hepatic function because it preserves the portal perfusion.




Figure1. Barium swallow-multiple esophageal varices

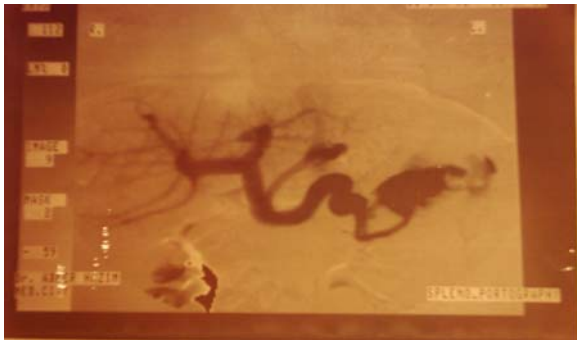

Figure2. Splenoportography- multiple esophageal and gastric varices

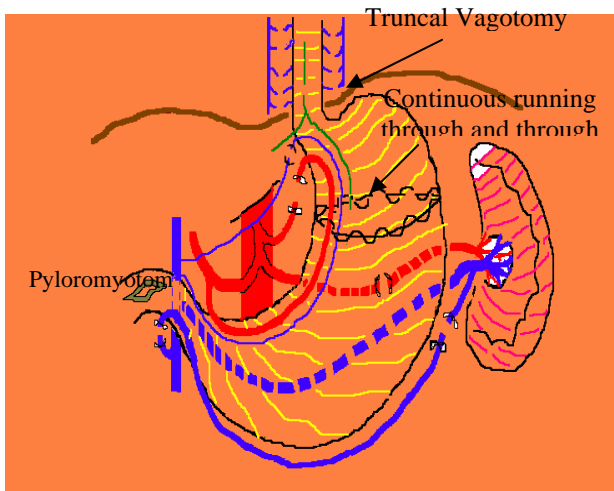


Figure3. Illustration of the modified Sugiura operation used in this study

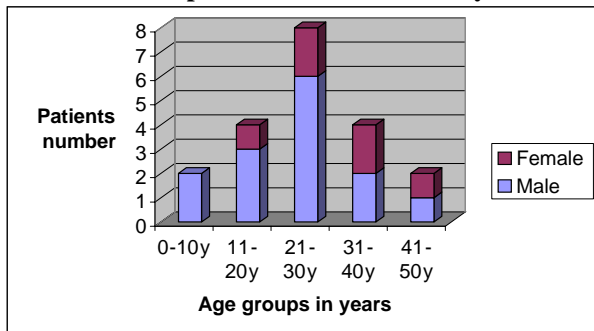


Figure4. Age and sex distribution

Conclusion:

Our technique of modified sugiura operation is probably a reasonable procedure available that meets most of the criteria of the “ideal” operation for variceal hemorrhage.

The operation can be effectively carried out in both adults and children, it is equally applicable in the elective as well as in the emergency situation and for the good – risk as well as the poor – risk patients.

In contrast to the shunting operations, recurrent variceal bleeding is uncommon, encephalopathy is not increased postoperatively, hepatopetal portal flow is not decreased and the liver function is well preserved with our technique.

References:

- Henderson J. M., Portal Hypertension; Zinner M. J., Schwartz S. I.; Ellis H.; Maingots abdominal operations, 10th ed. USA, Prentice Hall International; Vol. 2; 1997; 1649-1662.
- Donovan A. J., Surgical Treatment of Portal Hypertension: A Historical Perspective. World J. Surg. 1984; 8, 5, 626-645.
- Donovan A. J., Portal Hypertension: Background and general evaluation; Mcdermott W. V.: Surgery of the Liver. USA, Blackwell Scientific Publications. 1989; 283-291.
- Hermann R. E. Shunt Operations for Portal Hypertension. Surgical Clinics of North America. 1975; 55, 1073-1087.
- Drapanas T.: Interposition mesocaval shunt for treatment of portal hypertension. Ann. Surg. 1972; 176, 435.
- Warren WD, Millikan WJ, Henderson JM, et al. Ten years of portal hypertension at Emory: results and new perspectives. Ann Surg. 1982; 195, 530-542.
- Warren WD, Millikan WJ, Henderson JM, et al: Splenopancreatic disconnection: Improved selectivity of distal splenorenal shunt. Ann Surg. 1986; 204, 346.
- Conn H. O. Ideal Treatment of Portal Hypertension in 1985. Clinics in Gastroenterology. 1985; 14, 1, 259-288.
- Kobayashi M.; Inokuchi K.; Nagasue N., et al. Successful treatment of early cancer of the liver and portal hypertension in patients presenting with bleeding esophageal varices. Br. J. Surg. 1977; 64, 8, 542-544.
- Inokuchi k., Kobayashi M., Ogawa Y. et al. Results of left gastric vena caval shunt for esophageal varices : analysis of one hundred clinical cases. Surgery 1975; 78, 628-636.
- Sahi R.P. Modification of Tanners operation for bleeding esophageal varices. Journal of the Royal College of Surgeons of Edinburgh. 1975; 20, 6, 404-405.
- Hassab M.A. Gastroesophageal decongestion and splenectomy in the treatment of esophageal varices in bilharzial cirrhosis: Further studies with a report on 355 operations. Surgery 1967; 61, 2, 169-176.
- Karara K.; El-Gendi M.A.; Gertsch Ph. Portal pressure measurements before and after Hassab's decongestions operation. A preliminary report. Int. Surg. 1987; 72, 141-143.
- Al-Kraida A.; Qazi S.A.; Shaikh M.U.; et al. Transabdominal gastroesophageal devascularization and esophageal transection for bleeding esophageal varices. Br. J. Surg. 1989; 76, 9, 943-945.
- Sugiura M. ; Futagawa S. : A new technique for treating esophageal varices. J. Thorac. Cardiovas. Surg. 1973; 66, 677.
- Futagawa S.; Sugiura M.; Hidai K. ; Emergency esophageal transection with paraesophagogastric devascularization for variceal bleeding. World J. Surg. 1979; 3, 299.
- Idezuki Y; Kokudo N; Sanjo K, et al. Sugiura procedure for management of variceal bleeding in Japan. World J. Surg. 1994; 18, 2, 216-21 (abstract from the medline).
- Saeed Z. A.; Michaletz P. A., et al: Endoscopic variceal ligation in patients who have failed endoscopic sclerotherapy. Gastrointestinal Endoscopy. 1990; 36, 6, 572-574.
- Al-Fallouji M.A.R.; Mcbrien M.P.: Postgraduate Surgery. London, William Heinemann Medical books. 1986; 59-62.
- Mann Ch. V.; Russell R.C.G. and Williams N.S.: Bailey and Love's Short practice of surgery, 22nd ed. London, Chapman and Hall Medical. 1995; 712-718.
- Matory W.E.; Sedgwick C.E., et al. Non shunting procedures in management of bleeding esophageal varices. The surgical clinics of north America. 1980; 60, 2, 281-295.

22. *Samie B.S.: Surgical treatment of portal hypertension in children. Iraqi Medical Journal 1987; 35, 1, 12-18.*

23. *Abouna G.M.; Baissony H. and Menkarios A.T., The place of Sugiura operation for portal hypertension and bleeding esophageal varices. Surgery 1987; 101, 1, 9*