

The Value of Stroboscopic Examination in the Diagnosis of Hoarseness

Ahmed M. Rasheed FIBMS

Summary:

Background:

In modern laryngological practice laryngovideostroboscopic examination is an important step for correct diagnosis of vocal cord lesions.

Aims:

To assess the role of laryngovideostroboscopy as a clinical tool in evaluation of hoarse patients.

Patients and Methods:

Stroboscopic examinations were carried out on 43 patients presented with hoarseness at the ENT department at Al- Kadhimya Teaching Hospital during the period from "January 2006 to October 2006".

Results:

Stroboscopic examination contributed significant diagnostic information, it changed the diagnosis made by nonstroboscopic means in 8 cases (19%), this resulted in avoidance of surgery in 4 cases and 4 cases referred to surgery instead of medical therapy.

Conclusion:

Laryngovideostroboscopy is a useful clinical tool in modern laryngological practice so as to alter the diagnosis and management plan which may result in avoidance of unnecessary surgical and/or medical-therapies.

Keywords: Larynx, Stroboscopy.

*Fac Med Baghdad
2008; Vol.50, No.1
Received April 2007
Accepted Oct.2007*

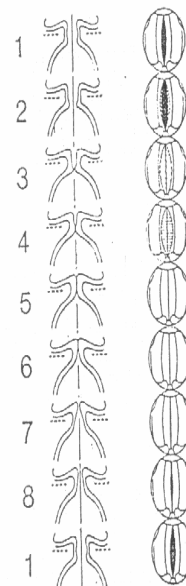
Introduction:

The larynx (voice box) is a passageway that connects the hypopharynx with the trachea. (1) The vocal folds are two fold-like structures, which extend from the middle of the angle of the thyroid cartilage to vocal processes of the arytenoid cartilages, the vocal fold consists of mucosa and muscle, the mucosa is subdivided into epithelium and lamina propria which consists of superficial, intermediate and deep layers, (2) it is this superficial layer which vibrates most significantly during phonation, if it becomes stiff due to some pathology such as inflammation, its vibration is disturbed. (2)

Laryngeal functions include protection of lower airways, phonation, respiration, chest fixation and laryngeal sphincters. (3)

Laryngovideostroboscopy is direct examination of the vocal cords under intermittent light to observe the vibratory movements of the vocal cords during phonation at slow motion, permitting detailed observations of the structure in the opened or closed positions. (5,6) The modern

videostroboscopic unit now is capable of producing a brightly illuminated and magnified image. (7)



Fig(1-1): Schematic presentation of the vocal fold vibratory pattern during phonation in normal chest register.
Left column: frontal section.
Right column: view from above as perceived in the laryngeal mirror.

Laryngovideostroboscopy in the modern laryngological practice is an essential diagnostic procedure for detection of vocal cord pathology. (8) Stroboscopy significantly

*Lecturer, Dep. Of Surgery (Otolaryngology),
College of Medicine, Baghdad University.*

improves the sensitivity of subtle laryngeal diagnosis with continuous light source. (9)

The operative principle of stroboscopy is that the image persists on the retina for 0.2 second after exposure, therefore, images presented at intervals less than 0.2 second are fused together, producing a montage of apparent motion. (10) The frequency of the examinees sustained voice is picked up by a microphone and triggers the stroboscopic light source. (11) The strobe light is produced at frequency several hertz slower than the vocal frequency to produce illusion of a slow motion (12).

Stroboscopic examination can be performed using either rigid or flexible endoscopes. (13)

The most useful clinical uses of stroboscopy include phonatory function assessment, differentiation between benign and malignant vocal cord tumors and evaluation of patients with vocal cord paralysis. (14)

Patients and Methods:

This is a prospective study which was carried on 43 patients presented with hoarseness at the ENT department at AL-Kadhimya Teaching Hospital during the period from January 2006 to October 2006.

Stroboscopic examination was carried out after history, routine otolaryngological

examination and fiberoptic examination of the larynx. Because of better visualization, a rigid stroboscopic examination was conducted with the 90° laryngoscope. After initial examination without stroboscopy, a tentative diagnosis and treatment recommendation was made. A second evaluation of each patient was completed after stroboscopic examination.

Evaluation criteria in stroboscopic examination include fundamental frequency, symmetry, amplitude, periodicity, vocal cords closure and mucosal wave propagation. Lastly grading was done. Grade "0" was made if the stroboscopic examination did not add new information to the diagnosis or to the subsequent management; grade "1" was made if stroboscopic examination provided significant information that altered the diagnosis made by nonstroboscopic means.

Results

In the present study the age ranged from 14-60 years, the most common age group seen was the third decade, there was 23 male (53.5%) and 20 females (46.5%) with male to female ratio 1.12:1.

Table 1 Shows the number and percentage of pathologic categories, and the usefulness of stroboscopy for each.

Table 1: The number and percentage of pathologic categories and the usefulness of stroboscopy

Pathology	Total number	Percentage	Usefulness rating	
			Useless (grade=0)	Useful (grade=1)
Nodule	17	39.53	14	3
Polyp	12	27.91	9	3
Laryngitis	7	16.25	5	2
Cancer	4	9.3	4	0
Paralysis	2	4.65	2	0
Trauma	1	2.33	1	0
Total	43	100%	35	8

In the 43 recordings done, stroboscopic examination provided critical information in 8 patients (19%) who had their management decisions changed due to added information from stroboscopic examination (Grade 1),

however, stroboscopic grading was "0" in 35 patients (81%) which means that stroboscopy did not add new information change the diagnosis and management plan.

Table 2: The eight cases with major management decisions changed by stroboscopic examination

Case	Sex	Initial Diagnosis	Initial Management	Final Diagnosis	Final Management
1,2&3	Female	Vocal nodule	Medical	Intracordal cyst	Surgical
4,5&6	Female	Unilateral polyp	Surgical	Vocal nodule	Medical
7&8	Male	Chronic laryngitis	Medical	Laryngeal carcinoma	Surgical

In the first 6 patients, the main stroboscopic findings which differentiate intracordal cyst from vocal cord nodule, and

vocal cord polyp from vocal cord nodule are tabulated in Table 3.

Table 3: The stroboscopic findings in vocal cord nodule, polyp and intracordal cyst

Stroboscopic findings	Pathology		
	Nodule	Intracordal cyst	Polyp
Symmetry	Normal	Asymmetrical	Asymmetrical
Periodicity	Normal	Aperiodic	Aperiodic
Glottic closure	Reduced (hourglass)	Reduced	Irregular
Amplitude	Reduced	Reduced	Reduced
Mucosal wave	At nodule site 1-reudced (edematous), 2-absent (firm)	Reduced (throughout the affected side) & absent (over the cyst).	Little or no wave

In the last 2 patients in which the initial diagnosis by mirror and fiberoptic examination was chronic laryngitis, stroboscopy shows absence of vibration of the affected vocal cord which indicates infiltration.

Discussion:

With the recent development of low-cost chip cameras and video equipment, stroboscopic examination can be easily documented and its findings can be shared between professionals and patients, as patients request more participation in decision process, stroboscopy will have a valuable role in patient education. (15)

In our study, the major pathologic conditions where that of vocal cord nodules (39. 53%), vocal polyps (27.91%), laryngitis (16. 28%), laryngeal carcinoma (9.3%). Woo, et al., (1991), in 195 stroboscopic examinations reported that the major pathologic conditions were that of laryngitis (23 %), laryngeal trauma (10.3%) and laryngeal paralysis (8.2%). (16)

In the 43 recordings done, stroboscopic examinations provided critical information that were instrumental in establishing the diagnosis in 8 cases (19%). These 8 patients had their management decisions changed due to added information from videolaryngostroboscopy; in

the remaining (81%)'stroboscopy resulted in no change in diagnosis.

Sataloff, et al., (1987), estimated in a series of 486 examinations that stroboscopy was valuable in the diagnosis of one third of the professional voice users. (17).

Casiano, et al., (1992), reported that videolaryngostroboscopy was found to alter the diagnosis and treatment outcome in 14% of patients. (18)

Sataloff, et al, (1991), reported that additional experience had altered the clinical usefulness of the procedure.(19)

Conclusions:

1- The technique of stroboscopy and video documentation is practical and easy to use.

2- In a small but significant percentage of patients (19%), the use of stroboscopy resulted in changes of diagnosis so as to alter the management plan, thereby avoiding unnecessary surgical and or medical therapies.

Acknowledgement:

I wish to express my thanks to Dr. Yusra Hayder for her great help and Substantive contributions to this study.

References:

1- Tortora, G.J. *The respiratory system. Principles of anatomy and physiology. 2000; 9th edition, pp. 780-83.*

2- Wier, N. (1997). *Anatomy of the larynx and tracheobronchial tree*. Scott- Browns Otolaryngology 6th edition, Basic sciences. pp. 1127-8.

3- Groves, J.; Gray, R.F. and Downton, D.(). *A synopsis of Otolaryngology*. 1985; 4 thedition, pp. 190,352-369.

4- Kitzing, p. *Stroboscopy: a pertinent laryngeal examination*. *Journal of Otolaryngology* . 1985; Vol.14,pp. 151-157.

5- Remade, M. *The contribution of videostroboscopy in daily ENT, practice*. *Acta Otorhinolaryngology*, 1996; Vol.50 (4), pp. 265-281.

6- Bless, D.M. ; Hirano, M. and Feder, R.J. *Videostroboscopic evaluation of the larynx*. *Ear, Nose and Throat Journal*, 1987; Vol.66,pp.289.

7- Buckmire, R.A.(2001). *Stroboscopy*. (Internet, Web: [http: \www. Emedicine.com\ent\ top ic606. htm](http://www.Emedicine.com/ent/top ic606. htm)).

8- Case, J.L. *Technology in the assessment of voice disorder*. *Seminars in Speech and language*, 1999; VoL20(2), pp. 169-84.

9- Dejonckere, P.H. *Perceptual and laboratory assessment of dysphonia*. *Otolaryngologic Clinics of North America*, 2000; Vol.33(4), p.731-750.

10-Cummings, C.W. ; Fredrickson, J.M, and Harker, L.A., et al. *The professional Voice Otolaryngology Head and Neck surgery*, 3rd edition, 1998; Vol. III, pp. 2057- 2059.

11- Metson, R.; Rauch, S.D. *Videolaryngoscopy m the office-acritical evaluation*. *Otolaryngology Head and Neck surgery*, 1992; Vol. 106(1), pp.56-9.

12-Rosen, C.A. And Murry, T. *Diagnostic laryngeal endoscopy*. *Otolaryngology Clinics of North America*, 2000; Vol.33(44), pp.753-758.

13- Hirano, M. and Bless, D.M. *Videostroboscopic examination of the larynx*. San Diego: Singular Publishing Group; 1993.

14-Colden, D.; Zeitels, S.M. and Hillman, R.E., et al. *Stroboscopic assessment of vocal fold keratosis and glottic cancer*. *Annals of Otolaryngology, Rhinology and Laryngology*, 2001; Vol. 110(4), pp.293-8.

15-Foure, M.A. and Muller, A. *Stroboscopy*. *Journal of voice*, (1992); Vol.6(2), pp.139-148.

16- Woo, p.; Cotton, R.; Casper, J. and Brewer, D. *Clinical applications of videostroboscopy in voice disorders*. *Journal of voice*, 1991; vol.5, pp.231-238.

17- Sataloff, R.T.; Spiegl, J.P. and Carroll, L.M., et al. *Stroboscopic examination in professional voice users: Results and clinical value*. *Journal of Voice*, 1987; Vol.1(4), pp.359-364.

18-Casiano, R.R.; Zaveri, V. And Lundy, D.S. *Efficacy of videostroboscopy in the diagnosis of*

voice disorders. *Otolaryngology Head and Neck Surgery*, 1992; vol.107, pp.95-100.

19-Sataloff, R.T., Siegel, J.R. and Hawkshaw, M.J. *Stroboscopic examination; Results and clinical value*. *Annals of otology, rhinology and laryngology*, (1991); Vol. 107, pp. 725-727.