

The role of IL-6 in the etiology of tinea versicolor in group of Iraqi patients.

Wifaq M. AL-Wattar*

Khalida M. AL-Mussawy*

Mukarum AL-Waiz**

FICMS

MCHB, PhD

MCHB, PhD

Summary:

Background Tinea versicolor is a common dermatological problem worldwide in distribution, caused by dimorphic fungus called *Malassezia furfur*, they exist at the very interface between commensal and pathogen and, as such, their interaction with the human immune system is of great interest. Immuno-inflammatory activity mediated by different cytokines could have a role in the etiology of tinea versicolor.

Patients and Method: The study covered 46 subjects .It comprised 26 patients with TV compared with 20 healthy normal controls. Serum IL-6 analysis was done by ELISA.

Results: The level of IL-6 was elevated in patients with tinea versicolor, when compared with healthy control

Conclusion: IL-6 increases during the infection and could be part of a complex immune response leading to fungal elimination from human body.

Keywords: interleukin-6, immunocompromized , tinea versicolor

Fac Med Baghdad
2010; Vol. 52, No. 2
Received Dec., 2009
Accepted Jan. 2010

Introduction:

Tinea versicolor is a common superficial skin infection , characterized by lesions varying in color from red, white (Hypo pigmented) to brown (Hyper pigmented) , usually affecting the upper trunk ,neck ,arms and may be found elsewhere on the skin except the soles and the palms . The lesions are scaling, macular, with mild to moderate itching, and cosmetic disfigurement which is the main complaint for most of the patients. The causative organism is a lipophilic yeast known as *Malassezia furfur*(1-4).

The genus *Malassezia* was first described in 1846 by Eichstedt. *Malassezia* species are, existing in both yeast and mycelial phases, the classical microscopical appearance composed of clusters of yeasts with hyphae that may be branched “spaghetti and meatballs”.

Malassezia species can cause several cutaneous and systemic disease in suitably predisposed human, they exist at the very interface between commensal and pathogen and, as such, their interaction with the human immune system is of great interest (5) .An increased incidence of this disease was more noticed in patients undergoing immunosuppressive therapy for organ transplant or various autoimmune diseases, systemic corticosteroid and cytotoxic drugs ; as an increased plasma cortisol level shown in Cushing syndrome whether spontaneous or iatrogenic was commonly associated with TV (6,7,8) and some suggests that diminished rate of physiologic desquamation of the infected stratum corneum may predispose to colonization of *Malassezia furfur* on

skin surface.(9) The chronic relapsing course of the disease and increased incidence of TV in steroid treated and immunosuppressed patients are suggestive of failure on the patients' part to mount a protective cell mediated immunity(CMI)response against the fungus.

A recent study found that patients with TV may not actually have a deficient CMI to the mycelial antigen of *Malassezia*. However, during active disease, they fail to generate a CMI response that would provide protection (10),but recently the defect seems to be in one of the mechanisms at three levels: 1) barrier functions of the uppermost layer of the skin, the stratum corneum,2) cytokine production by epidermal keratinocytes, and 3) immune and inflammatory responses by infiltrating neutrophils and T cell(11).

Material and Method and Patients:

The study was done in period between November, 2004 and middle of March, 2005.

Patients study group: The study was conducted on forty six blood samples of twenty apparently healthy persons as a control sample to be compared with twenty six tinea versicolor patients , who were examined and diagnosed for the classical skin rash , by the dermatologist at the Department of Dermatology at Baghdad teaching hospital, and the immunocompromized patients with TV were chosen from the Department of Blood Diseases . Five mls of venous blood were taken from each individual, 2mls were put in tubes with anticoagulant to be sent for complete blood picture ,and the rest 3 cc of blood were left to clot at room temperature ,then centrifuged and serum was collected in aliquots to stored in(-18°C) until needed for IL-6 investigation .

*Dept. of Microbiology/ college of Medicine/ Baghdad University.

** Dept. of Dermatology/ college of Medicine/ Baghdad University.

Drug, Kits and reagents: Human Interleukin -6 (IL6) ELISA kit (BioSource .KAC1261:96 determinations.

Interpretation of the results: The results were calculated by Interpretation from a standard curve that is performed in the same way as that of the sample .The average absorbance for each sample on the vertical axis was located and the corresponding IL-6 concentration on the horizontal axis was read.

Statistical analysis was done using SPSS version computer software (Statistical Package for Social Sciences). T-test was used to analyze the data, and the calculation of mean difference, p value <0.05 level of significance was considered statistically significant

Results:

According to the three study groups: there was statistically significant differences in the concentration of IL-6 level between TV patients and healthy control p<0.025, the difference was also significant between the healthy control and immunocompramized patients with TV,P<0.005 while. the difference between the two diseased groups was non significant(p< 0.3) As shown in

The detectable level of IL- 6in the three study groups	N	mean	Std. Error Mean	t- test P- value p<0.05
Tinea versicolor patients	13	312.9	74.65	0.025\S
Immunocompra mized patients	13	219.9	45.96	0.005\S
Normal controls	20	107.8	29.02	

table (1)

Table 1: The level of IL-6 in the three study groups

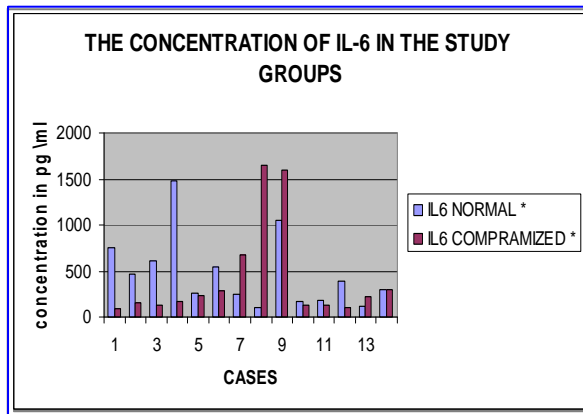


Figure 1: The concentration of IL-6 in tinea patients

Discussion:

Tinea versicolor is a common dermatological problem worldwide in distribution and more prevalent in tropical areas , with an incidence in certain places as high as to 30 to 50% where there are high temperatures and high humidity, the condition is more frequent in summer time ,and the lesions may be more extensive in tropical climates (12), This disease was noticed in apparently normal persons as well as in the immunocompramized patients ,as in leukemia, lymphomas and those taking cytotoxic and or systemic steroid therapy (13) . Tinea versicolor had the ability to persist in both commensal as skin flora and a pathogen by escaping the immune defenses with a complicated process called immunomodulation resulting in skin problems which is tinea versicolor. Although TV is generally associated with minimal inflammation, a cellular infiltrate was seen in such lesions. One of the studies had characterized the infiltrate by increased numbers of T lymphocytes, mainly consisting of THP (T-helper) cells with few Tc(cytotoxic)cells ,with increased number of Langerhans' cell in the dermis in some lesions(14) the skin, Langerhans' cells are able to take up antigen and then present it to T cells, providing a link between nonspecific immunity and the specific immune response. Monocytes numbers were also increased in the dermis in some lesions, and were present in the epidermis in other lesions. Recently, it has been reported that when a monocytic cell line, and THP1, were stimulated with either live or heat-killed *Malassezia*, the production of interleukin-6 (IL-6) was increased, with the activation of neutrophils and induction of inflammation (15). IL-6 also induces activation of T cells. In this study the level of serum IL-6 was detectable in 10patients with tinea versicolor, and undetectable in 3patients only, the statistical analysis showed significant difference of (0.025), when compared with healthy control. All the immunocompramized patients had a detectable IL-6, with a high significant difference when compared with the control group, p< (0.005). This is comparable to the findings of some researchers who suggested that the interaction of *Malassezia* with phagocytic cells may serve to amplify the inflammatory response and up regulate phagocytic cells and even provide enhanced protection against the bacterial and tumor cell challenge in some animals (16, 17). There was no similar studies in Iraq ,while there was a consistency of these results with some other studies abroad like Collins &Sohnle (18) , and Kroger et al who studied the effect of a sonicated preparation of *Malassezia* on the increase of IgE, IL-2, IL4-, IL-6, IL-10, and IFN-γ production by peripheral blood mononuclear cells (PBMC) test in vitro, who relate it to the unique ability of *malassezia* to up regulate the production of some cytokine like IL-6 , resulting from the lymphocytic sensitivity of the immune system toward *Malassezia* when the(formalized whole cells, culture supernatant, and a cellular fraction) of *Malassezia* were incubated with

keratinocytes or PBMC, the release of cytokines was determined at various time points. The levels were significantly higher than those of the negative control (19). Certain keratinocyte-derived cytokines, including IL-6 may play a role in tissue remodeling and wound healing (20). It has been demonstrated that IL-6 stimulates keratinocyte proliferation in diseases associated with epidermal hyperplasia and wound healing (21, 22, 23).

References:

- 1- Rook, A. & Champion, R. H. (2004). *Mycology. In Rook's Textbook of Dermatology*, pp. 920–970. Edited by T. A. Burns, S. M. Breathnach, N. H. Cox & C. E. M. Griffiths. Oxford: Blackwell
- 2- Anaissie, E. J. 2002. *Dermatophytes. In Clinical Mycology*, pp. 370–372. Edited by E. J. Anaissie, M. R. McGinnis & M. A. Pfaller. Philadelphia: Churchill Livingstone.
- 3-Wifaq,AL-wattar&Khalida AL-Mussawy.(2007).The role of IL-4 and IL-8 in the etiology of Tinea versicolor in group of Iraqi patients. *JFac Med Baghdad*, Vol .49,No.1 ,p111-113.
- 4- Ford G. *Pityrosporum folliculitis* 1884.*Int J Dermato*;23:320-3215- Eichstedt, E. 1846. *Pilzbildung in der Pityriasis versicolor. Frorip Neue Notizen aus dem Gebeite der Naturkunde Heilkinde* 39:270.
- 6- Makimura, K. (2001). *Species identification system for dermatophytes based on the DNA sequences of nuclear ribosomal internal transcribed spacer I. Jpn J Med Mycol* 42, 61–67.
- 7- Dahl, M. V. & Grando, S. A. (1994). *Chronic dermatophytosis: what is special about Trichophyton rubrum. Adv Dermatol* 9, 97–109
- 8- Grone, A. (2002). *Keratinocytes and cytokines. Vet Immunol Immunopathol* 88, 1–12.
- 9- Hay RJ, Moore MIn: Champion RH, Burton JL, Burns DA, Breathnach SM, editors.(1998). *Textbook of dermatology. 6th ed. Oxford: Blackwell Science;*. p. 1277-376.
- 10-Saadatzadeh MR, Ashbee HR, Cunliffe WJ, Ingham E. (2001)*Cell mediated immunity to mycelial phase of Malassezia spp in patients with pityriasis versicolor and controls. Br J Dermatol*;144:77-84.
- 11- Wurtz RM.(1988). *Malassezia furfur* in a patient without the usual risk factors. *Ann. Intern. Med.* 109-432.
- 12- Midgley, G. 1989. *The diversity of Pityrosporum (Malassezia) yeasts in vivo and in vitro. Mycopathologia* 106:143–155.14- Midgley, G. *The diversity of Pityrosporum (Malassezia) yeasts in vivo and in vitro. Mycopathologia* 106:14G
- 13-Scheynius, A., J. Faergemann, and U. Forsum. 1984. *Phenotypic characterisation in situ of inflammatory cells in pityriasis (tinea) versicolor. Acta Dermato-Venereol.* 64:473–479.
- 14-Taha O.D,Gad-Elrab MO.1990.*Immunological status of Tinea versicolor patients.Pan-Arab League of Dermatologists ;1:21-26.*
- 15-Guillot, J., and E. Gueho. 1995. *The diversity of Malassezia yeasts confirmed by rRNA sequence and nuclear DNA comparisons. Antonie Leeuwenhoek* 67:297–314.
- 16- Ruth H. Ashbee* and E. Glyn V. 2002 January. *Immunology of Diseases Associated with Malassezia Species Evans.Clin Microbiol Rev.*; 15(1): 21–57.
- 17-Takahashi, M., T. Ushijima, and Y. Ozaki. 1986. *Biological activity of Pityrosporum. II. Antitumour and immune stimulating effect of Pityrosporum in mice. JNCI* 77:1093–1097.
- 18-Sohnle PG,Collins –Lech C.1980 . *Analysis of the lymphocyte transformation response to Pityrosporum orbiculare in patients with tinea versicolor.:J Invest Dermatol ;75 (3):279-283.*
- 19- Kroger, S., K. Neuber, E. Gruseck, J. Ring, and D. Abeck. 1995. *Pityrosporum ovale extracts increase interleukin-4, interleukin-10 and IgE synthesis in patients with atopic eczema. Acta Dermato-Venereol.* 75:357–360
- 20- Yumi Shiraki¹, Yoshio Ishibashi², Masataro Hiruma³, Akemi Nishikawa² and Shigaku Ikeda.2006.¹ *Cytokine secretion profiles of human keratinocytes during infections .J Med Microbiol* 55, 1175-1185.
- 21- Krueger, J., Ray, A., Tamm, I. & Sehgal, P. B. 1991. *Expression and function of interleukin-6 in epithelial cells. J Cell Biochem* 45, 327–334
- 22- Chinen, J. & Shearer, W. T. 2005. *Basic and clinical immunology. J AllergClinImmunol*116,411–418.
- 23-Gu, L., Tseng, S., Horner, R. M., Tam, C., Loda, M. & Rollins, B. J. 2000. *Control of TH2 polarization by the chemokine monocyte chemoattractant protein-1. Nature* 404, 407–411