

Soft tissue Sarcomas: Immunohistochemistry evaluation by Desmin, Myosin, Smooth muscle Actin and Vimentin

DOI: [doi.org/ 10.32007/jfacmedbagdad.621,21704](https://doi.org/10.32007/jfacmedbagdad.621,21704)

Ibtisam H.Azeez Al Obaid* MD



This work is licensed under a [Creative Commons Attribution-NonCommercial 4.0 International License](https://creativecommons.org/licenses/by-nc/4.0/).

Abstract:

Background: Soft tissue sarcomas (STS) are relatively rare tumors, representing less than 1% of adult malignancies based on report from American Cancer Society. The crude incidence rate in Iraq for soft tissue sarcomas was 219/ 100,000 populations during 2014 with a male: female ratio of 1.2:1, and the highest age peak falling between 30-34 years. The histological subtype and microscopic criteria are two parameters that influence the tumor grade which is the best predictor for aggressiveness.

Objectives: A retrospective evaluation of soft tissue sarcomas, using immunohistochemical (IHC) study of Myosin, Desmin, Smooth muscle Actin (SMA) and Vimentin, aiming to review the primary diagnosis and whether IHC assessment in soft tissue sarcoma is mandatory to reach a final interpretation.

Patients and methods: A total of 50 cases of soft tissue sarcomas were reviewed retrospectively from case archives of histopathology department/ Central Public Health Laboratory and Ghazi Al Hariri Hospital for Specialized Surgeries for the period (2011-2018). Hematoxylin and Eosin (H&E) stain and IHC staining of unstained sections from formalin-fixed, paraffin-embedded tissue were performed using SMA, Vimentin, Desmin and Myosin. The staining intensity was assessed based on the percentage of positive cell expression of the four IHC monoclonal antibodies.

Results: The staining interpretation of the four monoclonal antibodies were confirmatory for the original diagnosis in 40% of cases, while 60% of the final diagnoses were re-evaluated and a different interpretation was given supported by the IHC findings for Desmin, Myosin, SMA and vimentin, under the clinical and radiological context.

Conclusions: The co-expression of SMA and Desmin helped in the diagnosis of leiomyosarcoma (LMS). Myosin expression was helpful in the diagnosis of rhabdomyosarcoma (RMS) and alveolar soft part sarcoma (ASPS). SMA and Vimentin were not specific for the diagnosis of malignant fibrous histiocytoma (MFH). By applying IHC markers, 60% of soft tissue sarcomas were found to be different from the preliminary diagnosis while 40% of cases were supportive of the original H&E diagnosis.

Keywords: soft tissue sarcomas, immunohistochemistry, pathological types of soft tissue sarcomas.

JFac Med Baghdad
2020; Vol.62, No .1,2
Received: Oct., 2020
Accepted June 2020
Published: June , 2020

Introduction:

Soft tissue sarcomas are relatively rare tumors, the crude incidence rate in Iraq for soft tissue sarcoma was 219/100,000 population during 2000 with male: female ratio of 1.2:1 and age range (1 - 70 years) (1). The pathogenesis of soft tissue sarcomas reveals that it occurs de novo rather than from malignant transformation of preexisting benign tumors, as in neurofibromas (2, 3). Two parameters can influence the tumor grade including (a) histological subtype and (b) microscopic criteria: including cellularity, mitotic count/ 10 HPF, necrosis, hemorrhage, degree of differentiation, vascularity and vascular invasion (4). The diagnosis of soft tissue sarcoma is a challenge even for expert pathologists and the use of IHC as one of the necessary diagnostic procedures beside the

radiology, special stains as PAS for intracytoplasmic glycogen in extraskeletal Ewing's sarcoma, reticulin stain in vascular tumors, PTAH and Masson's trichrome stain for striated muscles, and mucin stain for myxoid tumors (5).

Patients and Methods:

A total of 50 cases soft tissue sarcomas were reviewed retrospectively from the histopathology department in Central Public Health Laboratories and Ghazi Al Hariri Hospital for Specialized Surgeries for the periods (2011-2018). Both diagnostic biopsies and excisional biopsies were included in this study. Age at diagnosis, gender and tumor sizes and location were collected from the relevant pathology reports. Sixty eight (68%) of patients were males versus (32%) females, with the highest peak of age between (51-60) years. Extremities were the most common site of involvement. The primary diagnosis was made based on H&E staining

* National center for teaching laboratories, Medical city.
bhazeez@gmail.com.

only, under the context of the clinical data and radiological findings. No IHC was done initially. All paraffin blocks from these cases were collected, stained with H&E stain, then an IHC staining of unstained 5 microns thickness sections was done using SMA, desmin, myosin and vimentin monoclonal antibodies. Applying PAP (peroxidase antiperoxidase) method, the monoclonal mouse and rabbit antibodies (SMA clone 1A4, Desmin clone D33, myosin clone 2F12.A9 and vimentin clone V9) were used. Control slide sections of appropriate tissues were included as a positive control for each antibody. Negative control slides were run for each antibody. Pathologist's visual interpretation of stained slides compared to positive control slides by assessing the intensity of the staining was scored semiquantitatively from 0 to (+++). Negative staining was reported when no stain was seen. Positive (+) means that up to 30% of tumor cells were with antigen expression. Positive (++) interpretation was given when 31-60% of tumor cells showed staining reaction, while

Positive (+++) interpretation was reported when over 60% of tumor cells showed staining reaction. (6)

Statistical Analysis using Spearman's correlation coefficients and P-value between the immunohistochemical staining scores for Myosin, Desmin, SMA and vimentin expressions reveal a significant P-value (<0.05) and a positive correlation between the positive expression and staining intensity scores.

Results:

The 50 cases studied revealed various IHC staining patterns for the four monoclonal antibodies used. **1-Myosin:** Striated muscle fibers were used as a positive control for myosin. Out of 50 cases, 30 (60 %) showed positive staining including 10 cases (20%) with intense (+++) staining pattern, 16 cases (32%) with moderate (++) staining, 4 cases (8%) with low (+) staining, and 20 cases (40%) showed negative staining (Table-1).

Table -1: Myosin Immunohistochemistry staining interpretation

Type of sarcoma	No. of cases	Score				% of positive cases
		0	+	++	+++	
Fibrosarcoma	6	4	0	2	0	33.0
MFH	22	12	2	4	4	83.3
RMS	12	2	2	8	0	83.3
STS	4	0	0	2	2	100.0
LMS	2	2	0	0	0	100.0
SS*	2	0	0	0	2	100.0
ASPS	2	0	0	0	2	100.0
Total (%)	50	20 (40)	4 (8)	16 (32)	10 (20)	
P-Value	0.0369					

*Synovial Sarcoma

Smooth muscle actin (SMA): Smooth muscle fibers in (uterine leiomyoma) stained as positive and were used as a positive control for SMA. Out of 50 cases, 38 cases (76%) showed positivity including 12 cases (24%) with

intense (+++) staining, 10 cases (20%) with moderate (++) staining, and 16 cases (32 %) showing low staining (+) intensity, while 12 cases (24 %) were negative for SMA (Table-2).

Table-2 Smooth muscle actin (SMA) immunohistochemistry staining interpretation

Type of Sarcoma	No. of cases	Score				% of positive cases
		0	+	++	+++	
Fibrosarcoma	6	0	2	0	4	100.0
MFH	22	4	10	6	2	81.8
RMS	12	2	4	2	4	83.3
STS	4	4	0	0	0	-
LMS	2	0	0	0	2	100.0
SS	2	0	0	2	0	100.0
ASPS	2	2	0	0	0	-
Total (%)	50	12 (24)	16 (32)	10 (20)	12 (24)	
P- Value	0.0118					

Desmin: Monoclonal antibodies were used on sections from uterine leiomyoma and used as a positive control for desmin. Out of 50 cases, 8 cases (20%) showed positivity for desmin, including 3 cases (6%) with

intense (+++) staining, 2 cases (4%) with moderate (++) staining and 3 cases (6%) with low (+) staining intensity (Table-3).

Table-3: Desmin Immunohistochemistry staining interpretation

Type of Sarcoma	No. of cases	Score				Score
		0	+	++	+++	
Fibrosarcoma	6	2	2	0	2	66.6
MFH	22	22	0	0	0	0
RMS	12	8	2	1	1	33.3
STS	4	4	0	0	0	0
LMS	2	0	0	1	1	100
SS	2	2	0	0	0	0
ASPS	2	2	0	0	0	0
Total (%)	50	40 (80)	4 (8)	2 (4)	4 (8)	0
P-Value	0.0463					

Vimentin: The endothelial – lined blood vessels were used as a positive control for Vimentin internal positive control. Positive staining was identified in 42 cases (84%) of cases including 12 cases (24%) with intense

(+++ staining, 17 cases (34%) with moderate staining and 13 cases (26%) with weak (+) staining, while 8 cases (16%) were negatively stained as in (Table-4).

Table-4: Vimentin Immunohistochemistry staining interpretation

Type of Sarcoma	No. of cases	Score				% of positive cases
		0	+	++	+++	
Fibrosarcoma	6	0	1	2	3	100.0
MFH	22	3	4	10	5	86.3
RMS	12	2	4	3	3	83.3
STS	4	1	2	1	0	75.0
LMS	2	0	0	1	0	50.0
SS	2	0	1	0	1	100.0
ASPS	2	3	0	0	0	0
Total (%)	50	8 (16)	13 (26)	17 (34)	12 (24)	
P-Value	0.0423					

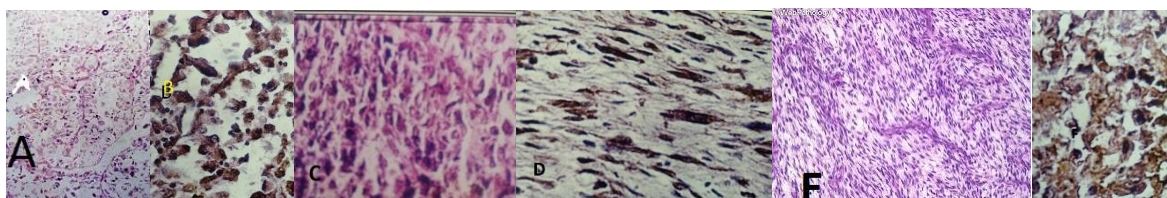


Figure-1: Alveolar soft part sarcoma with organoid arrangement of the tumor cells (A), positive myosin IHC showing diffuse cytoplasmic staining(B). A case of MFH H&E stain showing atypical fibrohistiocytic lesion (C) , positive for Myosin IHC with cytoplasmic expression(D). A case of Synovial sarcoma, H&E stain showing vague storiform spindle cell neoplasm(E) with positive Myosin expression(F).Original magnificationX200 H&E slides [A,C,E] and X400 IHC slides[B,D,F]

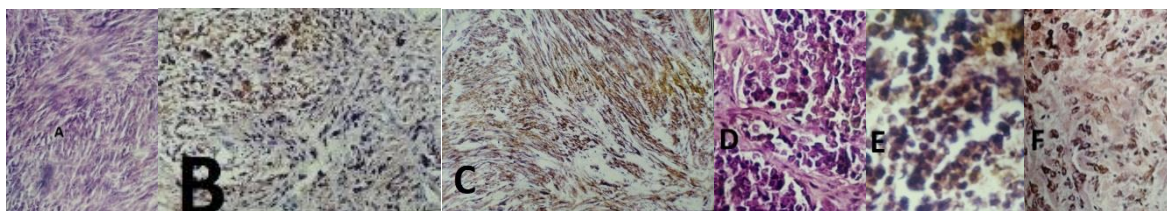


Figure-2: Leiomyosarcoma (H&E)stain showing spindle cell lesion with storiform pattern (A), desmin (B) and vimentin (C) positive IHC favored the diagnosis of LMS, Alveolar Rhabdomyosarcoma (H&E) stain showing non-cohesive pleomorphic malignant cell in alveolar pattern (D), the initial interpretation was Peripheral neuroectodermal tumor (PNET) , but reveal positivity for myosin IHC (E) and desmin (F), favored the diagnosis of Alveolar RMS .Original magnification X200, H&E slides[A&D] and X400 IHC sllides [B, C, E,F].

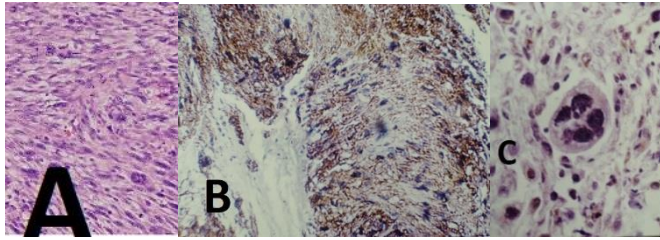


Figure-3: Malignant fibrous histiocytoma(MFH), H&E stain showing atypical fibrohistiocytic lesion, inflammatory cells and tumor giant cell (A) with positive smooth muscle actin (SMA)IHC (B) and negative myosin IHC(C). Original magnification X200 , H&E slide [A] and X400 IHC slides [B, C].

Discussion:

The value of using IHC markers in the diagnosis and sub-classification of soft tissue neoplasms in general is a very wellknown fact in histopathology. There are more than 100 distinct types of soft tissue neoplasms, including more than 80 benign and intermediate mesenchymal tumors and around 40 soft tissue sarcomas. Accurate diagnosis relies first upon recognition of characteristic histologic and cytologic features, and once a differential diagnosis is established, application of IHC, cytogenetic and molecular diagnostic assays is used in attempt to reach specific diagnosis.

Fibrosarcoma: Six cases originally diagnosed as fibrosarcoma by H&E stain, were tumors that at least focally showed the presence of eosinophilic spindle cells with vesicular blunt ended nuclei arranged in a fascicular pattern. Two cases were diffusely reactive for SMA and Desmin, while negative for Myosin (Fig-3, Table-2 & 3). These cases were re-evaluated as LMS based on this findings, this concurred with the results of Schaefer & Hornick (2018), Markku et al (1988) and Christopher et al (2001), who found that both SMA and Desmin together are good markers for smooth muscle differentiation and serve to identify LMS(7,8,9). One case originally diagnosed as fibrosarcoma, showed a positive myosin with focal SMA positivity and Desmin negativity, was re-evaluated as RMS, under the clinical context and site of the tumor in the lower extremity. This also was consistent with the findings of Christopher et al (2001) (9) and Koh et al (1980) (10). These two studies found that RMS exhibit positive staining with antimyosin antibodies and may show focal positive stain for SMA, which is an excellent marker for smooth muscle differentiation but can be expressed in up to 13% of RMS as reported by Wei (2017) (11).

Malignant fibrous histiocytoma (MFH): Twenty two cases were originally diagnosed as MFH by ordinary H&E stain, included eight cases of high grade pleomorphic spindle cell sarcoma, often containing large polygonal cells with copious eosinophilic cytoplasm that is myosin positive, Desmin negative with or without SMA positivity (Fig-3). These cases were re-evaluated as pleomorphic RMS. In Montiel et al study (2006), Nascimento (2008) and Koh et al study (1980) who emphasized the diagnostic value of Myosin

in RMS, beside the role in solving the differential diagnosis of RMS with other Myosin –negative tumors like lymphoma, neuroblastoma, Ewing’s sarcoma and MFH.(12,13) Two cases were diagnosed as MFH versus LMS on H&E stain, was myosin positive (Fig-2), and negative for SMA and Desmin, this excluded the diagnosis of LMS as both SMA and Desmin are negative and cases were re-evaluated as RMS with myosin positivity .This also correlated with the findings of Meittinen (2014) (13).

Six cases were originally diagnosed as high grade MFH, they expressed SMA and vimentin positivity, while negative for myosin and Desmin. SMA can be focally expressed in MFH according to Christopher et al (2001) (9) and Marco et al (1999) (14). Vimentin is a good marker for mesenchymal differentiation, it is a very sensitive but non-specific marker for certain types of sarcomas. Marco et al study (1999) and Saeed et al study (2011) give 100% vimentin positivity in MFH cases which supports the original H&E diagnosis in our study of these six cases.(14, 15).Two cases in this study diagnosed as MFH versus RMS, revealed SMA, vimentin positivity and myosin, Desmin negativity (excluding muscle differentiation); then excluding the possibility of RMS, based on Christopher et al. study(2001) Meittinen (2014) and Marco et al study(1999)(9,13,14)

Rhabdomyosarcoma (RMS): Out of the twelve cases originally diagnosed as RMS by H&E stain: six cases were Myosin positive, Desmin negative, SMA positive; confirming the original diagnosis of RMS. Two cases were positive for myosin, SMA and vimentin, confirming the original diagnosis of RMS. Desmin was positive (++) score in one case with morphology of embryonal RMS (Fig-2, Table-3).Vimentin is expressed in all our RMS cases, matching the findings of Wieslawa (2002) and Cacho (2005) but more prominent in undifferentiated than well-differentiated tumors (5, 16). It was of limited use due to its presence in a variety of sarcomas (17). Two cases were positive SMA while negative for Desmin and myosin, which is against the diagnosis of RMS. The cases were reclassified as pleomorphic myogenic sarcoma. Two cases were positive for myosin, with alveolar RMS morphology by H&E stained section (Fig-2); while

negative for both SMA and Desmin, supporting the original diagnosis of RMS (18).

Soft Tissue Sarcoma (STS): Four cases were diagnosed as STS by H&E stain; they were found to be Myosin positive and SMA, Desmin negative, therefore reclassified as RMS (1, 16). STS is not accepted as a final diagnosis. Usually the pathologist states this diagnosis when the picture is not specific for subtyping and IHC is mandatory but not available. So this diagnosis was reported as “STS, not specified by histopathological findings” (19).

Leiomyosarcoma (LMS): Two cases in our study were diagnosed as LMS by H&E stain, revealed positive SMA and Desmin (Fig-2) which confirmed the original diagnosis and concurred with the conclusions of Markku (8) and Christopher et al (14) who found that both SMA and Desmin serve together as a good marker for smooth muscle differentiation. Diffuse Desmin positivity throughout a tumor is indicative of myoid differentiation, and the presence of either SMA or Desmin focally, should not be necessarily equated with myoid lineage but rather with myofibroblastic lineage as proved by Hirofumi et al (1998)(4), Meittinen (2014)(13) and Parham (2015)(17).

Synovial Sarcoma (SS): Two cases were diagnosed as SS, revealed positive staining for myosin (Fig-1) and SMA, while negative for Desmin. Correlation of the IHC pattern with the histomorphology of these tumors which exhibits a high grade spindle cell proliferation with high grade nuclear features and high mitotic rate put the diagnosis under controversy and raised the need for extra monoclonal antibodies to be studied. A study done by Marco et al (1999) on 34 cases of poorly differentiated sarcoma, concluded that SS is immunoreactive for (S100 protein, collagen IV, fibronectin, cytokeratins and epithelial membrane antigen), and negative staining with SMA, Desmin and myosin (14). Another study by Parham (2015), highlight the use of TLE1 immunostaining as a standard marker in SS evaluation; however, it was non-specific because other sarcomas may show a weak reaction that is overlapping with SS (17, 20). Based on these findings, these cases in our study were re-diagnosed as high grade RMS.

Alveolar soft part sarcoma (ASPS): Two cases in our study with the original H&E diagnosis of ASPS, show a diffuse positive staining for Myosin (Fig-1) and support the original diagnosis. This interpretation is also supported by the studies of Parham (2015)(17), Foschini et al (1994)(21) and Jo Vy (2013, WHO)(22); who concluded that ASPS is of myogenous derivation and that it represents a distinct variant of RMS; with the inconsistent IHC demonstration of smooth muscle and sarcomeric Actins, Desmin, vimentin and myosin. The vital role of IHC in the distinction of ASPS from the other differential diagnoses as Renal cell carcinoma (EMA positive), Paraganlioma showing

neuroendocrine markers as Synaptophysin, Chromogranin A, and S100 protein in sustentacular cells, while granular cell tumor show S100 protein positivity(23,24,25). It was evident that Desmin diffuse positive staining in four cases (8%) that could be due to the fact that Desmin is more specific for myogenic differentiation but it is less specific than Actin. Several studies regarded Desmin as a non-specific marker in RMS, and gives positivity in (85-100%) of cases (23, 24). Marco et al study (1999) (14), reported 34% Desmin positivity for three cases of poorly differentiated sarcoma. A similar conclusions was made about Desmin by Fisher (2009) (26), Pardal (2017) (27), and Shankar (2019). (28) The result of Vimentin in our study were 100 % positive staining (six cases fibrosarcoma, Fig-2, Table-4), regarded as a sensitive marker for mesenchymal tissue, but it is not a specific marker and this is consistent with other studies such as Al-Jebori (2018) and Fletcher (2013)(29, 30) who found 100% positivity. Al Daraji study (2009) reported 100% positivity(18), Hasan study (2008) reported 89.5% positivity (25), and Strauss et al (2010)(31). Reporting 100% positivity for six cases of fibrosarcoma, however; it is a non-specific marker for RMS as in Schaefer Study (2018) (32), Jha study (2010) (33) Singh study (2017) (34) and Al-Agha (2008) (35) who made a conclusion of the likelihood to get a negative vimentin in RMS. A positive nuclear staining for TFE3 is diagnostic of ASPS in 100% of cases, together with positive (cytoplasmic only) MyoD1 and Vimentin, beside a positive PAS stain, diastase resistant needle-like structures.(36, 37, 38)

Conclusions:

Co-expression of SMA and Desmin helped in the diagnosis of LMS. Myosin expression was helpful in the diagnosis of RMS and ASPS. SMA and vimentin are not specific for the diagnosis of MFH. High grade spindle cell sarcoma expressed SMA only without Myosin or Desmin; can be categorized as pleomorphic myogenic sarcoma. The original diagnosis by H&E staining have been changed after IHC staining in 32/50 cases (60%) while it was confirmatory for the original diagnosis in 18/50 cases (40%).

In summary, further to this work, we recommend in practice; to consider using a new continuously updated panel of monoclonal antibodies to establish the subtype of STS as an important ancillary testing before issuing a pathology report. Myosin, SMA, Desmin and vimentin IHC study can be considered a basic initial panel for any STS under the clinical context of the age, gender and site of the tumor; however, it is not sufficient in a variety of STS and additional markers can be added after the initial assessment like Alpha-1-Antitrypsin, MyoD1, Myogenin, S100 protein, h-Caldesmon, CD34, Sox10, HHV8, CD31 and CD68. A panel of IHC markers is required for accurate diagnosis,

based on varying sensitivity, specificity and different staining intensity scoring for the positively stained monoclonal antibody markers.

References:

1. Iraqi Cancer Registry Center, Ministry of Health, Baghdad-Iraq, 2014.
2. Goldblum J, Weiss Sh, Folpe AL, 2013. *Immunohistochemistry for analysis of soft tissue tumors, chapter 7, Enzinger and Weiss's Soft tissue Tumors, 6th edition. St Louis:P: (1, 3,5,6, 7, 8 ,9, 1511, 1518), Elsevier Expert consult: online and print.*
3. Rosai JM, 2011. *Soft tissues, Chapter 25, Rosai and Ackerman's Surgical pathology, 10th edition, Vol.1 and 2, P: 48, 51, 58, 2258, Elsevier Expert consult: online and print.*
4. Hirofumi N, Ipeei K, Keishi N. 1998. Well – differentiated adult type fibrosarcoma arising from occipital subcutaneous tissue in a 17 years old man case report with immunohistochemistry study. *Jap J Clin. Oncol; 12: (511-516).*
5. Wieslawa S, Aldona W, Malgorcata JJ, 2002. *Usefulness of immunohistochemical testing and electron microscopy in diagnosis of embryonal rhabdomyosarcoma, Medical Science Monitoring; 8(1):39-46.*
6. Longway SR, Lind HM, Haghighi P, 1986. *Extrasketal Ewing's sarcoma arising in the broad ligament; Arch Pathol Med; 110 (1058-1061).*
7. Schaefer IM, Hornick JL, 2018. *Diagnostic Immunohistochemistry for soft tissue and bone tumors: An update, Adv. Anat. Pathol; 25(6):400-412.*
8. Markku M, 1988. *Antibody specific to muscle actin in the diagnosis and classification of soft tissue tumors, Am J Pathol; 130(1).*
9. Christopher DM, Fletcher CD, Pelle G et al, 2001. *Clinicopathological re-evaluation of 100 malignant fibrous histiocytomas: Prognostic relevance of subclassification, J Clin Oncol; 19(12):3045-3050.*
10. Koh Sk, Johnson W, 1980. *Antimyosin and antirhabdomyoblastic sera: Their use for the diagnosis of childhood rhabdomyosarcoma, Arch. Pathol. Lab. Med; 104: (118-120).*
11. Wei S, Henderson, Jackson E, Qian X, Bui MM, 2017. *Soft tissue tumors Immunohistochemistry update: Illustrative examples of diagnostic pearls to avoid pitfalls. Archive of Pathol .Lab. Med; 141(8)1072-1091.*
12. Montiel P, Plaza JA, Malagon DH et al, 2006. *Differential expression of smooth muscle myosin, smooth muscle actin, h-Caldesmon and Calponin in the diagnosis of myofibroblastic and smooth muscle lesions of skin and soft tissue, Am J Dermatopathol; 23(5): 12-23.*
13. Meittinen M, 2014. *Immunohistochemistry of soft tissue tumors- Review with emphasis on 10 markers. Histopathology; 64(1):101-118.*
14. Marco S, Alessandro F, Camilla E, 1999. *The comparative roles of electron microscopy and immunohistochemistry in diagnosis of poorly differentiated sarcomas, Appl. Pathol.:1-5.*
15. Saeed MS, Yahya Th T, Hudder OE, Hussein IA, 2011. *Undifferentiated (Embryonal) sarcoma of the liver: Case report and review of literatures, Iraqi Academic Scientific J, Vol 10(4); 576-582.*
16. Cacho CM, 2005. *The role of immunohistochemistry in the differential diagnosis of soft tissue tumors, Pathology update: 28-36.*
17. Parham DM, 2015. *Immunohistochemical markers of soft tissue tumors: Pathologic diagnosis, genetic contributions and therapeutic opinions, Analytic Chemistry Insite; Libertas Academica. 10(Suppl): 1-10. Online.*
18. Al Daraji W, Husain E, Zelger BG, 2009. *A practical and comprehensive immunohistochemical Approach to the diagnosis of superficial soft tissue tumors, Int. J Clin. Exp. Pathol; 2(2):119-131.*
19. Nascimento AF, Raut CP, 2008. *Diagnosis and management of pleomorphic sarcomas (so – called "MFH") in adults, Surg Oncol.; 97:330-339.*
20. Mathew S. Turner, and Jeffrey D. Goldsmith, 2009. *Best practices in Diagnostic immunohistochemistry, Arch. Pathol. Lab. Med; 133: (1370-1374).*
21. Foschini MP, Eusebi V, 1994. *Alveolar soft part sarcoma: A new type of rhabdomyosarcoma, Semi. Diag.Pathol; 11: (58-68).*
22. Jo Vy, Fletcher CD. 2013. *WHO classification of soft tissue tumors: an update based on the pathology, 4th edition; 46:95-104.*
23. Demicco EG, Boland GM, Brewler KJ et al, 2016. *Progressive loss of myogenic differentiation in leiomyosarcoma has prognostic value, Histopathology; 66(5):627-638.*
24. Abdelateef Sh M, 2013. *Immunohistochemical analysis of CD34 to evaluate angiogenesis in chronic lymphocytic leukemia, J of Faculty of Medicine, Vol. 55(2); 131-134.*
25. Hasan FF, Mohammed HL, 2008. *Comparison between Benign and Malignant primary bone tumors: A histopathological study of 119 cases. Al-Mustansiriyah J of Science, Volume 2(1); 141-146.*
26. Fisher C, 2009. *Low grade sarcomas with CD34-positive fibroblast and low grade myofibroblastic sarcoma, J Ultrastruc pathol; 28(5):291-305. <https://www.tandfonline.com/10i/iusp20>*
27. Parda J, Hoang MP, 2017. *Soft tissue neoplasms, Chapter 7, Immunohistochemistry in Diagnostic dermatopathology, p: 138-185, Cambridge.org university press. <http://doi.org/10.1017/9781316576816008>*
28. Shankar V, 2019. *Undifferentiated/ unclassified sarcoma, Pathologyoutlines.com website <http://www.pathologyoutlines.com/topic/softtissuemfhpleo.html>*

29. Al-Jebori HA, 2018. Immunohistochemistry on cell blocks: A method for pre-operative diagnosis of papillary thyroid carcinoma by FNAC, J of Faculty of Medicine Baghdad, Vol.60 (2); 102-104.
30. Fletcher C, Bridge JA, Hogendoorn PCW, Mortens F, 2013. WHO Classification of tumors of soft tissue and bone, P: 5, 12, 33, 42, IARC Press Lyon, World Health Organization, France.
31. Strauss DC, Qureshi YA, Hayes AJ et al, 2010. The role of core needle biopsy in the diagnosis of soft tissue tumors, J Surg Oncol; 102: 523-529.
32. Schaefer IM, Cote GM, Hornick JL, 2018. Contemporary sarcoma diagnosis, genetics and genomics, J Clin. Oncol; 36: 101-110.
33. Jha R, 2010. Difficulties in the diagnosis of soft tissue sarcomas, J Instit. Med.; 32: 226-229.
34. Singh HP, Grover S, Garg B et al, 2017. Histopathological spectrum of soft tissue tumors with immunohistochemical correlation and FNCLCC grading: A North Indian experience, NMJ; 58(5):149-155.
35. Al-Agha O, Igbokwe AA, 2008. Malignant fibrous histiocytoma: Between the past and the present, Archiv Pathol. Lab. Med; 132(6):1030-1035.
36. Hornick JL, 2010. The prognostic role of immunohistochemistry in sarcomas. uscap.org/Knowledge-hub, <https://elearning.uscap.org>.
37. Fos B, Navrro S, Liombart A, 2008. Immunohistochemistry of soft tissue sarcomas, AJSP: Reviews and reports; 13(2): 45-50.
38. Argani P, Antonesco CR, Llei PB, Lui MY, Timmons CF, Newbury R. et al, 2007. Primary renal neoplasm with ASPL-TFE3 gene fusion of alveolar soft part sarcoma: A distinctive tumor previously included among renal cell carcinoma of children and adolescents, Am J Pathol; 159(1):179-192.

غرن الانسجة الرخوة الخبيث: تقييم بالصبغات النسيجية المناعية الكيميائية

د. ابتسام حسين عزيز العبيدي

خلفية البحث: يعتبر غرن الانسجة الرخوة من الاورام النادرة الحدوث نسبيا حيث تشكل اقل من 1% من نسبة جميع السرطانات، مع تنوع وتداخل كبيرين في الصفات النسيجية المرضية. كانت نسبة وقوع الورم في العراق حوالي 219/100,000 شخص للعام 2014 وبنسبة ذكور لإناث تساوي 1.2: 1. ان الصبغات المناعية النسيجية الكيميائية تساعد بشكل كبير في التصنيف الدقيق لاورام الانسجة الرخوة. لقد اجريت هذه الدراسة لغرض تحديد اهمية وقيمة هذه التقنية في التوصل الى تشخيص دقيق لانواع مختلفة من غرن الانسجة الرخوة.

الاهداف: اعادة تقييم التشخيص الاولي في 50 حالة من غرن الانسجة الرخوة متضمنة نماذج الخزعات التشخيصية ونماذج استئصال الورم. تهدف الدراسة لتحديد اهمية اجراء الصبغات النسيجية المناعية الكيميائية باستخدام الطرائق القياسية للحصول على افضل النتائج ودورها في التوصل الى تشخيص اكثر دقة.

مادة الدراسة وطرق البحث: تم دراسة 50 حالة مختارة لغرن الانسجة الرخوة استنادا والتي تم الحصول عليها من مختبرات النسيج المرضي في مختبر الصحة العامة المركزي ومختبر مستشفى الجراحات التخصصية في بغداد للفترة الزمنية (2011-2018). تم استخراج قوالب البارافين الشمعية وصبغها بصبغات الهيماتوكسيلين والايوسين (H&E)، مايوسين للعضلات المخططة (Myosin)، ديسمين (Desmin)، أكتين العضلات الملساء (SMA) وفايمنتين (Vimentin).

النتائج: اظهرت دراسة 50 حالة من هذه الاورام باستخدام الصبغات المناعية الكيميائية تفاعلا ايجابيا اما موقعا او منتشرا وبنسبة 71.4% للمايوسين، 76% لأكتين العضلات الملساء، 16% لديسمين و 84% للفايمنتين.

مناقشة النتائج: ان التشخيص النهائي بعد اجراء فحوص الصبغات المناعية النسيجية الكيميائية قد تغير حيث كانت النتائج توكيدية للتشخيص الاولي في 40% من الحالات بينما 60% من الحالات اظهرت نتائج مساعدة في التوصل الى التشخيص بالتفريق عن حالات اخرى مشابهة شكليا او اعطت تشخيصا نهائيا محدد وواضحا ومختلفا عن التشخيص الاولي مع الاخذ بنظر الاعتبار نتائج الفحوص الشعاعية وموقع الورم للوصول للتشخيص النهائي.

الاستنتاج والتوصيات: التعبير المتصاحب لأكتين العضلات الملساء (SMA) وديسمين (Desmin) في ساعد على تمييز غرن العضلات الملساء بينما تعبير مايوسين العضلات المخططة ساعد على تشخيص غرن العضلات المخططة (RMS) وغرن الاجزاء الرخوة السنخية (ASPS). استخدام أكتين العضلات الملساء وفايمنتين في تشخيص اورام الخلايا الليفية المنسجة الخبيثة (MFH) ولكن لايمكن الاعتماد عليها بصورة كاملة في تشخيص هذه الاورام لكونها حساسة ولكنها غير متخصصة لنوع معين من الاورام. من الممكن استخدام مجموعة اولية من معلمات الاورام النسيجية الكيميائية المناعية (مايوسين ديسمين، أكتين العضلات الملساء وفايمنتين) كخطوة اساسية اولية في تشخيص غرن الانسجة الرخوة بدقة وبالامكان الذهاب لاجراء صبغات نسيجية مناعية اخرى مثل (S100 بروتين، مايوجينين، سوكنس 10، سي دي 34، سي دي 68 و HHV8)

مفتاح كلمات البحث: غرن الانسجة الرخوة الخبيث، الصبغات المناعية النسيجية الكيميائية، تشخيص اورام الانسجة الرخوة